



# Surgical Treatment of Spinal Nerve Sheath Tumors of the Cervical Spine with Paravertebral Growth

Slynko Ievgenii\*; Derkach Urii; Alao Oluwateniola

Department of Spinal Cord and Spine Pathology, Romodanov's Institute of Neurosurgery, Kyiv, Ukraine.

**\*Corresponding Author(s): Slynko Ievgenii**

Department of Spinal Cord and Spine Pathology,  
Romodanov's Institute of Neurosurgery, Kyiv, Platona  
Maiborody Street, 32, Kyiv, 04050, Ukraine.

Tel: +380505437680; Email: eu.slynko@gmail.com

**Abstract**

**Object:** Still, the question about the specific treatment of patients with SNTs of the cervical spine segment with paravertebral growth is insufficiently studied. This requires close attention and needs further improvement, which proves the relevance of the chosen topic and research area.

Solving the problem of improvement of treatment of SNSTs of cervical spine consists of evaluating the results of surgical treatment, and advanced surgical approaches used to remove these tumors.

**Methods:** The research is based on analysis of results from the diagnosis and surgical treatment of 65 patients who were Surgically Treated for (SNST) of the cervical segment with paravertebral growth. The research took place in the Department of Spine and Spinal Cord Pathology, Romodanov's Institute of Neurosurgery, from the year 1999 to 2019. We collect preoperative through 15-day postoperative data (medical charts, MRI, CT, vertebral and spinal angiography, Ro-graphs) on patients at our hospital.

**Results:** The choice of surgical approach was made based on data of instrumental research methods and topographic anatomical variants of tumors in detail substantiated in the developed classification. A variety of surgical approaches has been used to remove these tumors. Surgical approach used in excision of SNSTs of cervical segment with paravertebral growth are applied in the study: Posterior - 21(32.3%) observations; posterior-lateral - 25(38.5%); far lateral - 4(6.1%); extreme-lateral - 3(4.6%); anterior - 12(18.5%). The assessment of the quality of life outcomes was assessed according to the ECOG-WHO scale. We substantiated the criteria that allowed to choose surgical approaches that provided optimal visual control over the course of tumor removal and the condition of surrounding tissues, namely TMO's condition at different levels and the preservation of the conditional's physiological curvature plane of the intervertebral foramina.

Received: Feb 01, 2022

Accepted: Feb 25, 2022

Published Online: Feb 28, 2022

Journal: Neurology and Neurological Sciences: Open Access  
Publisher: MedDocs Publishers LLC

Online edition: <http://meddocsonline.org/>

Copyright: © Ievgenii S (2022). *This Article is distributed under the terms of Creative Commons Attribution 4.0 International License*

**Keywords:** Nerve sheath tumors; Cervical spine; Paravertebral growth.

**Abbreviations:** SNST: Spinal Nerve Sheath Tumor; PG: Paravertebral Growth; MPNST: Malignant Peripheral Nerve Sheath Tumors; AG: Angiography; PS: 5 - Point Scale of Pain Syndrome; MRI: Magnetic Resonance Imaging; MD: 5-Point Scale of Motor Segmental Disorders; CT: Computed Tomography; SD: 5 - Scale Of Sensory Segmental Disorders; MSCT: Multi-Spiral CT; VA: Vertebral Artery; BO: Before Operation; AO: After Operation; SNR: Spinal Nerve Root; LTG: Lateral Tumor Growth; VTG: Ventral Tumor Growth; DTG: Dorsal Tumor Growth.

**Cite this article:** Ievgenii S, Urii D, Oluwateniola A. Surgical Treatment of Spinal Nerve Sheath Tumors of the Cervical Spine with Paravertebral Growth. *Neurol Neuro Sci Open Access*. 2022; 5(1): 1026.



**Conclusions:** The study of the relationship between duration of history and probability of the McCormick scale of transition to another group (improvement and regression of neurological disorders) after surgery showed that the longer the history, the less likely it is to move to another group.

When analyzing the topographical and anatomical characteristics of the tumor of the spinal nerves of the cervical segment with paravertebral spread, the following distribution of location options were found: we detected 27.7% of tumor observations at the level of C1-C2 vertebrae, 41.5% - C2-C3 vertebrae, 7.7% - C3-C4 vertebrae, 4.6% - C4-C5 vertebrae, in 7.7% - C5-C6 vertebrae, 10.7% - C6-C7 vertebrae, 3% - C7-T1 vertebrae. Dislocation of the common carotid artery by the tumor was diagnosed in 12% and 24% of the vertebral artery.

## Introduction

Spinal Nerve Sheath Tumor (SNST) occurs quite often and makeup to 48% of the tumor of the spinal region. The biggest problem is the neurosurgical removal of tumors that spread paravertebral in the cervical spine. Among (SNST), there are various topographic-anatomical and histological types. The surgical tactics depend on the region and the predominant direction of the spread of the paravertebral tumor [1]. In the process of growing, neoplasms reach impressive dimensions and lead to profound neurological disorders due to compression of roots and spinal cord, dislocation and compressions of the vascular and nerve structures paravertebrally. This causes significant difficulties in removing tumors in this region, and therefore, due to the unsatisfactory results of neurosurgical treatment, relapses or extended tumor growth in a short time [2]. Thus, surgical treatment SNST of the cervical spine with paravertebral growth is an actual neurosurgical problem. This is in connection with the complexity of the stage of surgical treatment, taking into account their various paravertebral distribution, with the formation of a complex tumor neuro-vascular connection. The detailed information on the effectiveness of the lateral and anterior approaches in modern treatment is insufficient [3]. Also, the peculiarity is a need to provide decompression of the spinal cord, spinal nerve roots, and vertebral artery when the tumor is excised to achieve and ensure a robust spinal fixation with preservation of functionality [4]. At the time, a wide range of surgical approaches for the treatment of such kind tumors in the cervical spine is being implemented. Still, the question about the specific treatment of patients with SNTs of the cervical spine segment with paravertebral growth is insufficiently studied. This requires close attention and needs further improvement, proving the relevance of the chosen topic and area of research [5].

Solving the problem of improvement of treatment of SNSTs of the cervical spine consists of evaluating surgical treatment results and advanced surgical approaches used to remove these tumors.

## Methods

### Data source

The research is based on analysis of results from the diagnosis and surgical treatment of 65 patients who were surgically treated for (SNST) of the cervical segment with paravertebral growth. The research took place in the Department of Spine and Spinal Cord Pathology; Romodanov's Institute of Neurosurgery

during the year 1999 to 2019. We collect preoperative through 15-day postoperative data (medical chart, MRI, CT, vertebral and spinal angiography, Ro-graphs) on patients at our hospital. We used techniques for intraoperative monitoring during spinal surgery include Somatosensory Evoked Potentials (SSEPs), Motor Evoked Potentials (MEPs) and Electromyography, which can either, be Spontaneous Free-Running (sEMG) or Triggered (tEMG). To control the vertebral artery dopplerography was used intraoperative.

### Patient population

Observations are divided into two groups, with different possibilities of diagnostic tests and treatment technologies: first group - 1999-2009 and the second group - 2009 – 2019. Among patients involved in this study were 36 men (55.4%) and 29 women (44.6 %).

### Outcomes

Outcomes evaluated were 7-day mortality, major complication, operative duration (minutes), total hospital Length of Stay (LOS; days), and dynamics of neurological symptoms. The major complication was: During surgery-hemorrhage and need for blood transfusion, damage arteries or veins, damage nerves, spinal cord; postsurgical - pneumonia, Deep Vein Thrombosis (DVT), Pulmonary Embolism (PE), wound infection. The minimum follow-up in our postoperative follow-up was 2 weeks; the maximum was - 72 months. The average duration of remote observation was  $24.4 \pm 1.2$  months.

### Statistical analysis

Statistical processing of the material was done using the statistical software package STATISTICA 10.0 Stat Soft Inc. of USA. Descriptive statistics were used to describe the observation groups - the mean, the error of the mean and standard deviation were calculated. Cross-tabulation was used (in dividing the sample into groups according to the value of two or more variables): Conjugation tables were compiled to represent the joint distribution of variables and study the relationship between them. Correlation analysis was used to calculate the correlation between the variables' quantitative value - Pearson's pairwise linear correlation was calculated. A non-parametric Chi-square test for qualitative variables or parameter was used to determine the probability of error between the two samples. Differences between indicators were considered significant at  $P < 0.05$ .

## Results

### Patient cohort

Consequently, 40% of elderly patients and 55.4% of men are predominating.

The locations of SNSTs of the Cervical Segment with DG are distributed as follows: In 18 (27.7%) observations of the tumors were detected at the level of C1-2 vertebrae, 27 (41.5%) - C2-C3 vertebrae, 5 (7.7%) - C3-4 vertebrae, 3 (4.6%) - C4-5 vertebrae, 5 (7.7%) - C5-6 vertebrae, 7 (10.7%) - C6-7 vertebrae, 2 (3%) - C7-T1 vertebrae. Most often, tumors were located at the C2-C3 level, in the second most frequent place - at the C1-C2 level.

It is important to emphasize that in all cases, the tumor spread paravertebrally. In 18 (41.5%) cases, SNST compressed and displaced the vertebral artery; in 5 (8.3%) - displaced the common carotid artery; in 3 (5.4%) caused compression and dislocation of the esophagus.

In our observations, schwannomas were 42 cases (65.6%), neurofibromas - 16 (24.6%), perineuromas - 3 (4.6%), malignant peripheral nerve sheath tumor - 4 (6.1%).

A variety of surgical approaches has been used to remove these tumors. Surgical approach used in excision of SNSTs of cervical segment with paravertebral growth are applied in the study: Posterior - 21(32.3%) observations; posterior-lateral - 25(38.5%); far-lateral - 4(6.1%); extreme-lateral - 3(4.6%); anterior - 12(18.5%). The assessment of the quality of life outcomes was assessed according to the ECOG - WHO scale.

### Comparison of results in two study periods

Operations in both observation periods were performed by neurosurgeons with at least ten years of experience in self-surgery for spinal tumors.

The first period, 1999 - 2008 years.

In the first period of our study, we used only posterior approaches in all cases. Began to perform surgical interventions using microsurgical techniques, diagnostic capabilities used to diagnose SNST of the cervical spine became more accessible and began to be used in all cases of detection of such tumors. No, neurophysiological monitoring or intraoperative Doppler visualization used in this period.

The second period 2009 - 2019 years.

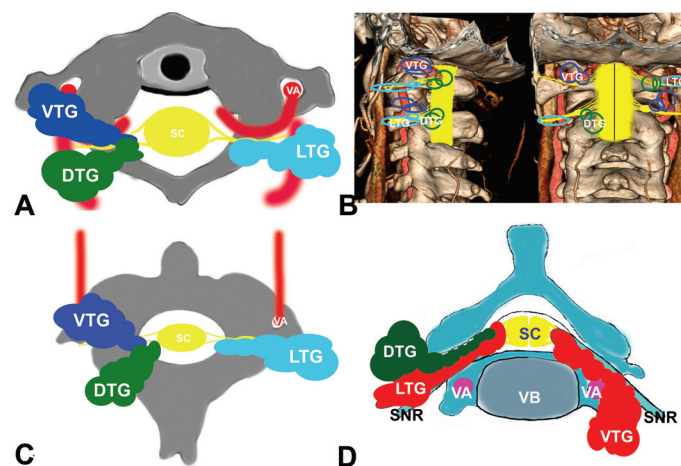
We fully used microsurgical techniques to remove these tumors; in the arsenal of neuroimaging, methods used modern devices that allow more accurate training of patients to remove SNST of the cervical spine. In the second period, using the anterior approach to remove SNSTs with VTG allows adequate visual inspection of the vertebral artery during the removal of such tumors, which prevents complications associated with VA artery damage. Likewise, anterior approach was used to remove SNSTs with LTG. Posterior and posterolateral approaches used to remove SNSTs with DTG.

In the second period we used techniques for intraoperative monitoring during spinal surgery include Somatosensory Evoked Potentials (SSEPs), Motor Evoked Potentials (MEPs) and electromyography, which can either be Spontaneous Free-Running (sEMG) or Triggered (tEMG). To control the vertebral artery dopplerography was used intraoperatively. The neurophysiological monitoring and intraoperative Doppler visualization used as a standard in all patients.

When comparing observations of II and I within the periods 1999-2008 and 2009 - 2019, we found out that the duration of hospitalization from the beginning of the development of neurological symptoms decreased (from  $38.7 \pm 2.1$  months in group I to  $15.2 \pm 1.5$  months in group II).

For us to remove the cervical SNTs from the DG, it is essential to clarify the neuroimaging characteristics regarding the direction of spread and the nature of tumor growth. In the second group of observations, and in addition to Standard Methods of Neuroimaging (MRI, MSCT) in the presence of spinal artery displacement or a need for more accurate imaging of the spinal artery, we used Multi-spiral CT angiography (16 observations), MR-angiography - 9, selective angiography (19 observations). After analyzing the data of instrumental research methods, the necessary approach was chosen to remove the tumor, which made it possible to avoid damage to the vertebral artery in all cases.

Our analysis of the existing topographic and anatomical classifications showed that they are based on the principle of estimating the tumor's location relative to the plane of the dura mater. It is well known that SNSTs with DG are marked by the possibility of spread, not only in the spinal canal to the dura mater (which manifests itself in the form of intra-extradural location) but also spread through the intervertebral foramina paravertebrally. These features allowed us to deviate from the established principles of classification and recognize the anatomical border not only the meninges but the complex "dura mater - the intervertebral foramen." This comprehensive approach to determining the conditional anatomical border of the tumor's root became the basis of the proposed topographic - anatomical classification (**Figure 1**).



**Figure 1:** Schematic representation of the types of tumor growth on which the choice of surgical approach depends. A - Level C1 vertebrae, B - Scheme based on standard CT angiography of tumor growth types, C - level C2 vertebrae, D - sub-axial level.

SC: Spinal Cord; VB: Vertebral Body; VA: Vertebral Artery; SNR: Spinal Nerve Root; LTG: Lateral Tumor Growth; VTG: Ventral Tumor Growth; DTG: Dorsal Tumor Growth.

The choice of surgical approach was made based on data from instrumental research methods and topographic - anatomical variants of tumors in detail substantiated in the developed classification.

Our position was the principle of choosing a one-stage surgical approach, which allows removing both the paravertebral part of the tumor, and the tumor in the canal of the spinal nerve and the tumor in the spinal canal. To do this, sometimes it was necessary to remove a part of the vertebral body or articular facet. Then, depending on the degree of resection, the necessary fixation was performed.

Analyzing the data as seen in the first group of observations, the same type of posterior approach was used (hemilaminotomy - 15, posterior - 17), despite the nature of the spread of SNSTs with para-vertebral growth, in contrast to the second period of observations due to differentiated approach and implementation latest technical capabilities: In the second group of observations, we used a different strategy to choose the surgical approach depending on the direction of growth, localization of the tumor and the size of the paravertebral component in addition to posterior approach groups (posterior - 4, posterolateral - 10), we used anterior approach (extreme lateral approach - 3, far-lateral - 4, Anterior - 12).

In our study, in I period were 10 cases LTG: In 8 cases was used posterior - lateral approach, in 2 cases - posterior ap-

proach. In the same period, there were 11 cases of DTG: In 3 cases, we used the posterior - lateral approach, in 8 cases -posterior approach. Also, in the first period, there were 11 cases of VTG: In 4 cases, we used the posterior - lateral approach, in 7 cases - posterior approach.

In our study, in II period were 10 cases of LTG: In 1 case, we used far - lateral approach, in 6 cases - anterior approach, in 3 cases, we used posterior - lateral approach. There were also 11 cases of DTG: In 7 cases, we used the posterior - lateral approach, in 4 cases -posterior approach. This period was characterized by 12 cases of VTG: In 3 cases we used far - lateral approach, in 6 cases -anterior approach, in 3 cases we used extreme - lateral approach.

In the first period of our study, in 8 cases, these tumors were not removed radically because we used only posterior approaches - posterior - 17, posterolateral - 15. In this period, there were 3 injuries of the vertebral artery, 2 - the spinal cord, 3 - segmental roots. The mortality rate was 2 patients.

In the second group, we used the posterior approach - 4, far lateral approach - 4, extreme lateral approach - 3, posterolateral approach - 10, anterior approach - 12. All tumors were removed radically. There was no damage to the vertebral artery, spinal cord, or segmental roots during this period. There was no mortality.

In the second group of observations, for ventral and lateral localization of the tumor, we used approaches that allowed us to reach "the tumor directly" visualize and control VA that significantly reduce the rate of complications and neurological deficit compared with the first observation period.

Tables 1, 2, 3 present the distribution of observations based on the severity of neurological deficits in observations II and I before and after surgery, depending on the direction of the tumor's growth and applied surgical approach.

The data in Tables 1-3 shows the regression of neurological deficits, which indicates the second group of observations. This is explained by a reasonable differentiated choice of surgical approach regarding the nature of the spread and direction of tumor growth, the use of microsurgical techniques with a microscope, and endoscopic assistance for visual control features in removing the tumors.

When comparing the conduction abnormalities on the McCormic scale in the first group of observations of the VG and LG tumors the average score was  $2.34 \pm 0.23$  in the preoperative period and  $1.67 \pm 0.19$  in the postoperative period. MS in the first group was  $3.23 \pm 0.32$  before surgery and  $2.45 \pm 0.26$  after surgery; SS was  $3.55 \pm 0.36$  before surgery and  $3.22 \pm 0.24$  in the postoperative period. PS was  $3.0 \pm 0.37$  in the preoperative period and  $2.3 \pm 0.22$  after surgery, respectively. In the second group of observations, similar indicators were on the McCormic scale  $2.12 \pm 0.21$  before surgery and  $1.13 \pm 0.14$  in the postoperative period. MS was  $3.13 \pm 0.31$  before surgery and  $1.9 \pm 0.23$  after surgery, SS was  $3.23 \pm 0.33$  before surgery and  $2.12 \pm 0.24$  in the postoperative period, PS was  $2.7 \pm 0.34$  in the preoperative period and  $1.8 \pm 0.21$  after surgery.

Comparing the I and II period, the choice of anterior, far or extreme lateral approaches in the cases of SNSTs with LTG or VTG showed a more significant regression of neurological deficit.

The dynamics of neurological deficiency with DTG of SNSTs did not differ between the two groups.

**Table 1:** The dynamics of neurological deficit based on surgical approach used in clinical groups with VTG.

Evaluation Criteria	I Period (1999 – 2008 pp.)				II Period (2009- 2019 pp. )					
	Approach									
	Posterior n = 7		Posterior-lateral n = 4		Anterior n = 6		Far-lateral n = 3		Extreme-lateral n = 3	
	Pre-operative	Post-operative	Pre-operative	Post-operative	Pre-operative	Post-operative	Pre-operative	Post-operative	Pre-operative	Post-operative
McCormic	2.5	2.3	2.7	2.4	2	0.3	1.6	0.6	2	0.5
PS	2.5	2.0	3	2.7	3	2.3	3.2	1.4	3.6	1.2
SS	4.5	3	3.2	2.7	3.6	2.5	2.8	0.8	3.6	1.6
MS	3	2.5	3.2	2.2	2	1.3	2.4	1.2	2.6	1

**Table 2:** The dynamics of neurological deficit based on surgical approach used in clinical groups with LTG.

Evaluation Criteria	I Period (1999 – 2008 pp.)				II Period (2009- 2019 pp. )					
	Approach									
	Posterior n = 8		Posterior-lateral n = 2		Anterior n = 6		Far-lateral n = 3		Posterior-lateral n = 1	
	Pre-operative	Post-operative	Pre-operative	Post-operative	Pre-operative	Post-operative	Pre-operative	Post-operative	Pre-operative	Post-operative
McCormic	2.5	2.3	2.6	2.3	2.4	1.5	2.8	1.3	3	1
PS	2.5	2	3	2.7	3.6	1.5	3.3	1.5	5	2
SS	4.5	3	3.1	2.6	3.3	1.7	3.6	1.7	4	1
MS	3.0	2.5	3.1	2.7	2.1	1.5	2	1.3	2	0

**Table 3:** The dynamics of neurological deficit based on surgical approach used in clinical groups with DTG.

Evaluation Criteria	I Period (1999 – 2008 pp.)				II Period (2009- 2019 pp. )			
	Approach							
	Posterior n = 8		Posterior-lateral n = 3		Posterior n = 4		Posterior-lateral n = 7	
	Pre-operative	Post-operative	Pre-operative	Post-operative	Pre-operative	Post-operative	Pre-operative	Post-operative
McCormic	2,6	1,6	2,8	1,6	2,8	1,4	2,4	1,1
PS	2,4	1,5	3,1	1,9	3	1,8	3,2	1,4
SS	3,5	1,9	3,3	1,7	3,2	1,5	2,8	1,1
MS	2,9	1,6	3,4	1,8	2	1,3	2,4	1,2

### Tumors of C1, C2, C3 Spinal Nerve (craniovertebral-C1-C2 level).

In the II period, far lateral approaches at Craniovertebral - C1-C2 levels we used for LTG and extreme lateral - for VTG of SNTs (**Figure 2**). Tumors with pure DTG were perfectly removed using posterior - lateral approach (**Figure 3**).

#### Subaxial levels

In the II period, using the anterior approach to remove SNSTs with VTG allows adequate visual inspection of the vertebral artery during the removal of such tumors, which prevents complications associated with VA artery damage (**Figure 4**). Likewise, anterior approach was used to remove SNSTs with LTG. Posterior and posterolateral approaches used to remove SNSTs with DTG.

In cases where the articular processes were removed during the removal of tumors from the posterior approach, posterior transpedicular fixation was used to ensure reliable stabilization of the spine; used in 19 cases from both groups (5 - first period, 14 - second period).

With anterior approaches, if it was possible to remove the tumor through the enlarged intervertebral foramen from the spinal nerve canal or the spinal canal, fixation was not used. If the vertebral body had to be resected to remove the tumor from the spinal nerve canal or the spinal canal, body cage and anterior plating were used; 7 - cases (**Figure 5**).

For extreme lateral and far lateral approaches, if there were violations of the lateral masses of the atlas or the articular process of the axis or occipital condyle, we used fixation; usually transpedicular from levels C2-C3 (sometimes C4) the occipital bone; used in 9 cases.

Fixation allows stabilizing the spine; this reduces the progression of kyphotic deformity of the cervical spine and the decrease due to this neurological deficit in a long-term observation group by 46.7% in the second group of observations in comparison with the first group of observations when fixations were performed much less frequently.

Based on the results of the comparison in the two periods, it is possible to make the following clear recommendations for the use of optimal surgical access and avoidance of complications.

MSCT angiography, selective angiography at the planning stage provides a clear justification for approach and prevents complications.

The choice of surgical approach in the removal of tumors of the spinal nerves of the cervical segment with paravertebral spread depends on the relationship of tumor bulk, the degree of spread and direction of its paravertebral component relative to the plane of the spinal cord, dura mater, conditional plane of physiological curvature, and topographic - anatomical classification. This approach optimizes the removal phase to ensure radical removal.

The posterior approach is convenient for removing SNSTs of the cervical segment from the paravertebral growth, with the predominance of the tumor located in the dorsal part.

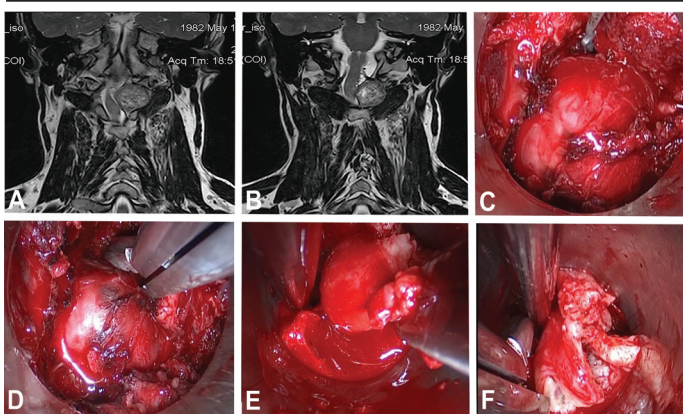
The posterior lateral approach, the best-known operations of this group, is hemi-posterior with a facetectomy. This approach gives a good overview not only of posterolateral paravertebral growth but also of the subdural dorsal and lateral subarachnoid spaces of the spinal cord.

The far-lateral approach is the most optimal and least traumatic at the ventral localization of tumors at the level of C1-C3 vertebrae. This approach allows us to reach the upper cervical spine and visualize the ventrolateral surface of the spinal cord and brain stem; this approach is convenient in case of the spread of extra vertebral component of the tumor in the ventral direction.

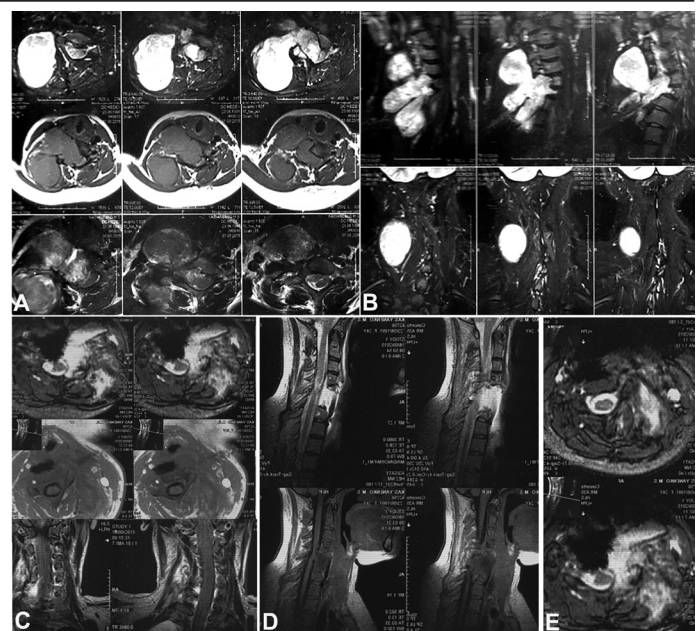
The extreme lateral approach allows you to visualize the anterior surface of the lower parts of the medulla oblongata and the upper segments of the spinal cord at the level of C1-C3 vertebrae. This surgical approach is the most optimal for removing SNSTs of a spine's cervical segment with para-vertebral growth in a ventrolateral direction.

The anterior or anterolateral approach is advantageous in removing SNSTs of the cervical segment with para-vertebral growth at the C3-C7 vertebrae level, which had a ventral distribution type.

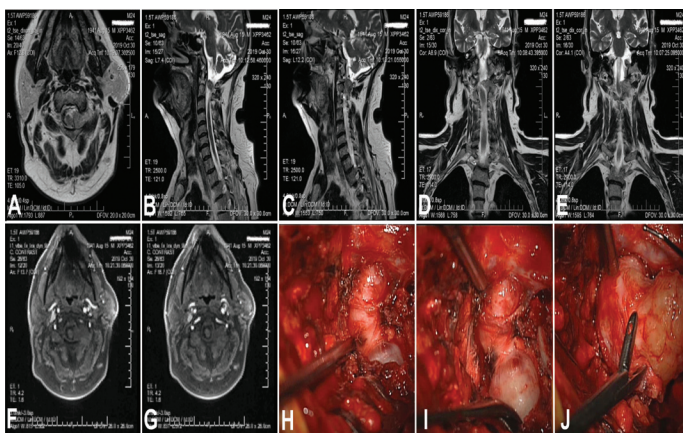
The use of anterior, far lateral and extreme lateral approaches to remove SNSTs at the cervical level with PG allows sufficient visual control of the vertebral artery during removal of such tumors. Direct visualization of the vertebral artery reduces the risk of its damage to zero.



**Figure 2:** SNST of C2 with lateral tumor growth. Compression VA from the posterior side. Far lateral approach, microsurgical removal with endoscopic assistance. A, B frontal MRI where seen SNST, compressed VA. C, D, E, F-endoscopic view; C - mobilizing tumor, D, E, F - Removing the tumor with parts of the conchotome.



**Figure 4:** Giant SNST, multinodular Ventral Tumor Growth (VTG), growth in the spinal canal and compression of the spinal cord. Lateral curvature of the cervical spine towards the tumor. Anterolateral approach, removal of the paravertebral part of the tumor. Exposure of the vertebral artery at the C5-C6 level, corpectomy C6, partly C5, removal of the tumor in the spinal canal, decompression of the spinal cord, corpectomy C5-C7 with a cage, fixation with a plate. MRI before surgery and 7 days after surgery. Total removal of the tumor. A - axial MRI T1, T2, B - frontal MRI T2, C - axial MRI T2, T1, frontal MRI T2 after surgery, D - sagittal MRI T2, T1 after surgery, E - axial MRI T2 after surgery.



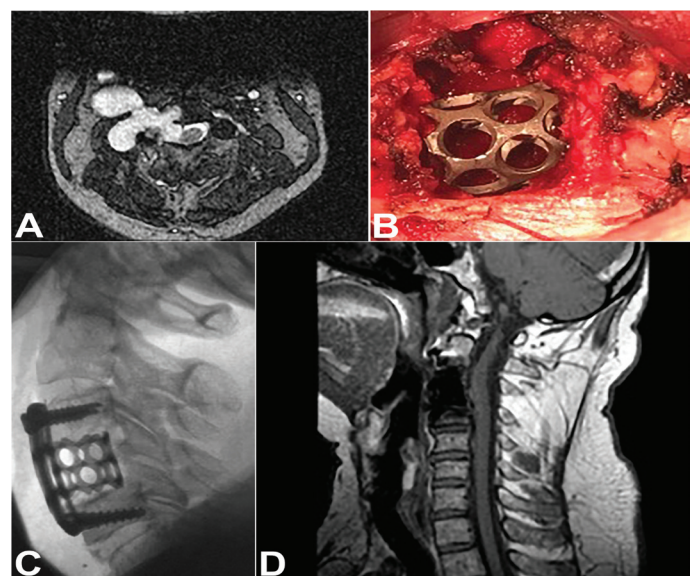
**Figure 3:** SNST of C2 with Dorsal Tumor Growth (DTG). Compression VA from the end of its posterior side, its ventral and lateral displacement. Posterior - lateral approach, microsurgical removal. A - axial MRI T2; B, C - sagittal MRI T2, D, E - frontal MRI T2; F, G - MRI angiography, where seen compression VA from the end of its posterior side its ventral and lateral displacement by SNST; H, I, J - microsurgery; H, I - mobilizing tumor, J - opening the tumor capsule and extracting the tumor with parts of the conchotome.

**Discussion**

SNSTs with DG are difficult for surgical removal because they grow through the spinal nerve canal, compress and displace vertebral artery, and cause destruction of the cervical vertebrae due to compression. Various approaches are used to remove the them, depending on the direction of tumor growth and familiarity with neurosurgeons' approaches [1,6].

The posterior approach is convenient for removing SNSTs of the cervical segment from the paravertebral growth, with the predominance of the tumor located in the dorsal part [5]. We used the posterior approach in 37 cases.

The posterior lateral approach, the best-known operations of this group, is hemi-posterior with a facetectomy. This approach gives a good overview not only of posterolateral paravertebral growth but also of the subdural dorsal and lateral subarachnoid spaces of the spinal cord. (Figure 3). This approach was used to remove tumors located laterally and dorsally during our study using 14 cases.



**Figure 5:** SNST at level C4 with VTG. Compression VA from the end of the posterior side, its ventral and medial displacement. The anterior approach, microsurgical removal. A - Axial MRI T2; B - tumor and vertebral body C4 removed, titanium mesh inserted between vertebral bodies C3-C5, C - lateral roentgenogram, D - MRI after surgery.

The far-lateral approach is the most optimal and least traumatic at the ventral localization of tumors at the level of C1-C3 vertebrae. This approach allows us to reach the upper cervical spine and visualize the ventrolateral surface of the spinal cord and brain stem; this approach is convenient in case of the spread of extra vertebral component of the tumor in the ventral direction [6].

The extreme lateral approach allows you to visualize the anterior surface of the lower parts of the medulla oblongata and the upper segments of the spinal cord at the level of C1-C3 vertebrae [7]. This surgical approach is the most optimal for removing SNSTs of a spine's cervical segment with para-vertebral growth in a ventrolateral direction.

The anterior or anterolateral approach is advantageous in removing SNSTs of the cervical segment with para-vertebral growth at the C3-C7 vertebrae level (Figure 4), which had a ventral distribution type [8].

The use of anterior, far lateral and extreme lateral approaches to remove SNSTs at the cervical level with PG allows sufficient visual control of the vertebral artery during removal of such tumors. Direct visualization of the vertebral artery reduces the risk of its damage to zero [9].

The most important for such tumors is a careful choice of approach depending on the direction of tumor growth and the features of compression of the vertebral artery, spinal cord, and surrounding structures. Thus, comparing the data on the quality of life shows that patients in the second group of observations were significantly more likely ( $p = 0.035$ ) to have a satisfactory condition (0 points on the ECOG-WHO scale) in the early and long-term postoperative period than patients in the first group of observations. In which 15 (45.4%) cases of group II and 6 (18.7%) cases in the second group in the early period and 12 (48%) cases in second group observations, 5 (33.3%) in first group in the long-term period. Thus, studies of the dynamics of recovery of patients with regression of neurological deficits in the early and later postoperative period show that the differentiated choice of surgical approaches to remove cervical SNSTs with DG provides a better quality of life in the second compare to the first group of observation.

### Conclusions

When analyzing the topographical and anatomical characteristics of the tumor of the spinal nerves of the cervical segment with paravertebral spread, the following distribution of location options were found: we detected 27.7% of tumor observations at the level of C1-C2 vertebrae, 41.5% - C2-C3 vertebrae, 7.7% - C3-C4 vertebrae, 4.6% - C4-C5 vertebrae, in 7.7% - C5-C6 vertebrae, 10.7% - C6-C7 vertebrae, 3% - C7-T1 vertebrae. Dislocation of the common carotid artery by the tumor was diagnosed in 12% and 24% of the vertebral artery.

In second group, in addition to Standard Neuroimaging Methods (MRI, MSCT) and the presence of changes in the location of the vertebral artery or the need for detailed imaging of the vertebral artery, MSCT angiography, selective angiography at the planning stage provides a clear justification for approach and prevents complications.

The choice of surgical approach in the removal of tumors of the spinal nerves of the cervical segment with paravertebral spread depends on the relationship of tumor bulk, the degree of spread and direction of its paravertebral component relative to the plane of the spinal cord, dura mater, conditional plane of physiological curvature, and topographic - anatomical classification. This approach optimizes the removal phase to ensure radical removal.

Comparative analysis of the first and second group of observations proved that the total removal of the SNSTs of the cervical segment from the DG requires the following reliable fixation of the spine. This reduces the progression of kyphotic deformity of the cervical spine and reduces the progression of neurological deficits in the long-term observation period by 46.7%.

Study of the relationship between duration of history and probability of the McCormick scale of transition to another group (improvement and regression of neurological disorders) after surgery showed that the longer the history, the less likely it is to move to another group.

The use of a differential method to choose a surgical approach in removing tumors of the spinal nerves of the cervical region with paravertebral spread provides high quality of life. Patients in the second group of observations had a satisfactory condition (0 points on the ECOG-WHO scale) in the early and long-term postoperative period than patients in the first group.

### References

1. Serrano JPM, Neves MWF, Marchi C, Nakasone FJ, Maldaun MVC, et al. Giant dumbbell C2C3 neurofibroma invading peribulbar cistern: Case report and literature review. *Surg Neurol Int.* 2019; 10: 77.
2. Zhan Z, Yan X, Nie W, Ding Y, Xu W, et al. Neurofibroma and Meningioma within a Single Dumbbell-Shaped Tumor at the Same Cervical Level without Neurofibromatosis: A Case Report and Literature Review. *World Neurosurg.* 2019; 130: 1-6.
3. Lavrador JP, Lascelles K, Ferner R, Thomas N, Zebian B. Neurofibroma of the cervical spine in infants. *Childs Nerv Syst.* 2016; 32: 2277-2279.
4. Waqar M, Huson S, Evans DG, Ealing J, Karabatsou K, et al. C2 neurofibromas in neurofibromatosis type 1: Genetic and imaging characteristics. *J Neurosurg Spine.* 2018; 30: 126-132.
5. Taleb FS, Guha A, Arnold PM, Fehlings MG, Massicotte EM. Surgical management of cervical spine manifestations of neurofibromatosis Type 1: Long-term clinical and radiological follow-up in 22 cases. *J Neurosurg Spine.* 2011; 14: 356-366.
6. Boumaza K, Michel G, Salaud C, Bossard C, Espitalier F, et al. Peripheral neck nerve tumor: A 73-case study and literature review. *Eur Ann Otorhinolaryngol Head Neck Dis.* 2019; 136: 455-460.
7. Safaee MM, Lyon R, Barbaro NM, Chou D, Mummaneni PV, et al. Neurological outcomes and surgical complications in 221 spinal nerve sheath tumors. *J Neurosurg Spine.* 2017; 26: 103-111.
8. Safaee M, Oh T, Barbaro NM, Chou D, Mummaneni PV, et al. Results of Spinal Fusion after Spinal Nerve Sheath Tumor Resection. *World Neurosurg.* 2016; 90: 6-13.
9. Abe J, Takami T, Naito K, Yamagata T, Arima H, et al. Surgical management of solitary nerve sheath tumors of the cervical spine: A retrospective case analysis based on tumor location and extension. *Neurol Med Chir (Tokyo).* 2014; 54: 924-929.