



Long-Term Outcome of Open Thoracolumbar Fracture Dislocation with Neurologic Deficits Treated with Ilizarov External Spinal Fixator: A Rare Case Report

Jean Marie Vianney Hope*; Jean Paul Bitega; Francis Mugabo; Edmond Mukimbili; Albert Ndata

Department of Orthopedics and Traumatology, Rwanda Military Hospital, Kigali, Rwanda

*Corresponding Author(s): Jean Marie Vianney Hope

Department of Orthopedics and Traumatology, Rwanda Military Hospital, P.O. Box: 3377 Kigali-Rwanda

Tel: +250789364492; Email: hopejmv@gmail.com

Abstract

Thoracolumbar junction is the transition segment between the relatively stiff thoracic spine and the mobile lumbar spine. This region especially predisposes for injury due to absence of costovertebral structures that provide additional supporter for vertebral column, and uncompleted transition to the full lumbar lordosis; and it is considered biomechanically the weakest point in the spine. The management of thoracolumbar fracture dislocation is highly controversial, and there is no generally accepted treatment method. However, unstable fracture dislocation requires either open or endoscopic internal fixation using either posterior or anterior approach or a combination of both. We report a particular case of a 32-year-old bank cashier who sustained, following aggression, open rotational injuries associating L1 – L2 dislocation and severe burst fracture of L2 associated with neurologic deficits treated with Ilizarov external fixator. The patient made an uneventful recovery of all neurological functions, and returned to his full-time employment. Seven years after surgery, the patient had a kyphosis of 9° that did not affect his activities of daily living.

Received: Jul 13, 2020

Accepted: Aug 28, 2020

Published Online: Sep 03, 2020

Journal: Neurology and Neurological Sciences: Open Access

Publisher: MedDocs Publishers LLC

Online edition: <http://meddocsonline.org/>

Copyright: © Vianney Hope JM (2020). *This Article is distributed under the terms of Creative Commons Attribution 4.0 International License*

keywords: Thoracolumbar junction; Fracture dislocation; Ilizarov External fixator; Recovery.

Introduction

The term of thoracolumbar spine (or thoracolumbar junction) refers the area made up of T11 to L2 vertebrae as described by Stagnara et al [1]. Thoracolumbar junction has unique anatomical and biomechanical features because of this segment is a transition region from the rigid kyphotic cephalad thoracic segment (T1 – T10) to the mobile lordotic caudal lumbar segment (L3 – L5); and for this is the region most commonly involved with traumatic spinal fractures and/or dislocations [1-5]. As the spinal cord ends at approximately the L1 – L2 level, and the roots of the cauda equina fill the canal, a variety of neurologic injury patterns can take place with a fracture and/or dislocation

at this level [6]. Despite the sophistication of modern injury analysis schemes and modernized instrumentation techniques, the main goals of treatment have not changed, that are, to protect or recover neurologic function, prevent pathologic collapse or deformity of the spinal column, and maximize clinical outcomes [7-12]. However, the management of thoracolumbar fracture dislocation is highly controversial, and controversies exist regarding the appropriate radiological investigations, the indications for surgical management and the timing, approach and type of surgery [13-15]. Despite these advances, internal fixation is not indicated for all patients. As in our case where the



Cite this article: Vianney Hope, Bitega JP, Mugabo F, Mukimbili E, Ndata A. Long-Term Outcome of Open Thoracolumbar Fracture Dislocation with Neurologic Deficits Treated with Ilizarov External Spinal Fixator: A Rare Case Report: *Neurol Neurol Sci Open Access* . 2020; 3(1): 1016.

risk of infection was high; external fixation plays an important role. External fixation in spine is being largely used for cervical spine injuries [16-19]. The Ilizarov external fixator was developed in the 1970s and is widely used for spinal disease in Russia [2]. The purpose of this report is to present the case of a 32-year-old man who sustained, following aggression, a type-C open rotational injuries associating L1 – L2 dislocation and severe burst fracture of L2 associated with neurologic deficits treated with an Ilizarov external spinal fixator. We aimed to describe the surgical technique used and long-term outcome.

Case report

A 32-year-old bank cashier was transferred to our hospital from local clinic 7 days after a violent aggressive attack. He was attacked by 4 aggressors who wanted to steal his money and severely beaten with sticks. On arrival, he was lying in a stretcher; healthy appearing but in severe pain; alert and oriented; responds appropriately; in no acute distress and his general status was conserved. Foley's catheter was in situ with clear urine. Blood pressure measurement revealed a pressure of 135/75 mmHg, his pulse rate was 88 beats/minute and his respiratory rate was 21 cycles/minute. On inspection, there were extended skin abrasions on both elbows; a clean sutured linear scalp wound of 7 cm and 2 linear, dirty, soiled, bad smearing wounds on the back measuring respectively 1 cm X 2 cm and 1 cm X 3 cm (**Figure 1**). Urgent tetanus toxoid was given. Neurological examination revealed paraparesia; no motor function. There was preservation of sensory only below L1 dermatomal distribution including S4 – S5 segment. He was ASIA B on the American Spinal Injury Association (ASIA) scaling system. Osteo-tendinous reflexes of lower extremities (patellar and Achilles) were absent. Pathologic reflexes (Hoffman, Wartenberg, and Babinski) were negative. Bulbocavernous reflex was Present. There was no priapism. Rectal tone and continence were preserved.

Anteroposterior (AP) and lateral conventional radiographs of the thoracolumbar spine showed rotational injury associating L1 – L2 dislocation and burst fracture of L2 (**Figure 2**). Reconstructed coronal, sagittal and 3D Computed Tomography (CT) scans confirmed the rotational injury with L1 – L2 dislocation, split burst fracture of L2 and fractures of bilateral transverse processes of L3 and L4 (**Figure 3**). Reconstructed axial CT scans of L2 showed rotational burst split fracture without retropulsion of bony fragments into the spinal canal which has conserved its normal height (**Figure 4**). Reconstructed axial CT scans of L1 and L3 showing the displacement of the splitted fragments of L2 vertebra at the levels of L1 and L3 respectively, fracture of both pedicles of L1, but the height of the spinal canal was preserved at these levels (**Figure 5**). The lesion was classified according to AO/Magerl C1.3.2 and the thoracolumbar injury classification and severity score (TLICS) was 9.

Emergency surgery was planned to decompress the spine on the basis of the incomplete nature of his spinal cord injury and a TLICS of nine. Preoperative blood examination revealed WBC 10200/ μ l, Hb 14.5 g/dl and C-Reactive Protein 42 mg/dl. Due to the high risk of infection, an internal fixation was not possible. We opted for an Ilizarov external spinal fixator. The patient consented. Under general anesthesia, the patient was in prone position on a translucent orthopedic table with thoracic and pubic support keeping the abdomen free and sciatic nerve relaxed. After extensive debridement of two wounds in

the back, landmarks from T12 to L3 were made under fluoroscopic guidance. A posterior midline skin incision of 15cm was made and subcutaneous tissues and the fascia were incised and the spinous processes exposed. Lumbar paravertebral muscles were detached, lamina and transverse processes were exposed. The pedicular half pins were inserted in T12 – T11 proximally and L3 – L4 distally under fluoroscopic guidance (**Figure 6**).

The reduction was made by traction on the pins and using a spatula. L1 – L2 laminectomy was carried out. Intraoperatively, we found that the spinal cord was folded but not transected. No bone fragment was seen in the spinal canal. We performed the spinal cord and foraminal decompression to enhance recovery and restored anatomical alignment. We cleaned with warm normal saline. Closure was made layer by layer and the wound drainage system was inserted, and dry dressing was made. We maintained the reduction by mounting the Ilizarov apparatus (**Figure 7**). The duration of operation was 5 hours and blood loss was 500 cc. Postoperative AP and lateral radiographs were satisfactory (**Figure 8**). Postoperatively, he was under antibioprophyllaxis, oral analgesic, anticoagulation therapy and methylprednisolone sodium succinate (MPSS) with 1.8 g as loading dose and 0.3 g hourly as the maintaining dose. The postoperative course was uneventful; the wound drainage was removed after 73 hours, and started immediately sitting position. He was scheduled for intensive rehabilitation and recovered progressively all his neurologic functions. He started walking with aids at day 12 postoperatively (**Figure 9**). The wound healed well and skin sutures were removed after 3 weeks. Pins were cleaned regularly and once a week.

He was discharged at day 22 postoperatively. He continued weekly pedicle pin care and regular rehabilitation. At day 45 postoperatively, he was able to walk independently, and do slight movement of the thoracolumbar spine (**Figure 9**). At 3-month-follow up, control radiographs showed a well-maintained Ilizarov apparatus with good sagittal alignment and bone fusion. (**Figure 10**). He was pain-free. Thus, the Ilizarov apparatus was removed without anesthesia. He thereafter continued rehabilitation program. At 8-month-follow up, he was satisfied with the treatment made and was allowed to return to his full-time employment.

At 7-year-follow up, the patient had a kyphosis of 9° that did not affect his activities of daily living. He had no pain or tenderness and could walk without problems. He was able to perform all movements of the thoracolumbar spine (flexion-extension, internal and external rotation) without pain and any limitation (**Figure 11**). His Health related quality of life (HRQoL) was assessed using the Oswestry Disability Index (ODI) which comprises 10 dimensions (pain, self-care, lifting, walking, sitting, standing, sleeping, sex life, social life, and traveling) with each scored on six levels (ranging from: 0 no problems to 5 extreme problems) and leading after summation to a five scale disability index (ranging from minimal disability to bed-bound). His ODI score was 6%. Using the EQ-5D health questionnaire comprised of 5 dimensions (mobility, self-care, usual activities, pain/discomfort, and anxiety/depression) with 3 levels (no problems; some problems and extreme problems), he scored 0% (no problems for any of the five dimensions). Overall, his long-term functional outcome was satisfactory as he could cope with all his daily activities.

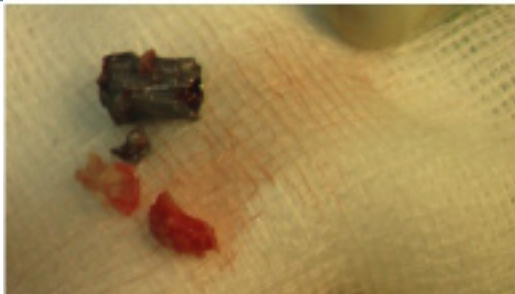
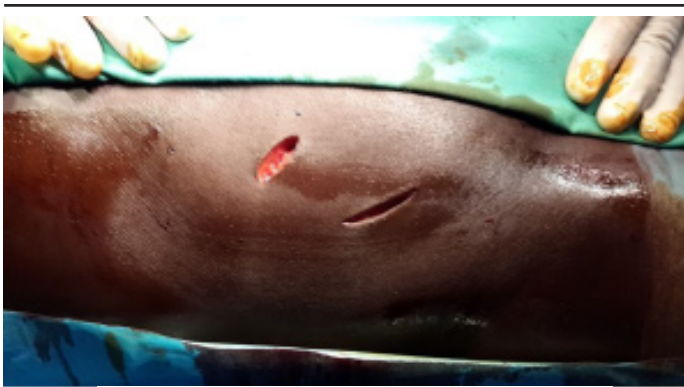


Figure 1: Preoperative image showing two linear wounds after extensive debridement and removed debris.

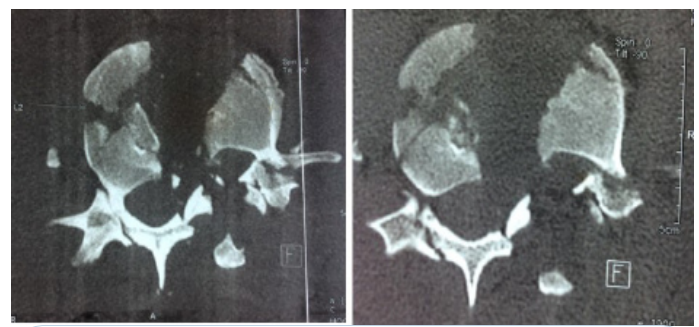


Figure 4: Reconstructed axial CT scans of L2 showing rotational burst split fracture without retropulsion of bony fragments into the spinal canal which has conserved its normal height.

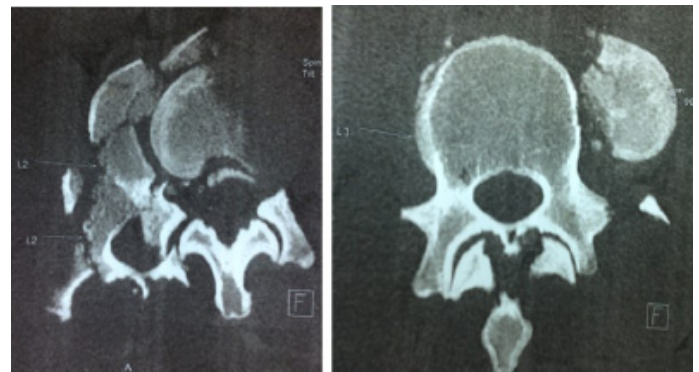


Figure 5: Reconstructed axial CT scans of L1 and L3 showing the displacement of the splitted fragments of L2 vertebra at the levels of L1 and L3 respectively, fracture of both pedicles of L1. The spinal canal is preserved.

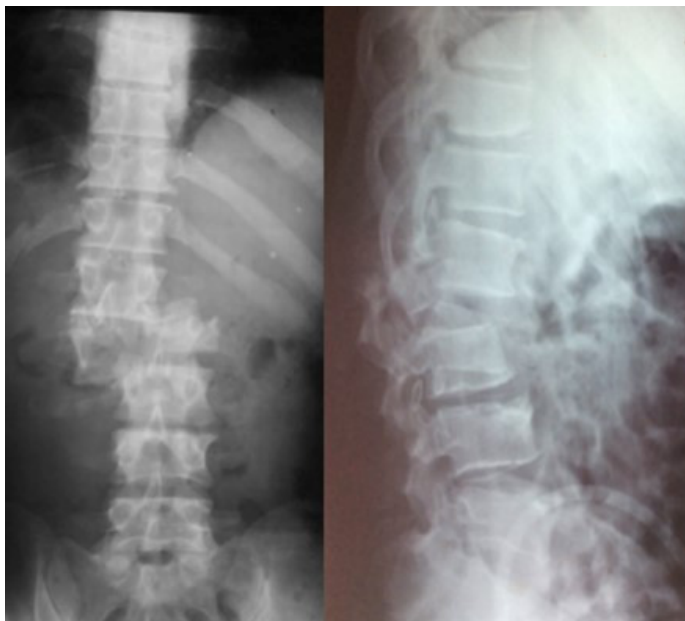


Figure 2: Preoperative AP and lateral radiographs of the thoracolumbar spine showing rotational injury associating L1 – L2 dislocation and severe burst fracture of L2.

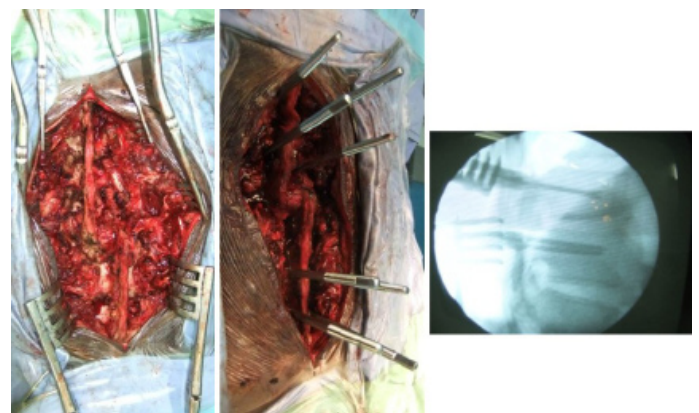


Figure 6: Intraoperative views showing an exposure of the posterior approach and pedicle pins placement in T12 – T11 proximally and L3 – L4 distally under C-arm guidance.

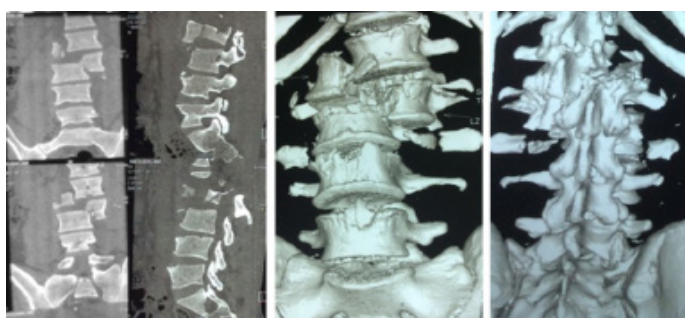


Figure 3: Reconstructed coronal, sagittal and 3D CT scans showing the rotational injury with L1 – L2 dislocation, split burst fracture of L2 and fractures of bilateral transverse processes of L3 and L4.

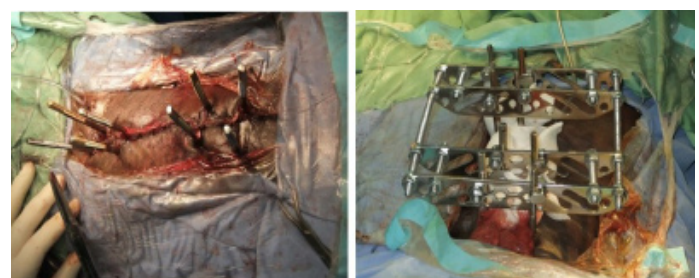

Figure 7: Operative views showing skin closure and mounting of Ilizarov apparatus.

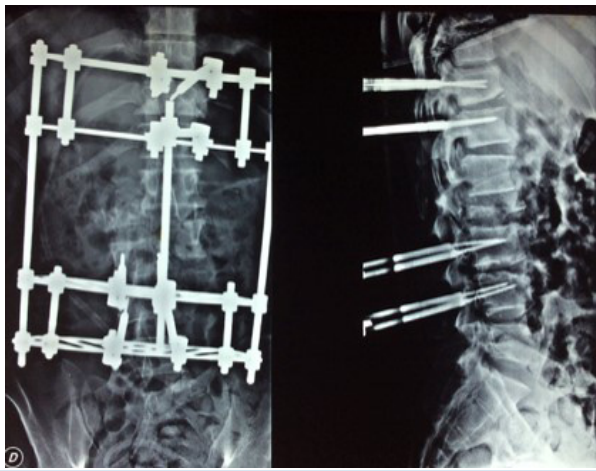


Figure 8: Immediate postoperative AP and lateral radiographs showing well positioned pedicle pins in T12 – T11 proximally and L3 – L4 distally and well mounted Ilizarov apparatus. The anatomic sagittal alignment of the spine is restored.

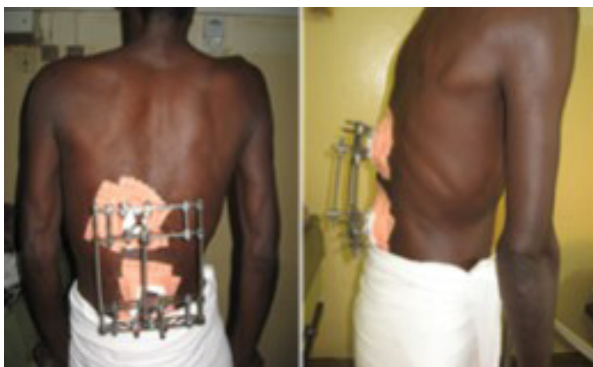

Figure 9: Images taken at day 12 (left) and 45 (right) postoperatively, showing respectively walking with aids and independently walking with some range of motion of the thoracolumbar spine.

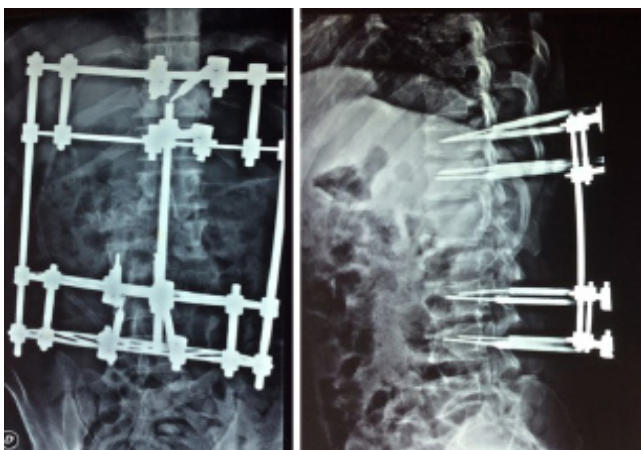


Figure 10: At 3-month-follow up, control AP and lateral radiographs showing a well-maintained Ilizarov apparatus with good sagittal alignment and bone fusion. No secondary displacement.

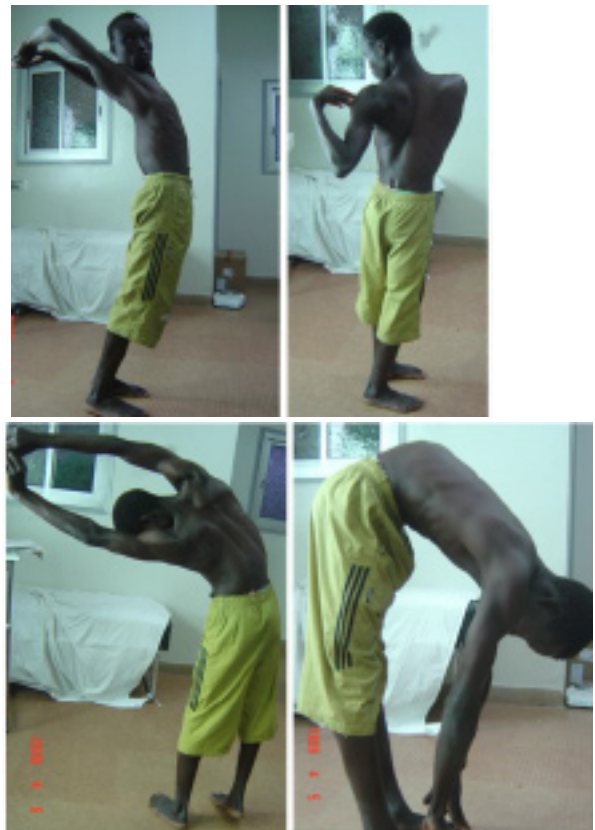

Figure 11: At 7-year-follow up, images showing normal locomotor function and neurological status with painless full range of motion in hyperextension, internal and external rotation, bending left and right and hyperflexion.

Discussion

Thoracolumbar fractures and/or dislocations are common injuries resulting from motor vehicle collisions (MVC, 40% to 45%), voluntary or involuntary falls from height (15% to 30%), sport/leisure accidents (15% to 25%), work accidents and aggressions [4-20,21]. Young patients are mainly male with high-energy trauma, whereas falls are mainly implicated for older victims [20-22]. Thoracolumbar traumatic spinal fractures and/or dislocations are frequent as this region represents the transition zone between the relatively immobile thoracic kyphosis and the more mobile lumbar lordosis [3-6,23]. The spinal cord ends approximately at L1–L2 level, meaning that fractures and/or dislocations at this level or below, generally displays as cauda equina syndrome whereas above L1 can be associated by spinal cord compression symptoms [5,24]. A full motor and sensory examination should be performed and scored according to the ASIA classification scheme. Rectal exams are done to assess tone, voluntary control, and the bulbocavernosus reflex [25]. Plain radiographs, and especially if three dimensional (3D) CT in modern trauma facilities is added, will demonstrate most bone injuries. If the level of neurology and the apparent spinal level of injury do not closely align, then a magnetic resonance imaging (MRI) of the entire spine should be obtained to try to verify the actual cause of the deficit [26-29]. After clinical examination and imaging studies, the lesions have to be classified and planned for accurate management [9]. In our case, it was a 32-year-old man involved in violent aggression and sustained an open L1-L2 fracture dislocation with incomplete spinal cord injury (SCI) ASIA B. Plain radiographs and CT scan were sufficient to analyze the lesions. MRI was not required. The lesion was classified according to AO/Magerl C1.3.2 (rotational split burst) and TLICS was 9. The literature about open thoracolumbar

bar injuries is scanty; thus our case presents uniqueness of being an open lesion.

Despite the sophistication of modern injury analysis schemes and modernized instrumentation techniques, the main goals of treatment have not changed, that are, (1) spinal cord and foraminal decompression to enhance recovery, (2) restoring sagittal balance, (3) early stabilization to allow rehabilitation and gait, (4) prevention of progressive deformity with neurological manifestations and (5) preserve the spine functions by achieving adequate fusion [3,21,30]. However, high degree of controversy and wide variation in the treatment of traumatic Thoracolumbar (TL) spine injuries exists; there is no universally accepted algorithms to decide whether a patient needs surgical intervention and if so what the appropriate surgical technique should be [6,30]. Historically, the guidelines for operative treatment included greater than 50% loss of vertebral body height, greater than 50% canal compromise, greater than 30° of kyphosis, injury of the posterior ligamentous complex or the presence of neurologic deficits [21,31,32]. There are numerous options for the surgical treatment of unstable TL fractures and/or dislocations or those with neurologic injury. They can be approached through an anterior, posterior, or combined technique, and using either open or endoscopic methods. The combined approach allows for the greatest stability, minimizes the number of levels fused, and allows for a direct decompression of the spinal canal. Unfortunately, this technique comes with a higher morbidity, frequent ileus, and longer recovery times [21].

Newer techniques have attempted to use minimally invasive techniques to decrease the associated morbidity. Whenever possible, the endoscopic approach offers significant advantages, mainly seen in lower pain postoperatively, esthetic results, less morbidity and quicker return to daily activities. Reports show less time with pain medication in 31% compared to open 42% [3]. These include: combining vertebral augmentation with pedicle screw instrumentation [3]; transpedicular corpectomy with expandable cage combined with pedicle screw fixation [33,34]; minimally invasive anterior corpectomy and posterior fixation technique [21]; endoscopically assisted simultaneous postero-anterior reconstruction of the thoracolumbar spine in prone position [35]; transpedicular fixation combined with transpedicular cancellous bone graft and posterior fusion [36]; thoracoscopic transdiaphragmatic approach to thoracolumbar junction fractures and pedicle screw instrumentation and balloon assisted end plate reduction (BAER) [15].

Combination of techniques has been also reported in literature. Percutaneous augmented instrumentation (PAI) is a novel approach, combining all three elements: (1) percutaneous SSPI (posterior short-segment pedicle instrumentation) of one vertebra cranial and one vertebra caudal to the fracture; (2) balloon kyphoplasty of the fractured vertebra; and (3) augmentation of the pedicle screws with polymethyl methacrylate (PMMA). However, certain concerns arise from this technique. The first is the risk of PMMA leakage through the fracture lines into the spinal canal or to adjacent soft tissue. The second concern is PMMA emboli. PMMA can leak through segmental veins into the inferior vena cava and reach the lungs. A third concern pertains to the use of PMMA in younger patients [38].

Controversy still exists over how many segments should be fixed when treating a thoracolumbar fracture. Some studies have shown that 2 vertebrae above and 2 below are best, giving adequate rigidity and consequently better stability. Other

studies have reported that a long instrumentation sacrifices unnecessary segments that are not damaged, and fixing 1 above and 1 below fractured vertebrae attains equal stability but less rigidity and preserved healthy segments. Recently, there have been reports that an intermediate screw in the fractured vertebrae augments rigidity with higher fusion rates and less time in achieving it. They also mention that it helps acquire better alignment [3]. The cross-link or transverse traction device has been used to add rigidity to the instrumentation, having as main goal to diminish the lever arm in the construct. This is why they are very useful in long instrumentations or in kyphosis (thoracolumbar union). In short segment instrumentations, with or without screw in the fractured vertebrae, reports have shown similar results regarding fusion rates and stability with or without the cross-link [3]. Despite these advances, internal fixation is not indicated for all patients. As in our case where the risk of infection was high; external fixation plays an important role. External fixation in spine is being largely used for cervical spine injuries [16-19]. The Ilizarov external fixator was developed in the 1970s and is widely used for spinal disease in Russia [2]. Use of external fixation to treat thoracolumbar fractures and/or dislocation has some disadvantages; it cannot decompress the spinal canal and allow bone grafting, there is a risk of pin damage and a loss of correction after hardware removal, and it causes discomfort in activities of daily living (e.g. patients cannot lie on their back). Some advise a bed with a hole. Nonetheless, the Ilizarov external fixation is less invasive than the anterior or posterior procedures, less damaging to soft tissue, allows easier removal of the hardware (no anesthesia is needed), and is capable of correcting the kyphosis after surgery. Patients can leave bed [2]. In this report, we have largely presented the use of external fixation using Ilizarov apparatus in management of open thoracolumbar injuries associated with neurologic deficits where internal fixation could not be indicated. The overall long-term outcomes were satisfactory.

Controversies also exist regarding the pharmacology of SCI. If a SCI is tentatively identified, there exists literature to suggest that high-dose steroids may have an effect on facilitating recovery [20,39]. Its method of action has been attributed to anti-inflammatory or antioxidant properties. Methylprednisolone (MP) has been shown to improve oligodendrocyte survival and decrease the extent of intramedullary spinal cord hemorrhage in treated patients [40-44]. Our patient has received 1.8 g as loading dose and 0.3 g hourly as maintenance dose of methylprednisolone sodium succinate (MPSS).

In different studies conducted on treatment of traumatic thoracolumbar fracture dislocation with neurologic deficits, objective outcome parameters such as EQ-5D and ODI pointed to a favorable overall result. All patients remained neurologically intact, fully ambulatory and all fractures fused with less residual deformity at a minimum of 6-year-follow up. Combining EQ-5D and ODI data showed that 21% of the patients had considerably and consistently worse outcomes [14,15,45-49]. McLain reviewed 62 patients treated with instrumented fusions for unstable thoracolumbar fractures at 5 years and found that 70% were able to return to work full time. Fifty-four percent were at their previous level or work without restrictions, whereas 16% were full time but with lighter jobs [50]. In our case, the ODI score was 6% and the only limitation he complained is that he felt slight pain while lifting heavy weights off the floor, but he could manage if they were conveniently positioned (i.e. on a table). Overall, his functional outcome was satisfactory and had returned to his full-time employment.

Conclusion

As well as the satisfactory global long-term outcomes, and given the local and general surgical environment, one can agree for taken option of Ilizarov external spinal fixator in the management of open thoracolumbar fracture dislocation with neurologic deficits. Interestingly, the patient initially suffering ASIA B paraparesia eventually fully recovered to ASIA E, and fixation with Ilizarov device resulted in successful reduction and fusion.

Funding: No benefits in any form have been received or will be received from a commercial party related directly or indirectly to the subject of this article.

Ethical approval: This article does not contain any studies with human participants or animals performed by any of the authors.

Informed consent: Written informed consent was obtained from the patient to publish the information, including her photographs.

Authors' Contributions: All authors have participated equally in the present study.

References

1. Stagnara P, De Mauroy JC, Dran G, Gonon GP, Costanzo G, et al. Reciprocal angulation of vertebral bodies in a sagittal plane: Approach to references for the evaluation of kyphosis and lordosis. *Spine (Phila Pa 1976)*. 1982; 7: 335-342.
2. Matsubara H, Tsuchiya H, Kawahara N, Kobayashi T, Morinaga T, Tomita K. Ilizarov external fixator for burst fracture of the lumbar spine: a case report. *Journal of Orthopaedic Surgery*. 2007; 15:380-3.
3. Cahueque M, Cobar AS, Zuñiga C, Caldera G. Management of burst fractures in the thoracolumbar spine. *Journal of Orthopaedics*. 2016; 13: 278-281.
4. Holmes JF, Miller PQ, Panacek EA, et al. Epidemiology of thoracolumbar spine injury in blunt trauma. *Acad Emerg Med*. 2001; 8:866-872.
5. Kim BG, Dan JM, Shin DE. Treatment of thoracolumbar fracture. *Asian Spine J*. 2015; 9:133-146.
6. Wood KB, Li W, Lebl DS, Ploumis A. Management of thoracolumbar spine fractures. *The Spine Journal*. 2014; 14: 145-164.
7. Aebi M, Etter C, Kehl T, Thalgott J. Stabilization of the lower thoracic and lumbar spine with the internal skeletal fixation system: indications, techniques, and first results of treatment. *Spine*. 1987; 12:544-51.
8. Kaya RA, Aydın Y. Modified transpedicular approach for the surgical treatment of severe thoracolumbar or lumbar burst fractures. *The Spine Journal*. 2004; 4: 208-217.
9. Lee JY, Vaccaro AR, Lim MR, Öner FC, R. John Hulbert RJ, et al. Thoracolumbar injury classification and severity score: a new paradigm for the treatment of thoracolumbar spine trauma. *J Orthop Sci*. 2005; 10:671-675.
10. Nicoll EA. Fractures of the dorso-lumbar spine. *J Bone Joint Surg Br* 1949; 31: 376.
11. Radcliff KE, Kepler CK, Delasotta LA, Rihn JA, Harrop JS, et al. Current management review of thoracolumbar cord syndromes. *The Spine Journal*. 2011; 1: 884-892.
12. Schnee CL, Ansell LV. Selection criteria and outcome of operative approaches for thoracolumbar burst fractures with and without neurological deficit. *J Neurosurg*. 1997; 86:48-55.
13. Rajasekaran S, Kanna RM, Shetty AP. Management of thoracolumbar spine trauma: An overview. *Indian J Orthop*. 2015; 49: 72-82.
14. Reinhold M, Knop C, Beisse R, Audigé L, Kandziora F, et al. Operative treatment of 733 patients with acute thoracolumbar spinal injuries: comprehensive results from the second, prospective, internet-based multicenter study of the Spine Study Group of the German Association of Trauma Surgery. *Eur Spine J*. 201; 19:1657-1676.
15. Verlaan JJ, Diekerhof CH, Buskens E, van der Tweel I, Verbout AJ, et al. Surgical treatment of traumatic fractures of the thoracic and lumbar spine: a systematic review of the literature on techniques, complications, and outcome. *Spine*. 2004; 29: 803-814.
16. Hope JMV, et al. Treatment of pediatric multilevel cervical spine fractures in resource-limited settings: A case report. *Child's Nervous System*. <https://doi.org/10.1007/s00381-018-3966-8>.
17. Jayaram M, Kumar P, Khanal GP, Singh MP, Singh GK, Karn NK, Shrestha A (2008) Improvised cost-effective halo vest brace using a recycled Ilizarov ring and a threaded rod. *Trop Dr*. 2008; 38: 96-97.
18. Longo UG, Denaro L, Campi S, Maffulli N, Denaro V. Upper cervical spine injuries: indications and limits of the conservative management in Halo vest. A systematic review of efficacy and safety. *Injury*. 2010; 41: 1127-1135.
19. Sane JC, Hope JMV, et al. Modified external fixator in pediatric multilevel noncontiguous cervical spinal fracture dislocation: A case report. *Journal of Orthopaedic Science*. 2018.
20. Charles YP, Steib JP. Management of thoracolumbar spine fractures with neurologic disorder. *Orthopaedics & Traumatology: Surgery & Research* 101 2015; S31-S40.
21. Eck JC. Minimally invasive corpectomy and posterior stabilization for lumbar burst fracture. *The Spine Journal*. 2011; 11:904-908.
22. Katsuura Y, Osborn JM, Cason GW. The epidemiology of thoracolumbar trauma: A meta-analysis. *Journal of Orthopaedics*. 2016; 13:383-388.
23. Schroeder GD, Kepler CK, Koerner JD, et al. Is there a regional difference in morphology interpretation of A3 and A4 fractures among different cultures? *J Neurosurg Spine*. 2015; 9:1-8. 4.
24. Holdsworth F. Fractures, dislocations, and fracture-dislocations of the spine. *J Bone Jt Surg Am*. 1970; 52:1534-1551.
25. American Spinal Injury Association. International standards for neurological and functional classification of spinal cord injury. Chicago, IL: American Spinal Injury Association. 1996.
26. Dalinka MK, Kessler H, Weiss M. The radiographic evaluation of spinal trauma. *Emerg Med Clin North Am*. 1985; 3:475-90.
27. Hauser CJ, Visvikis G, Hinrichs C, et al. Prospective validation of computed tomographic screening of the thoracolumbar spine trauma. *J Trauma* 2003; 55:228-34.
28. Keene JS. Radiographic evaluation of thoracolumbar fractures. *Clin Orthop*. 1984; 216:58-64.
29. Tarr RW, Drolshagen LF, Kerner TC, et al. MR imaging of recent spinal trauma. *J Comput Assist Tomogr*. 1987; 11:412-7.
30. Öner FC, Wood KB, Smith JS, Shaffrey CI. Therapeutic Decision Making in Thoracolumbar Spine Trauma. *SPINE*. 200; 35: S235-S244.

31. Vaccaro AR, Rihn JA, Saravanja D, et al. Injury of the posterior ligamentous complex of the thoracolumbar spine: A prospective evaluation of the diagnostic accuracy of magnetic resonance imaging. *Spine*. 2009; 34: E841–7.
32. Vaccaro AR, Zeiller SC, Hurlbert RJ, et al. The thoracolumbar injury severity score: a proposed treatment algorithm. *J Spinal Disord Tech*. 2005; 18:209–15.
33. Howard BM, Sribnick EA, Dhall SS. Complete neurologic recovery of spinal cord injury after posterior transpedicular reconstruction for traumatic lumbar burst fracture. *The Spine Journal*. 2013; 13:204–205.
34. Lu DC, Lau D, Lee JG, Chou D. The transpedicular approach compared with the anterior approach: an analysis of 80 thoracolumbar corpectomies. *J Neurosurg Spine* 2010; 12: 583–91.
35. Akhil P, Hoelzl A, Lill H, Katscher S, Glasmacher S, et al. The endoscopically assisted simultaneous posteroanterior reconstruction of the thoracolumbar spine in prone position. *The Spine Journal*. 2004; 4: 540–549.
36. Lefterink VJM, Zimmerman KW, Veldhuis EFM, ten Vergert EM, ten Duis HJ. Thoracolumbar spinal fractures: radiological results of transpedicular fixation combined with transpedicular cancellous bone graft and posterior fusion in 183 patients. *Eur Spine J*. 2001; 10: 517–523.
37. Kim DH, Jahng TA, Balabhadra RSV, Potulski M, f Beisse R. Thoracoscopic trans diaphragmatic approach to thoracolumbar junction fractures. *The Spine Journal*. 2004; 4: 317–328.
38. Rahamimov N, Mulla H, Shani A, Freiman S. Percutaneous augmented instrumentation of unstable thoracolumbar burst fractures. *Eur Spine J*. 2012; 21: 850–854.
39. Bracken MB, Shepard MJ, Holford TR, et al. Administration of methyl-prednisolone for 24 or 48 hours or tirilazadmesylate for 48 hours in the treatment of acute spinal cord injury. Results of the Third National Acute Randomized Controlled Trial. National Acute Spinal Cord Injury Study. *JAMA*. 1997; 277:1597–605.
40. Bydon M, Lin J, Macki M, Gokaslan Z, Bydon A. The current role of steroids in acute spinal cord injury. *World Neurosurg*. 2014; 8:848–854.
41. Eck JC, Nachtigall D, Humphreys SC, Hodges SD. Questionnaire survey of spine surgeons on the use of methylprednisolone for acute spinal cord injury. *Spine*. 2006; 31: E250–3.
42. Evaniew N, Noonan VK, Fallah N, et al. Methylprednisolone for the treatment of patients with acute spinal cord injuries: a propensity score-matched cohort study from a Canadian Multi-Center Spinal Cord Injury Registry. *J Neurotrauma*. 2015; 32:1674–1683.
43. Lee JM, Yan P, Xiao Q, et al. Methylprednisolone protects oligodendrocytes but not neurons after spinal cord injury. *J Neurosci*. 2008; 28:3141–9.
44. Leypold BG, Flanders AE, Schwartz ED, Burns AS. The impact of methylprednisolone on lesion severity following spinal cord injury. *Spine*. 2007; 32:373–8; 379–381.
45. Fairbank JC, Pynsent PB, The Oswestry Disability Index. *Spine* 2000; 25(22):2940-2952.
46. Fairbank JCT, Couper J, Davies JB. The Oswestry low Back Pain Questionnaire. *Physiotherapy*. 1980; 66: 271-273.
47. Mehra A, Baker D, Disney S, Pynsent PB. Oswestry disability index scoring made easy. *Ann R Coll Surg Engl*. 2008; 90: 497–499.
48. Pneumaticos SG, Triantafyllopoulos GK, Giannoudis PV. Advances made in the treatment of thoracolumbar fractures: Current trends and future directions. *Injury, Int. J. Care Injured*. 2013; 44: 703–712.
49. Roland M, Fairbank J. The Roland-Morris Disability Questionnaire and the Oswestry Disability Questionnaire. *Spine*. 2000; 25: 3115-3124.
50. McLain RF. Functional outcomes after surgery for spinal fractures: Return to work and activity. *Spine*. 2004; 29: 470–477.