



Tapered Biweekly Vincristine Dosing Regimen: A Safer way to Manage Canine Transmissible Venereal Tumor

Dominic Osei^{1,2*}; Enoch Obeng¹; Alfred Adjiri-Awere^{3,4}; Obed Danso Acheampong¹

¹Small Animal Teaching Hospital, School of Veterinary Medicine, College of Basic and Applied Sciences, University of Ghana.

²Institute of Anatomy and Cell Biology/ Institute of Veterinary Pathology, Justus Liebig University-Giessen, Germany.

³Consultant and Senior Veterinary Pathologist (Drug Safety Evaluation)/Drug Development Focus, Montreal, Canada.

⁴Visiting Senior Lecturer, School of Veterinary Medicine, College of Basic and Applied Sciences, University of Ghana.

*Corresponding Author(s): **Dominic Osei**

Veterinary Clinician, Small Animal Teaching Hospital, School of Veterinary Medicine, College of Basic and Applied Sciences, University of Ghana, P.O. Box LG68, Legon-Accra, Ghana

Email: dominicosei@ymail.com/dosei@ug.edu.gh

Abstract

Canine Transmissible Venereal Tumor (CTVT) occurs mainly in dogs, and is endemic in tropical and subtropical regions of the world. This report documents the chemotherapeutic protocol that treated effectively a longstanding and metastasized CTVT in a 14 Kg 6-year-old intact Ghanaian indigenous male dog. Grossly, a few ulcerated, mainly subcutaneous, granulomatoid, variably-sized and soft nodular growths at the dorsum of the cervico-thoracic region of body trunk were identified. Similar masses occurred at the perineum, on the glans penis, around the bulbus glandis and in the inguinal lymph nodes; cytological examination of lesions revealed CTVT. Due to severe adverse reactions associated with the initial 0.6 mg/m² tumor surface area of vincristine dose, the patient was rescheduled to receive doses after every 2 weeks, where each subsequent dose was half of the previous. Total remission of all granulomas was achieved after three doses of vincristine. In the light of discovering novel approaches for improved and targeted chemotherapy, aimed at reducing adverse reactions and enhancing therapeutic successes, this case report presents a promising therapeutic regime for further assessment and validation regarding vincristine sulphate use. Hereby, clinicians may consider treating CTVT in dogs with vincristine dosing of once every two weeks, whilst halving each preceding dose for the next.

Received: Jul 02, 2020

Accepted: Aug 21, 2020

Published Online: Aug 25, 2020

Journal: Journal of Veterinary Medicine and Animal Sciences

Publisher: MedDocs Publishers LLC

Online edition: <http://meddocsonline.org/>

Copyright: © Osei D (2020). *This Article is distributed under the terms of Creative Commons Attribution 4.0 International License*

Keywords: Canine Transmissible Venereal Tumor; Metastasis; Total remission; Halved doses; Biweekly; Vincristine sulphate.



Background

Vincristine monotherapy remains the most effective, less expensive and practical treatment of canine transmissible venereal tumor (CTVT) [1,2]. Recommendations for vincristine therapy for CTVT is a dose of 0.025 mg/kg of body weight or 0.75 mg/m² of tumor surface area, once weekly, up to two weeks beyond the total disappearance of any attributable macroscopic lesion [2,3]. However, the use of vincristine in dogs is often associated not only with transient adverse reactions such as anorexia, vomiting, depression and leucopenia, but also fatal consequences [2]. Transiently or permanently impaired spermatogenesis has also been reported; moreover, other reports assert that semen quality may or may not be regained after vincristine treatment of male dogs. These responses vary based on individual male dogs [2,4,5]. Adverse reactions are sometimes debilitating, and may even lead to death [8,10,15]. The potential risks due to adverse reactions associated with vincristine use emphasize the need for novel approaches towards improved and efficient therapeutic outcomes [6,7].

CTVT is well-known to be transmitted naturally through transplantation of tumor cells; it occurs in dogs of both sexes [8,9]. Except for Antarctica, the disease has been reported on all the continents of the world [10,11]. It is ubiquitous and asserted to be enzootic in the subtropics and tropics involving parts of Africa, Central and South America, the far East, Middle-East, south-east Europe, China, Ireland, and the southern United States. In areas where CTVT is rarely reported, like North America and North and Central Europe, it is ascribed to stringent stray dog population control, and effective pre-breeding examinations, as well as treatment of clinical cases [12,13].

Amongst dogs, CTVT is transmitted through physical contact with viable cancer cells, usually during coitus, licking, sniffing or parturition [1,9,14]. The condition is also transmissible to wildlife: foxes, coyotes, jackals, wolves, and even humans [14,15].

Effective control of CTVT involves critical action plans, directed at eliminating CTVT in dogs, especially in enzootic areas. Vincristine has proven to be an effective chemotherapeutic agent in the treatment of such cases. However, adverse reactions associated with vincristine usage are obnoxious. Hence, it is pertinent to explore how the associated adverse reactions of vincristine usage can be mitigated. Undoubtedly, many treatment approaches are adopted worldwide; this report presents a different approach to vincristine usage: a halved-dosing-biweekly regimen, which can be adopted to help achieve therapeutic goals safely in the management of CTVT in dogs.

Case description

A 14.0 Kg 6-year-old intact male dog was referred to the University of Ghana Small Animal Teaching Hospital (SATH-UG) with a four-month-long history of indolent skin ulcers and a mass at the perianal area. About 7 weeks before observing external lesions, the client had noticed intermittent bloody preputial discharges. The client history revealed a poor response to antibiotic therapy, and wound dressing. The patient was the only pet at home: he sneaked out occasionally and returned few days afterwards, hence, did not preclude contacts with other dogs.

The dog appeared bright, alert and responsive. The dog variably sized pliant lumps in skin; nine (9) in number, approximately 20 mm x 10 mm x 10 mm in sizes, with the overlying skin of two lumps denuded (**Figure 3**). An actively bleeding, walnut-shaped, perianal granulomatoid growth was also found 5 mm away from the ventral anal orifice and 25 mm in diameter (**Figure 1**). Granulomatoid masses were on penis as well; one at the tip of glans penis (bean-sized) (**Figure 2**): and the other, about the size of a ping-pong ball on the bulbus penis. Serosanguinous discharges exuded from the preputial cavity. The inguinal lymph nodes were enlarged and firm, which implied the possibility of metastases.

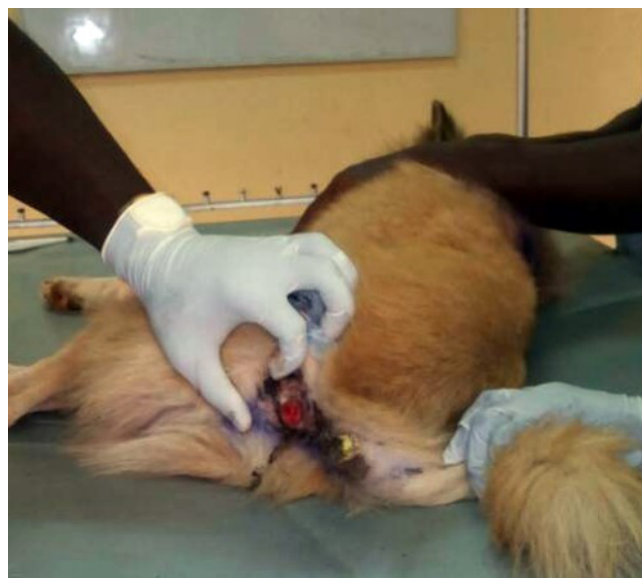

Figure 1: Dog on right lateral recumbence; cauliflower-like granulomatoid growth below anal orifice.

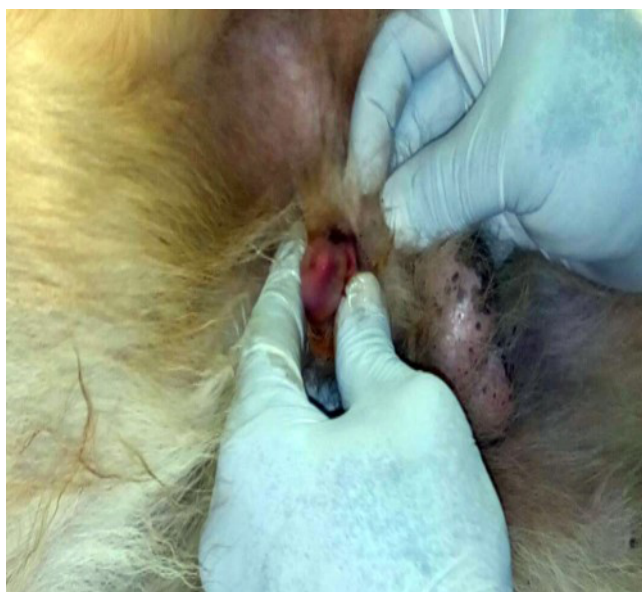


Figure 2: Bean-sized granulomatoid soft lesion on glans penis; lesion on bulbus glandis (not visible here) made extrusion of the crus penis nearly impossible.

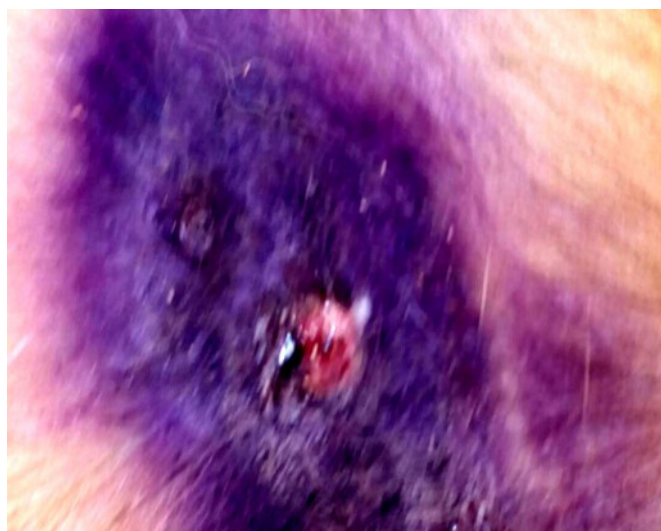

Figure 3: Ulcerated lumpy lesions at the dorsal cervico-thoracic region of torso. Bluish discoloration is as a result of oxytetracycline spray applied by dog owner for topical control of secondary bacterial infection.

A case such as this requires a clinician to identify if what is being observed has/or does not have an underlying infectious causation. This helps to avoid inappropriate use of antimicrobials. The gross appearance of lesions indicated to us also certain infectious and/or non-infectious causes in dogs. Bacterial causes of such epithelial and skin lumps are not farfetched, especially in pyodermas. Parasitic conditions like myiasis can cause subcutaneous lumps, however, usually without such a chronic anamnesis. Candidiasis can cause epithelial and skin lesions, often without such growths on the genitals. Mycetomas can also cause tumor-like lumps under the skin; likewise, with blastomycosis, but rarely causes skin nodules. Lesions associated with blastomycosis commonly begin in the lungs with subsequent cardiovascular dissemination to other organs [16]. This dog had been on an unknown and unsuccessful antibiotic regimen before referral, and this could complicate treatment options as well as the overall condition, especially if the patient had developed some degree of antimicrobial resistance. From the complete blood count of this patient (**Table 1**), a non-infectious cause became more likely: as observed in mast cell tumors, round cell tumors, squamous cell carcinoma, transmissible venereal tumors, plasmacytoma and histiocytoma.

The unresponsiveness to antibiotic therapy and wound dressing as well as the persistence of lesions for at least four months, macroscopic appearance of the lesions and their locations were suggestive of neoplasm. CTVT is enzootic in Ghana, so with the patient's history of occasional community roaming and possible contact with other dogs, it was considered a tentative diagnosis. Based on these considerations, the client was advised to avoid contact between patient and other dogs to prevent possible transmission. Considering the zoonotic potential of CTVT, the owner was also advised to observe certain hygiene precautions; frequent handwashing whilst avoiding direct contact with lesions as much as possible.

Diagnostic investigation

Fine needle aspirates from intact subcuticular lumps and direct slide impressions from open skin lesions were obtained; using Giemsa stain, cytology was performed on samples. To evaluate the overall health of patient, blood sample was collected and a full blood count was run. (results shown in **Table 1**).

Table 1: Full blood count of patient (dog).

BLOOD CELL TYPES/PARAMETERS	RESULT	RANGE	UNIT
WBC	14.54	6.00 – 17.00	10 ⁹ /L
Lymphocyte	0.52	0.83 – 4.69	10 ⁹ /L
Monocyte	1.64	0.14 – 1.97	10 ⁹ /L
Neutrophil	11.88	3.62 – 11.32	10 ⁹ /L
Eosinophil	0.45	0.04 – 1.56	10 ⁹ /L
Basophil	0.05	0.00 – 0.12	10 ⁹ /L
PLT	161.00	117.00 – 460.00	10 ⁹ /L
RBC	5.84	5.10 – 8.50	10 ¹² /L
HGB	13.30	11.00 – 19.00	g/dL
HCT	33.60	36.00 – 56.00	%
MCV	57.60	62.00 – 78.00	fL
MCH	22.70	21.00 – 28.00	Pg
MCHC	40.00	30.00 – 38.00	g/dL
RDW	15.90	14.50 – 19.20	%

WBC: White Blood Cell; PLT: Platelet; RBC: Red Blood Cell; HGB: Haemoglobin; HCT: Hematocrit; MCV: Mean Corpuscular Volume; MCH: Mean Corpuscular Hemoglobin; MCHC: Mean Corpuscular Hemoglobin Concentration; RDW: Red Cell Distribution Width.

Full blood count depicted: i) microcytic normochromic anemia characterized by low HCT and low MCV; ii) and an increased hemoglobin concentration per volume of an erythrocyte (high MCHC). These changes indicated chronic blood loss, which vividly occurred through the bleeding granulomas; however, in this case, patient had an atypically high hemoglobin concentration per erythrocyte (high MCHC). White blood cell counts revealed a neutrophilia and lymphopenia, fairly similar to a stress response or long term glucocorticoid therapy; a typical stress response however has in addition eosinopenia and monocytosis (**Table 1**).

Cytological examination of slide impressions and fine needle aspirate revealed a fairly uniform population of isolated round to oval, large, mesenchymal neoplastic cells with faintly basophilic cytoplasm, indistinct cell borders, increased nuclear-to-cytoplasmic ratio, variable nuclear sizes (anisokaryosis), round to oval nuclei, coarse deeply basophilic chromatin pattern and small discrete perinuclear cytoplasmic vacuoles that were pathognomonic for transmissible venereal tumor; few mitotic figures and anisocytosis were present (Figure 4).

Overall, based on history, physical examination and cytology findings, the condition was definitively diagnosed as metastasized CTVT. Since the client initially observed intermittent bloody preputial discharges before the appearance of all external lesions, it is very likely that the primary mode of contracting the disease was venereal, followed by metastases to the inguinal lymph nodes and subcutis: the perianal mass, however, could have developed after transplantation of tumor cells via licking of the genitals.

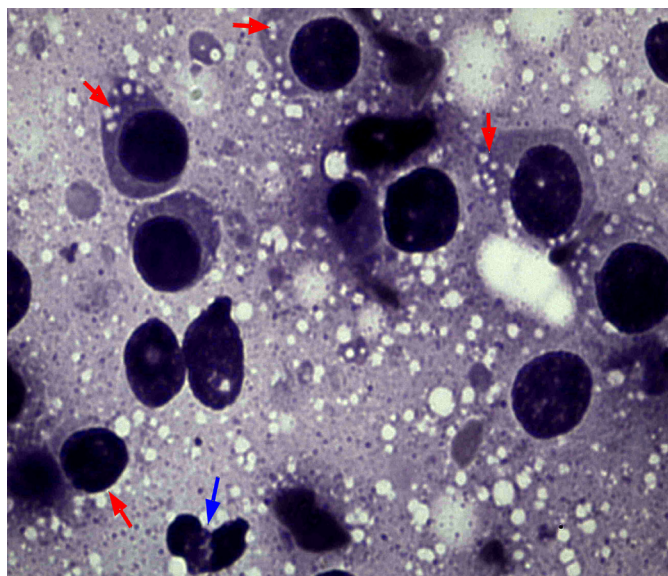


Figure 4: Representative cytology image of lesions. Round to oval isolated mesenchymal neoplastic cells, with discrete perinuclear cytoplasmic vacuoles (red arrows); mitotic figure at the lower border (blue arrow). (Giemsa stain, x20)

Treatment

The therapeutic plan involved chemotherapy with slow intravenous (IV) vincristine sulphate (Unicristin, United Biotech Pvt Ltd., New Delhi, India) injection at a dose of 0.6 mg/m² of tumor size, once every week, till two weeks after total macroscopic remission of granulomas. The first dose was administered based on these considerations. Two days later, the patient was presented with complaints of hyporexia, emesis (~7% dehydrated), lethargy, and depression; patient had a 2.8 Kg drop in weight, from 14.0 Kg to 11.2 Kg. The dog was admitted for critical assessment and monitoring, and also to manage the reported adverse reactions. To rehydrate this patient, daily intravenous administration of 20 ml/hour Ringer's Lactate and 13 ml/hour 5% dextrose IV (Intravenous Infusions Ltd., Effiduase-Koforidua, Ghana) was done. Promethazine (TROGE Medicals Ltd., Hamburg, Germany) was administered at a dose of 0.3 mg/Kg of body weight, three times daily to reduce vomiting. The dog was handfed with a bland diet till he begun eating and drinking by himself; he was discharged 3 days later after gaining a significant level of physical activity with no vomiting.

As a result of the initial adverse reactions to vincristine sulphate, the therapeutic plan was altered by increasing the dosing interval from one week to two whilst halving the previously administered amount. thus, a tapered dose with an extended inter-dosing interval, in an attempt to abate observed adverse reactions.

On the next visit, that is two weeks after initial dose, 5 out of the previous 9 subcuticular lumps were palpable; sizes of subcuticular granulomas had reduced to about 8 mm x 5 mm x 7 mm. The perianal lesion had shrunken to a third of its previous size with no active bleeding. The glans penial granuloma had regressed completely. The granuloma on the bulbus glandis had reduced to a third of the initial size; however, inguinal lymph nodes were firm with no discernible reduction in size. On this occasion, half of the initial dose of vincristine sulphate was administered; that is, of initial tumor surface area. No adverse reactions were reported following this second dose.

On the third visit, all the genital, perianal, and subcuticular granulomas had regressed completely (**Figures 5 A, B, and C**). Inguinal lymph nodes felt turgid and had attained normal sizes. Being impressed with the response to this dose modification, the next dose (0.15 mg/m² of initial tumor surface area) was administered and was determined to be the final one.

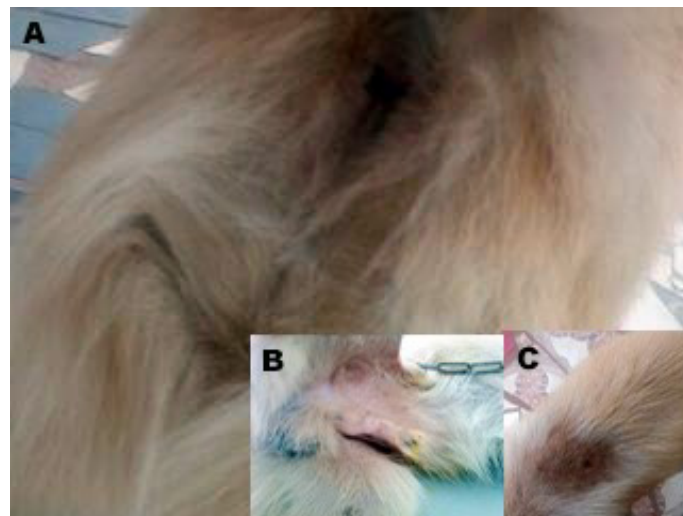


Figure 5: 6 weeks after chemotherapy. A) Perianal granuloma completely regressed. B) Complete remission of granuloma on bulbus penis markedly reduced alongside that of inguinal lymph nodes; Bean-sized granuloma regressed completely as well. C) Ulcerated lumps at dorsum completely healed. No more lumps in subcutis.

Outcome and follow-up

Review of patient after the final dose of vincristine was initially in the form of biweekly hospital visits for 6 weeks when complete remission was realized, followed by quarterly phone calls to client. During patient's recheck exams, resurgence of granulomas did not occur. Patient's care was transferred back to referring veterinarian.

At the time of writing this report, approximately two years after complete remission, there has been no recurrence of tumors in the patient.

Discussion

CTVT is common, especially in areas having stray dog populations with uncontrolled mating activity. It is the most prevalent tumor of the external genitalia in tropical and subtropical regions of the world [17]. CTVT occurrence patterns depict no sex predisposition [18].

Previous studies have described CTVT as highly friable, blood-oozing cauliflower-like tumor, usually located on the genitals [19,20]. In male dogs, tumors usually occur at the caudal part of the crus penis, bulbus glandis, pars longa glandis and seldomly on the prepuce; and similarly inside the vagina and at the vaginal orifice or vestibulo-vaginal junction in bitches [3]. In some affected dogs, the tumors may metastasize via lymphatics into regional lymph nodes, viscera, eyes [3,17,21], oral, nasal, and conjunctival mucosae, skin [22,23] and even the brain [24]. Metastases usually occur in puppies and immunocompromised dogs [25]. The macroscopic description of lesions in this report, in terms of physical appearance and location, is common to CTVT. Moreover, microscopic descriptions of high index mitotic figures, cellular vacuolations, anisocytosis, and anisokaryosis [18] which are typical of CTVT cells corroborate our findings in

this present case (**Figure 4**).

Rungsipat et al., 2019 [20] reported that, older dogs are more likely to develop extragenital forms of CTVT. In this case, the dog being 6 years old (middle-aged), as well as the locations of tumors (indicative of metastases) agrees with their observations. Full blood count for this patient (**Table 1**) depicted: i) chronic blood loss, which confirms the client's observation of persistent bloody preputial discharges for several months; ii) an atypical stress response or long term glucocorticoid therapy.

Vincristine is the drug of choice in treating CTVT and has been in use for decades [26,27]. Treatment regimens using vincristine vary based on the clinician's assessment of tumor sizes (surface area), level of metastasis, and whether or not if combined therapy with other drugs or treatment options, such as surgical excision, will be adopted. Time to achieve full clinical remission is dependent on tumor size(s), age of the patient, and season of the year; however, sex, weight, and breed are of no predictive significance regarding the remission time for CTVT [28]. In this case, we could not ascertain the roles the aforementioned factors played in our patient's response to the vincristine dosing regimen. Vincristine is administered once weekly at 0.025 mg/Kg, or 0.75 mg/m², and most patients achieve complete remission by the fourth or fifth week of treatment [19,20]. In managing this case, chemotherapy was adopted because tumor cells had metastasized; nonetheless, we have adopted several treatment options in several cases, often using the weight of animals in calculating dosages rather than tumor sizes, with varying outcomes.

After the initial dose of vincristine (0.6 mg/m²), this patient suffered severe adverse reactions. This led to our decision to halve the doses, and extend the dosing interval from one to two weeks, for subsequent visits to the clinic; and this helped mitigate adverse reactions. This observation is significant since such adverse reactions, in some cases, could produce fatal outcomes [1,5].

Although the protocol adopted in this report differs from the recommended [29], total remission was still achieved in this Ghanaian indigenous breed; however, the possibility of this regimen producing differing responses in other breeds of dogs at various ages can be argued and will require additional investigations. Of note, the potential risks due to adverse reactions associated with vincristine usage emphasize the need for novel approaches for improved and efficient therapeutic outcomes [6,7]. This need substantiates the findings of this report, rendering it significant and considerable for further investigation and possible adoption.

Learning points

Vincristine therapy for managing CTVT in dogs can be enhanced to achieve total remission of tumors safely by: i) starting at an initial dose of 0.6 mg/m², and tapering each subsequent dose to half of the previous; ii) whilst increasing dosing interval from one week to two.

This reduces the severity of associated adverse reactions as regards vincristine usage, and can also be used to treat successfully metastasized forms of CTVT in dogs.

Acknowledgement

The authors express their gratitude to the co-ordinator, as well as the technical staff, of the Small Animal Teaching Hos-

pital, School of Veterinary Medicine, University of Ghana; and also to the client for prompt feedback regarding the patient's response throughout the treatment and follow-up period.

References

1. Tella MA, Ajala OO, Taiwo VO. Complete regression of transmissible venereal tumor (TVT) in Nigerian mongrel dogs with vincristine sulfate chemotherapy, *African Journal of Biological and Medical Research*. 2004; 7: 133-138.
2. Ganguly B, Das U, Das AK. Canine transmissible venereal tumour: a review, John Wiley & Sons Ltd, *Veterinary and Comparative Oncology*. 2013 ; 14: 1-12.
3. Nak D, Nak Y, Cangul IT, Tuna BA. Clinico-pathological study on the effect of vincristine on transmissible venereal tumour in dogs. *J Vet Med. A Physiol Pathol Clin Med*. 2005; 52: 366-370.
4. Gobello C, Corrada Y. Effects of vincristine treatment on semen quality in a dog with a TVT, *Journal of Small Animal Practice*. 2002; 43: 416-417.
5. Saratsis PH, Ypsilantis P, Tselkas K. Semen quality during vincristine treatment in dogs with transmissible venereal tumor, *Theorogenology*. 2000; 53: 1185-1192.
6. Stettner N, Brenner O, Eilam R, Harmelin A. Pegylated liposomal doxorubicin as a chemotherapeutic agent for treatment of canine transmissible venereal tumor in murine models, *Journal of Veterinary Medical Science*. 2005; 67: 1133-1139.
7. Vilensky J, Koudinova NV, Harmelin A, Scherz A, Salomon A. Vascular-targeted photodynamic therapy (VTP) of a canine-transmissible venereal tumour in a murine model with Pd-bacteriopheophorbide (WST09), *Veterinary and Comparative Oncology*. 2005; 3: 182-193.
8. Cohen D. The Canine Transmissible Venereal Tumor: a Unique Result of Tumor Progression, *Advanced Cancer Research*. 1985; 43: 75-112.
9. Goldschmidt MH, Hendrick MJ. Tumors of the skin and soft tissues, Tumors in domestic animals, ed. DJ Meuten, 4th Ed., Iowa State Press, Ames, IA, 2002: 45-118.
10. Boscós CM, Ververidis HN. Canine TVT – Clinical Findings, Diagnosis and Treatment. Proceedings of the 29th World Congress of the World Small Animal Veterinary Association. 2004.
11. Das U, Das AK. Review of canine transmissible venereal sarcoma. *Veterinary Research Communications*. 2000; 24: 545-556.
12. Rust JH. Transmissible lymphosarcoma in the dog. *Journal of the American Veterinary Medical Association* 1949; 114: 10-14.
13. Moulton JE. *Tumours of Domestic Animals*. 3rd edn., Berkeley, University of California Press. 1990: 498-502.
14. Transmissible Cancer Group, *Canine Transmissible Venereal Tumor*, University of Cambridge, 2019.
15. Gross TL, Ihrke PJ, Walder EJ, Affolter VK. *Skin Diseases of the Dog and Cat* 2nd ed., Oxford, UK: Blackwell Publishing, 2005; 800-803.
16. Merck's Veterinary Online Manual.
17. Purohit G. Canine Transmissible Venereal Tumor: A Review, *The Internet Journal of Veterinary Medicine*, 2008; 6: 5692.
18. Smith GB, Washbourn JB, Infective sarcomata in dogs, *British Medical Journal*, 1998; 2: 1346-1347.
19. Hiblu MA, Khabuli NM, Gaja AO. Canine transmissible venere-

- al tumor: First report of three clinical cases from Tripoli, Libya Open Vet J. 2019; 9: 103-105.
20. Setthawongsin C, Teewasutrakul P, Tangkawattana S, Techangamsuwan S, Rungsipipat A. Conventional-Vincristine Sulfate vs. Modified Protocol of Vincristine Sulfate and L-Asparaginase in Canine Transmissible Venereal Tumor Front. Vet Sci. 2019.
 21. Kegler K, Habierski A, Hahn K. Vaginal canine transmissible venereal tumour associated with intra-tumoural *Leishmania* spp. amastigotes in an asymptomatic female dog. Journal of Comparative Pathology, 2013.
 22. Foster RA. Male reproductive system, Pathologic Basis of Veterinary Disease, 5th Ed., eds. McGavin MD, Zachary JF, Mosby Elsevier, 2012: 1152.
 23. Mozos E, Méndez ACJ, Martín J, Pérez J. Immunohistochemical Characterization of Canine Transmissible Venereal Tumor, Veterinary Pathology. 1996; 33: 257-263.
 24. Ferreira J, Jaggy A, Varejao AP. Brain and ocular metastases from a transmissible venereal tumour in a dog, Journal of Small Animal Practice. 2000; 41: 165-168.
 25. Mukaratirwa S, Gruys E. Canine transmissible venereal tumour: Cytogenetic origin, immunophenotype, and immunobiology. A review, The Veterinary Quarterly. 2003; 25: 101-111.
 26. Calvet CA, Leifer CE, McEwen EG. Vincristine for the treatment of Transmissible Venereal Tumor in the dog. J Amer Vet Med Assoc. 1982; 181: 163-164.
 27. Amber EI, Henderson RA, Adeyanju JB, Gyang EO. Single-drug chemotherapy of canine transmissible venereal tumour with cyclophosphamide, methotrexate, or vincristine, Journal of Veterinary Internal Medicine, 1990; 4: 144-147.
 28. Scarpelli KC, Valladao ML, Metze K. Predictive factors for the regression of canine transmissible venereal tumor during vincristine therapy. Vet J. 2008, 45: 243-256.
 29. Das U, Das AK, Das DK, Das BB. Clinical report on the efficacy of chemotherapy in canine transmissible venereal sarcoma, The Indian Veterinary Journal. 1991b; 68: 249- 252.