



# Negative Pressure Wound Therapy with a Syringe Technique for Subcutaneous Hematoma in a Heifer

Takeshi Tsuka\*; Yoshiharu Okamoto; Tomohiro Osaki; Kazuo Azuma; Masamichi Yamashita; Takao Amaha; Norihiko Ito; Yusuke Murahata; Tomohiro Imagawa

Joint Department of Veterinary Medicine, Faculty of Agriculture, Tottori University, 4-101 Koyama-Minami, Tottori-city, Tottori, Japan.

**\*Corresponding Author(s): Takeshi Tsuka**

Veterinary Diagnostic Imaging, Joint Department of Veterinary Medicine, Faculty of Agriculture, Tottori University, 4-101, Koyama-Minami, Tottori, Japan.  
 Tel: +81-857-31-5435;  
 Email: tsuka@tottori-u.ac.jp

**Abstract**

**Objective:** The objective of this study was (1) to determine the relationship between syringe volume and pressure generated on evacuation and (2) to report the use of Negative Pressure Wound Therapy (NPWT) with a syringe technique to treat a large subcutaneous hematoma of the trunk in a 2-year-old female Holstein heifer.

**Methods:** (1) One, two, or three syringes of different volumes were attached to a manometer. Syringes were attached to the manometer via connection tubes of different volumes. (2) NPWT using five 100-mL syringes was employed to maintain evacuation of the hematoma cavity in the cow following surgical drainage, with syringes emptied and reset twice daily.

**Results:** (1) The pressures generated from total volumes of two or three syringes were plotted along a regression equation to determine the relationship between negative pressure and the volume of one syringe. Decreases in negative pressure generated from the same volume of syringes were dependent on the inner volume of the connection tubes. (2) NPWT was initially insufficient to keep the large hematoma cavity drained; however, by the fourth day this treatment regime was able to adequately maintain evacuation. All drains were removed on day 11.

**Conclusions:** Substantial negative pressure can be generated by the use of syringes in NPWT, and this technique can be successfully used for fluid evacuation from cavities. NPWT with a syringe technique can be utilized to facilitate the healing of wound cavities in ambulatory large animals.

Received: Nov 01, 2020

Accepted: Jan 20, 2021

Published Online: Jan 25, 2021

Journal: Journal of Veterinary Medicine and Animal Sciences

Publisher: MedDocs Publishers LLC

Online edition: <http://meddocsonline.org/>

Copyright: © Tsuka T (2021). *This Article is distributed under the terms of Creative Commons Attribution 4.0 International License*

**Keywords:** Heifer; Negative pressure wound therapy; Subcutaneous hematoma; Syringe technique.



## Introduction

Negative Pressure Wound Therapy (NPWT) is a technique in which a device provides negative pressure to the external end of an evacuation tube [1] and is based on evidence that negative pressure increases skin perfusion [2]. In 1997, two studies reported that the greatest increase in blood flow to a wound site occurred at a negative pressure of -125 mmHg, which is now the pressure of choice in human medicine [3,4]. Increased blood flow results in improved tissue perfusion, which is believed to allow the delivery of nutrients, removal of local edema, and reduction of bacterial wound colonization rates [1,5]. In addition, negative pressure forces enhance the formation of granulation tissue [5]. NPWT is commonly achieved using a commercial Vacuum-Assisted Closure (VAC) system, comprising a polyurethane foam dressing, evacuation tube, waterproof adhesive barrier drape, and a vacuum-assisted device [5,6]. The use of a VAC system can increase healing efficacy in various wound types, both acute (e.g., trauma, burns, hematoma) and chronic (e.g., pressure sores, ulcers, complications), and promote earlier adhesion of skin grafts [6,7]. During the early period of technical developments of NPWT, syringes have been used to generate negative pressure [8,9]. Syringe pressure irrigation can also contribute to a reduction in postoperative wound infections when applied to surgical wounds, e.g., after an appendectomy [10].

VAC system-assisted NPWT has been used to facilitate the healing of open wounds, surgical wounds, infected olecranon bursitis involving a concurrently open wound, burn injuries, and skin grafts. It has been applied in various animals, including small animals such as cats and dogs [11,12], horses [13-15], and wild animals (e.g., tiger, tortoise, and rhinoceros) [16-18]. In addition, this technique has been used in experimental animals [2,3,19,20]. However, in large animal practice there can be difficulty in applying a VAC system, associated with their cumbersome design [13,14]. Thus, a classic vacuum system using a syringe has generally been used as a source of negative pressure for NPWT in canine [21] and bovine cases [22,23]. However, the methodology of classic NPWT has not been discussed in detail in relation to bovine practice. The purpose of this study was (1) to investigate the magnitude of negative pressure achievable using various syringe volumes and (2) to discuss the therapeutic efficacy of NPWT with a syringe technique for a large subcutaneous hematoma in a heifer.

## Materials and methods

### Assessment of negative pressure generated by syringes

The negative pressure generated by syringes of various volumes (2.5, 5, 10, 20, 50, and 100 mL) was measured using a manometer (Model PG-100; Copal Electronics Corporation, Japan).

(1) Syringes were connected via a three-way stopcock and a 35-cm-long tube to the manometer, using a connection tube (outer diameter, 6 mm; inner diameter, 4 mm, SF-GT1810; Terumo Corporation, Japan). The pressure generated by one, two, or three syringes of the same total volume was measured by connecting the second syringe to the other arm of the stopcock; or, for three syringes, connecting a second stopcock to this port and attaching two syringes to the second stopcock (Figure 1A). Additional volumes from each volume of one, two, or three syringes were used for statistical analyses.

(2) A 2.5, 5, 10, 20, or 50 mL syringe was connected to the manometer, employing various lengths of tubing (25, 50, or 100 cm) using tube type A (outer diameter, 5 mm; inner diameter,

2.5 mm, Phycon; Fuji System, Japan) or tube type B (outer diameter, 6 mm; inner diameter, 3.5 mm, Phycon; Fuji System). The volume of the inner space of the connection tube was calculated using the following formula:  $y = (\text{tube radius})^2 \times 3.14 \times (\text{tube length})$ .

The relationship between syringe volume and the negative pressure generated was determined by regression analysis.

### Case presentation

A 2-year-old pregnant Holstein heifer was admitted with a subcutaneous mass on the right side of the trunk (Figures 2A & 3A). The mass (70 cm dorsoventral dimension, 50 cm wide) was fluctuant, more distended ventrally, and had been enlarging for 3 months. The oral mucous membrane was macroscopically pale. The swelling had a distinct capsule and contained fluid with echogenic mass, when examined by an ultrasound machine (HONDA HS-101V; HONDA Electronics, Tokyo, Japan) with a 5.0-MHz linear transducer. A hematological examination revealed an anemic states, with a red blood cell count of  $290 \times 10^4$  cells/ $\mu\text{L}$  ( $853 \pm 101 \times 10^4$  cells/ $\mu\text{L}$ ), a hemoglobin level of 4.9 g/dL ( $9.8 \pm 1.3$  g/dL), and a hematocrit level of 13.2% ( $30 \pm 5\%$ ) [24].

Surgery was performed in a standing position and with dorso-lumbar epidural anesthesia (2% xylazine [0.025 mg/kg] combined with 2% lidocaine [0.1 mg/kg]). The mass was explored through a 30 cm-long dorsal incision in the swollen region. The capsule had a wall of approximately 3 to 5 cm thickness and contained odorless, serosanguineous fluid (approximately 50 L). The fluid was removed using an aspirator machine (maximum pressure, -600 mmHg; Blue Cross, Tokyo, Japan), and several fist-sized clots were removed manually. The capsule occupied most of the right abdominal wall and appeared to extend to the peritoneum (Figure 4A). The inner wall of the capsule was granular in texture and appeared brittle. Surgical removal of the mass was not possible, so we decided to use active drainage with a closed suction system.

Five plastic tubes (tube type A) were used, each with one end fenestrated with multiple side ports to facilitate fluid evacuation. Each tube was inserted through a dorsal skin incision, tunneled subcutaneously before entry through the capsule wall dorsally, and positioned on the floor of the cavity (Figure 4B). The length of the drainage tubes was 100 cm (inner volume: 4.9 cm<sup>3</sup>). The wall of the mass was closed with absorbable suture (Maxon 2-0; Davis and Geck INC., USA). After wound closure, each tube was secured at the skin incision using a Chinese finger trap suture pattern, and a 100 mL syringe was attached to each tube via a three-way stopcock. The syringes were secured to the body by skin sutures near the transverse processes of the lumbar vertebrae, dorsal to the surgical wound (Figure 2B). Each syringe was evacuated to its maximum volume once the stopcock was closed. The shaft of the plunger was secured with two steel pins passed through the barrel and plunger (Figure 4C), then the stopcock was opened to connect the syringe and cavity.

## Results

### Assessment of negative pressure generated by the syringes

(1) The negative pressures generated by a single 2.5, 5, 10, 20, 50, and 100 mL syringe via a tube of 4.40 cm<sup>3</sup> inner volume were -247.5, -386.3, -510.0, -607.5, -686.3, and -712.5 mmHg, respectively (Figure 1A). The relationship between total syringe volume and the pressure generated was plotted and could be described by the regression equation  $y = -113.3 \times \ln(x) - 232.7$

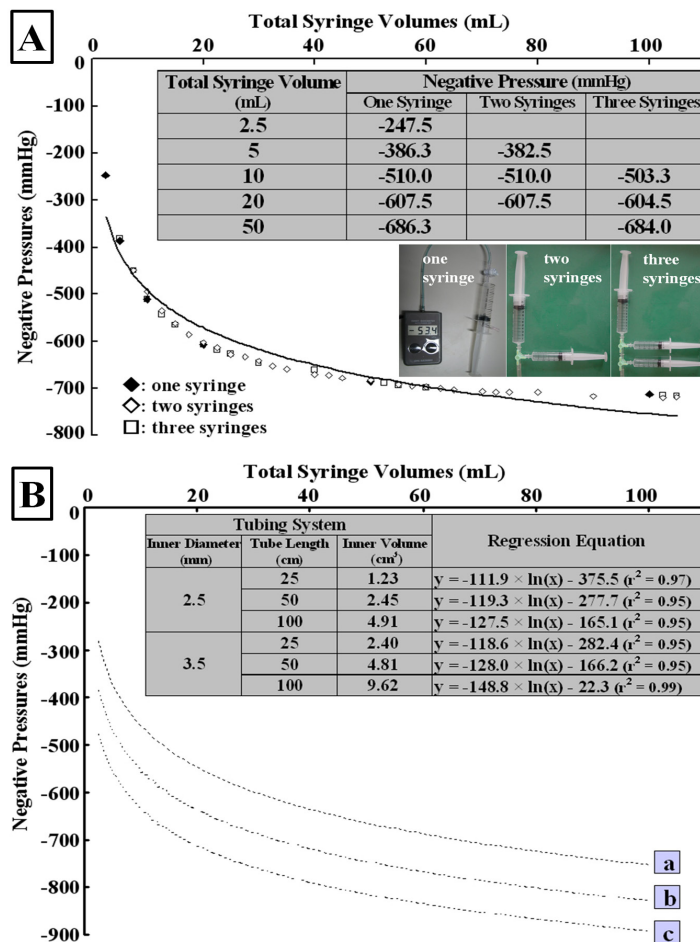
( $r^2 = 0.94$ ), where  $y$  represents the negative pressure generated and  $x$  is the total volume of the attached syringes (Figure 1A).

(2) The regression equations of the relationship between vacuum pressure and syringe volume via 25, 50, or 100 cm lengths of tube type A (inner volume: 1.23, 2.45, or 4.91 cm<sup>3</sup>, respectively): were  $y = -111.9 \times \ln(x) - 375.5$  ( $r^2 = 0.97$ ),  $y = -119.3 \times \ln(x) - 277.7$  ( $r^2 = 0.95$ ), and  $y = -127.5 \times \ln(x) - 165.1$  ( $r^2 = 0.95$ ), respectively (Figure 1B). Decreased levels of negative pressure generated by the same volume of syringes were significantly associated with increases in the inner volume of the connection tube. Plots of negative pressure generated by the syringe system via tubes of similar inner volume (e.g., 100 cm length of tube type A vs. 50 cm length of tube type B) could be described by similar regression equations.

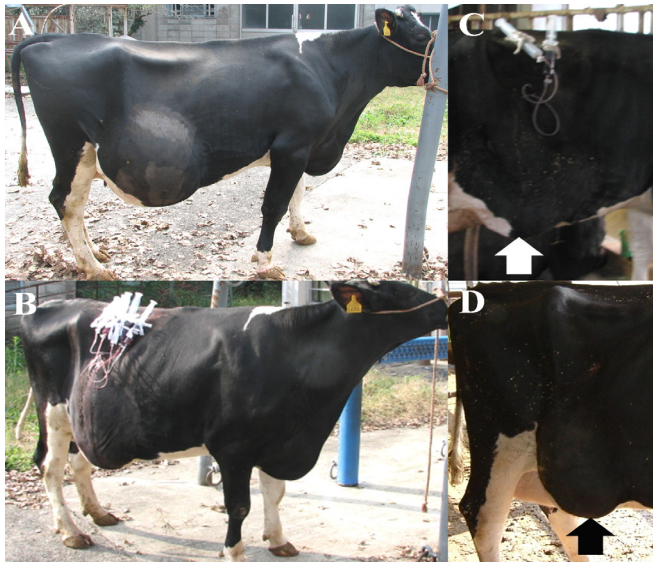**Case presentation**

NPWT using five syringes continued to be performed until 8 days after surgery (Day 8). According to the equation of the relationship between vacuum pressure and syringe volume, the estimated total negative pressure for the five syringes was -957 mmHg. Except for topical use of dry cow intramammary antibiotics (Kanamycin; Meiji Seika, Tokyo, Japan) for 4 days, no medications were administered. Syringes were reset twice daily to maintain negative pressure within the cavity. On Day 1, 615 mL of fluid was aspirated; however, fluid was still palpable within the cavity and was thus evacuated (1,100 mL) using an aspirator attached to one stopcock (Figure 5). Daily volumes aspirated


exceeded 500 mL until Day 4 and then gradually decreased. On Day 2, an aspirator was used to remove residual volume, and on Day 3 evacuation was performed manually using a syringe. Also on Day 3, cytology of the evacuated fluid revealed large numbers of erythrocytes and leukocytes were present, but no bacteria were evident. Drainage tubes were removed based on the reduction of the swelling size. Three were removed on Days 9-10, when no fluid content was palpable within the surgical wound; the surgical thread was also removed (Figures 2C & 3B). Two were removed on Day 11, when the surgical wound was slightly swollen and firm (Figure 3C). The average interval between aspiration recharges was 12.1 hours (range: 5.5-18.5 hours). The animal showed no signs of discomfort associated with the presence of the syringes attached to its body. In addition, there was no slippage of syringes during the 11 days of treatment. Bacterial examination of the fluid taken during surgery revealed no presence of bacteria. One month after treatment, the surgical wound had not re-enlarged and was palpable as firm, although slight swelling remained, which was possibly part of the capsular mass that remained under the skin (Figure 2D). The animal has grown normally without re-accumulation of exudates, and has been delivered of two calves.



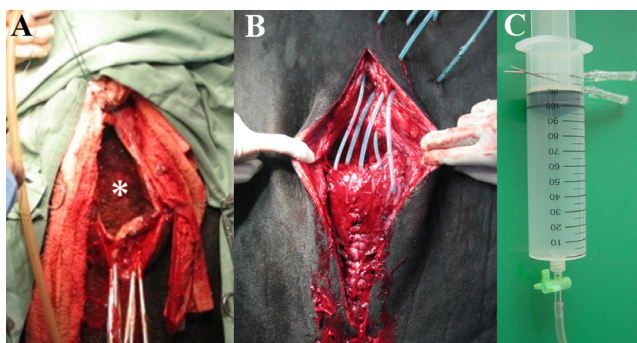
**Figure 1:** (A) Regression line and values for negative pressure generated by different volume syringes; (B) regression equations of the relationship between vacuum pressures and syringe volumes using 25, 50 or 100-cm lengths of tube A or tube B. Broken lines (a-c) show regression equations of data using 100, 50 or 25-cm lengths of tube A, respectively.



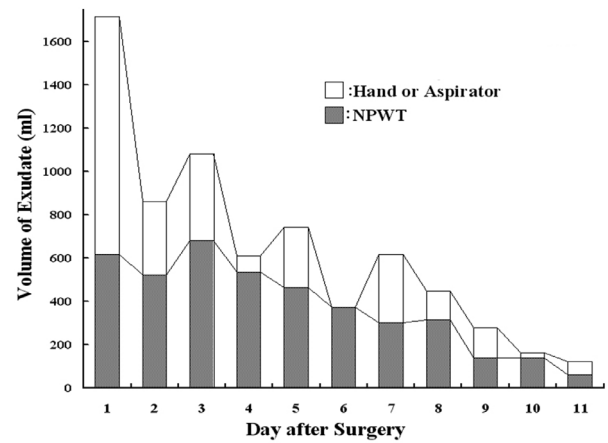
**Figure 2:** Lateral views of subcutaneous hematoma on the day of admission (A); one day after surgery (Day 1) (B); Day 9 (C); and Day 30 (D). Arrows show the reduction in the lesion.



**Figure 3:** Rear views of subcutaneous hematoma on the day of admission (A); 9 days after surgery (Day 9) (B); and Day 11 (C). Arrows show the remaining slight swelling in the lesion.



**Figure 4:** Intraoperative views of the incised capsular hematoma (asterisk) after removal of exudates (A); the sutured mass after insertion of five tubes into the mass lumen (B). (C) A photograph showing a syringe in which the shaft of the plunger has been secured with two steel pins passed through the barrel and the plunger.



**Figure 5:** Record of suction volumes of exudates following surgery.

### Discussion & conclusions

Subcutaneous hematomas in cattle commonly occur following injury (e.g., butting wounds) and sometimes increase in size over time. With chronic hematomas, blood and serosanguineous fluid is contained within a pseudo-capsule of granulation and fibrous tissue, which includes capillaries that allow repeated exudation or bleeding [25]. Common treatment approaches include centesis or surgical removal of the exudate, partial or intact removal of the pseudo-capsule, suture closure of the cavity, or administration of styptics and antibiotics; however, these methods frequently result in complications and recurrence [25]. Suture closure of the hematoma is often ineffective because of the large size of the cavity, and exposed sutures may result in further inflammation and potentially infection [7].

The use of NPWT for treating hematoma is effective, since it can generate wound compressive forces and prevent the accumulation of exudate [7]. NPWT can apply mechanical stress to tissues, enhancing tissue growth and expansion [7]. In addition, the active removal of bacteria via drainage can promote healing in hematomas associated with surgical wound infections, decreasing colony levels to  $<10^5$  organisms per gram of tissue and minimizing the likelihood of wound infection [1,3,5,7]. This is essential for cavity closure because infection appears to prolong inflammation, disrupt normal clotting, inhibit angiogenesis, and create friable granulation tissue [26]. In humans, the use of commercial VAC system for hematoma decreases infection rates to 8% compared with 16% for hematoma treated by drainage and pressure dressing [7]. Various types of commercial VAC systems have been used to generate a vacuum force when performing NPWT for small animals (such as cats and dogs) [11,12], horses [13-15], and wild animals [16-18]. The duration of NPWT was reported to be 3 days in a rhinoceros case [18], 8 days in a feline case [11] and an average of 3 days (range: 1-22 days) in 93% of canine cases [12]. However, for three equine cases with infected olecranon bursitis, it took 11-22 days to finish NPWT [15]. These extended periods required for NPWT might have resulted from the large volumes of the lesions [15], similar to this case.

The syringe technique has been used to apply NPWT in both small animal practice [21] and bovine practice [22,23]. However, complications can occur when using the syringe technique for NPWT, as it generates a continuous vacuum force of large magnitude negative pressure. The optimal negative pressure for wound healing appears to be -125 mmHg, using an intermittent pressure cycle of 5 minutes suction followed by 2 minutes without suction [5]. Granulation tissue formation was delayed

at -500 mmHg compared with its formation at -125 mmHg [20], and microvascular blood flow was inhibited at -400 mmHg but increased at -125 mmHg [19].

For NPWT with a syringe technique, the choice of syringe size is dependent on the estimated volume of exudate in the mass cavity. In this case, an aspiration volume greater than 500 mL was deemed necessary to achieve sufficient lavage. However, the use of a 500 mL syringe generated a large negative pressure of -957 mmHg (18.5 psi), which exceeded the recommended irrigation pressures of 4 to 15 psi (207 to 775 mmHg) in guidelines set forth by the Agency for Health Care Policy and Research (AHCPR) [8]. According to the AHCPR guidelines, the maximum total syringe size that should have been applied in this case is 120 mL, generating -775 mmHg (15.0 psi) of negative pressure [8]. On the other hand, high pressures loads of 1290 to 3100 mmHg (25 to 60 psi) may be acceptable only once the syringe technique has been applied for wound lavage in small animal practice [21]. In addition, the critical level of negative pressure to induce tissue damage is estimated to more than 70 psi (3620 mmHg) [9,10]. The size and number of syringes applied for NPWT with a syringe technique should be based on the required amount of suction, volume of the lesion, and the size of the animal's body, as well as the magnitude of the generated negative pressure.

Commercial VAC devices may be more beneficial for the treatment of more pliable tissues (e.g., subcutaneous tissue, fat, and skin grafts), if such devices can be effectively used with intractable or mobile animals [13]. An ingenious alternative approach for animals where continuous restraint is not practical employs a vacuum pump suspended in the center of the stall and attached to the drain tubing by extension tubing [16]; however, even this approach may be difficult to maintain in the long-term [16]. Compared with the use of a VAC system, the greatest advantage of NPWT with a syringe technique is the portability of the system, because the syringes are attached to the animal's body and also because multiple drain tubes can be used. In addition, the technique is simple, inexpensive, and the materials are readily available in practice. In bovine practice, NPWT using a 20 mL syringe has previously been used for the wound closure after open reduction technique in hip luxation [22]. The NPWT with a syringe technique seems to be applicable to joint lavage in younger calves with septic arthritis (instead of through-and-through lavage) [27], and vacuum suction in the drainage of tarsal bursitis and the removal of pericardial effusions associated with traumatic or idiopathic hemorrhagic pericarditis in adult cows [28,29]. To further develop the NPWT with a syringe technique it will be necessary to create a guideline for this technique about the safety and critical levels of negative pressure, frequency in recharge of negative pressure, and volume of syringe relative to the lesion's size.

## References

- Shirakawa M, Isseroff RR. Topical negative pressure devices. Use for enhancement of healing chronic wounds. *Arch Dermatol*. 2005; 141: 1449-53.
- Dersch T, Morykwas M, Clark M, Argenta L. Effects of negative and positive pressure on skin oxygen tension and perfusion. *Wound Repair Regen*. 1994; 2: 64.
- Morykwas MJ, Argenta LC, Shelton-Brown EI, McGuirt W. Vacuum-assisted closure: A new method for wound control and treatment: animal studies and basic foundation. *Ann Plast Surg*. 1997; 38: 553-562.
- Argenta LC, Morykwas MJ. Vacuum-assisted closure: a new method for wound control and treatment: clinical experience. *Ann Plast Surg*. 1997; 38: 563-576.
- Mendonca DA, Papini R, Price PE. Negative-pressure wound therapy: a snapshot of the evidence. *Int Wound J*. 2006; 3: 261-271.
- Jones SM, Banwell PE, Shakespeare PG. Advances in wound healing: topical negative pressure therapy. *Postgrad Med J*. 2005; 81: 353-357.
- Stannard JP, Robinson JT, Anderson ER, McGwin G Jr, Volgas DA, et al. Negative pressure wound therapy to treat hematomas and surgical incisions following high-energy trauma. *J Trauma*. 2006; 60: 1301-1306.
- Luedtke-Hoffmann KA, Schafer DS. Pulsed lavage in wound cleansing. *Phys Ther*. 2000; 80: 292-300.
- Wheeler CB, Rodeheaver GT, Thacker JG, Edgerton MT, Edlich RF. Side-effects of high pressure irrigation. *Surg Gynecol Obstet*. 1976; 143: 775-778.
- Cervantes-Sánchez CR, Gutiérrez-Vega R, Vázquez-Carpizo JA, Clark P, Athié-Gutiérrez C. Syringe pressure irrigation of subdermic tissue after appendectomy to decrease the incidence of postoperative wound infection. *World J Surg*. 2000; 24: 38-41.
- Owen L, Hotston-Moore A, Holt P. Vacuum-assisted wound closure following urine-induced skin and thigh muscle necrosis in a cat. *Vet Comp Orthop Traumatol*. 2009; 22: 417-21.
- Pitt KA, Stanley BJ. Negative pressure wound therapy: experience in 45 dogs. *Vet Surg*. 2014; 43: 380-387.
- Gemeinhardt KD, Molnar JA. Vacuum-assisted closure for management of a traumatic neck wound in a horse. *Equine Vet Educ*. 2005; 17: 27-33.
- Kamus L, Rameau M, Theoret C. Feasibility of a disposable canister-free negative-pressure wound therapy (NPWT) device for treating open wounds in horses. *BMC Vet Res*. 2019; 78: 15.
- Elce YA, Ruzickova P, da Silveira EA, Laverty S. Use of negative pressure wound therapy in three horses with open, infected olecranon bursitis. *Equine Vet Educ*. 2020; 32: 12-17.
- Lafortune M, Fleming GJ, Wheeler JL, Göbel T, Mazingo DW. Wound management in a juvenile tiger (*Panthera tigris*) with vacuum-assisted closure (V.A.C. Therapy). *J Zoo Wildl Med*. 2007; 38: 341-344.
- Adkesson MJ, Travis EK, Weber MA, Kirby JP, Junge RE. Vacuum-assisted closure for treatment of a deep shell abscess and osteomyelitis in a tortoise. *J Am Vet Med Assoc*. 2007; 231: 1249-1254.
- Harrison TM, Stanley BJ, Sikarskie JG, Bohart G, Ames NK, et al. Surgical amputation of a digit and vacuum-assisted closure (V.A.C.) management in a case of osteomyelitis and wound care in an Eastern Black Rhinoceros (*Diceros bicornis michaeli*) *J Zoo Wildl Med*. 2011; 42: 317-321.
- Wackenfors A, Sjögren J, Gustafsson R, Algotsson L, Ingemansson R, et al. Effects of vacuum-assisted closure therapy on inguinal wound edge microvascular blood flow. *Wound Repair Regen*. 2004; 12: 600-606.
- Morykwas MJ, Faler BJ, Pearce DJ, Argenta LC. Effects of varying levels of subatmospheric pressure on the rate of granulation tissue formation in experimental wounds in swine. *Ann Plast Surg*. 2001; 47: 547-551.
- Waldron DR, Zimmerman-Pope N. 'Superficial skin wounds', in D. Slatter, ed. *Textbook of Small Animal Surgery*, Third edition:

---

Elsevier Science. 2003; 259-273.

22. Marchionatti E, Fecteau G, Desrochers A. Traumatic conditions of the coxofemoral joint: luxation, femoral head-neck fracture, acetabular fracture. *Vet Clin North Am Food Anim Pract.* 2014; 30: 247-264.
23. Hull BL. Fractures and luxations of the pelvis and proximal femur. *Vet Clin North Am Food Anim Pract.* 1996; 12: 47-58.
24. Morita Y, Sugiyama S, Tsuka T, Okamoto Y, Morita T, et al. Diagnostic efficacy of imaging and biopsy methods for peritoneal mesothelioma in a calf. *BMC Vet Res.* 2019; 15: 461.
25. Reid JD, Kommareddi S, Lankerani M, Park MC. Chronic expanding hematomas. A clinicopathologic entity. *J Am Med Assoc.* 1980; 244: 2441-2442.
26. Wysocki AB. Wound fluids and the pathogenesis of chronic wounds. *J Wound Ostomy Continence Nurs.* 1996; 23: 283-290.
27. Desrochers A, Francoz D. Clinical management of septic arthritis in cattle. *Vet Clin North Am Food Anim Pract.* 2014; 30: 177-203.
28. Mates N, Muste A, Oana L, Beteg FL, Ober C. Morphoclinical aspects in tarsal bursitis in cattle; surgical and medicamentous treatment. *Bull Univ Agric Sci Vet Med Cluj-Napoca Vet Med.* 2008; 65: 182-186.
29. Buczinski S. Cardiovascular ultrasonography in cattle. *Vet Clin North Am Food Anim Pract.* 2009; 25: 611-632.