



Improve Patient Care and Enhance Client Engagement with At-Home, Low-Level Laser Therapy

Joel Ehrenzweig^{1*}; James St. Clair²

¹Veterinary Health Research Centers, LLC, U.S.A.

²Meriden Animal Hospital, Meriden, CT, U.S.A.

***Corresponding Author(s): Joel Ehrenzweig**

Veterinary Health Research Centers, LLC, U.S.A.

Email: petvet@hotmail.com

Received: Jan 27, 2022

Accepted: Feb 21, 2022

Published Online: Feb 25, 2022

Journal: Journal of Veterinary Medicine and Animal Sciences

Publisher: MedDocs Publishers LLC

Online edition: <http://meddocsonline.org/>

Copyright: © Ehrenzweig J (2022). *This Article is distributed under the terms of Creative Commons Attribution 4.0 International License*

Abstract

The COVID-19 pandemic has had a profound impact on the veterinary profession. Practices have struggled to maintain high-quality veterinary care while safeguarding the health and welfare of staff, patients and clients. Reducing hours of operation and triaging appointments based on the severity of a medical problem has significantly decreased the availability of clinic visits for patients with chronic but non-life-threatening conditions, often irritating the most loyal clientele.

The primary aim of this multisite, prospective exploratory trial was to evaluate the efficacy of an in-home treatment protocol using a client-operated Class 1 hand-held laser device for the treatment of inflammatory conditions regularly seen in companion animal practice. A secondary aim of the study was to assess the interest level of clients in continued, albeit remote, care of their pets' medical conditions.

Nomenclature: In 1965 Paul McGuff successfully used a ruby laser to cure malignant tumors in rats [1]. Endre Messter failed in an attempt to replicate McGuff's cancer treatment, having used a much lower-powered laser. But he had observed that his rats exhibited increased hair growth and improved wound healing, concluding that low-level light could have beneficial applications in medicine [2].

As with any discovery, science was quick to put a name to this new finding, and the appellation 'Low-Level Laser Therapy' (LLLT) was coined. Those striving for precision nomenclature, however, argued that 'low-level' was a term without exactitude: *Precisely what constitutes a low-level?* It was decided that the action of 'photobiomodulation' (PBM)



Cite this article: Ehrenzweig J, Clair JS. Improve Patient Care and Enhance Client Engagement with At-Home, Low-Level Laser Therapy. J Vet Med Animal Sci. 2022; 5(1): 1108.

would more accurately portray the application of light to promote in vivo tissue healing through triggered mitochondrial activity, and ‘Soft Laser’ or LLLT would best describe the therapeutic treatment.

For consistency, the authors have used ‘Laser’ in lieu of either ‘Soft Laser’ or ‘LLLT’ when referring to laser treatments in this manuscript [3].

Method: A sampling of 18 patients with chronic inflammatory conditions had appointments to be seen at small animal veterinary clinics in Connecticut and Texas.

Clients were selected at random and offered the use of an at-home laser device. The primary aim was to determine if laser would improve treatment outcomes of recurring conditions. A secondary aim was to assess clients’ receptivity to augment the management of pets’ treatments by themselves at home rather than in-clinic. Patients were assessed at baseline and again on Days 14 and 28. Client interviews established the extent of compliance with the laser protocol; their comments elucidated the impact of treatment on patient behavior and quality of life; and clinical examinations evaluated if the improvement had been made with laser treatments compared to routine care the patient had received.

To further demonstrate the results of the subjective observations made by veterinarians and owners, several hi-tech devices were tested for the objective determination of the laser’s efficacy: A Digatherm Thermographic camera was used to measure changes in surface temperature due to inflammation; a Tekscan Strideway platform can aid in the identification of lameness by analyzing paw pressure, asymmetries and gait discrepancies over several strides.

Study results are to be used to assist in the decision to adopt a policy recommendation of at-home use of laser to improve treatment outcomes of conditions known to respond to laser therapy.

Introduction

The unforeseen arrival of COVID-19 has had a profound impact on the practice of veterinary medicine. Every facet of clinic life has been challenged as the world continues to slog through the uncertainties of life during a pandemic. For clinicians, safeguarding the health and welfare of staff and clients while maintaining a high standard of operational integrity so that patients continue to receive needed veterinary care is a daily, and often hourly, balancing act. The veterinary community’s response to life’s reality during COVID has been as swift as it had been unexpected.

The mandatory lockdowns and extended periods of self-isolation resulted in owners cohabiting more with their pets. And in attempts to moderate and manage the mental health effects of newfound seclusion, many people turned to the adoption of animals from shelters.3 This unanticipated increase of pets going into new homes--numbering some eight million dogs and cats--had a profound effect on how practices functioned (Figure 1 and 2).

Operational strategies

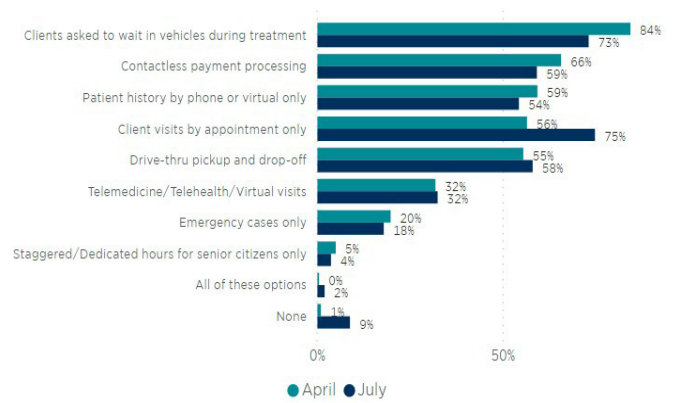


Figure 1: Modifications to clinic operations during COVID. From AVMA.org: Covid-19 Veterinary Survey Results 2021.

Many of them asked clients to wait in the parking lot while animals were brought into the clinic for treatment. At its height, 84% of practices had adopted this precaution [4]. As client traffic increased, this novel workaround was accepted as a short-term ‘new normal’. The emergence of COVID variants necessitated a continuous need for social distancing, using the parking lot as a waiting room, and having to tell longstanding clients that their pets could not be scheduled for days or even weeks. For staff, this evolved into a 24/7 struggle to effectively balance an overriding responsibility to preserve animal welfare and maintain good client relations while simultaneously ensuring the continued health of the public, colleagues and families.

Precautionary measures

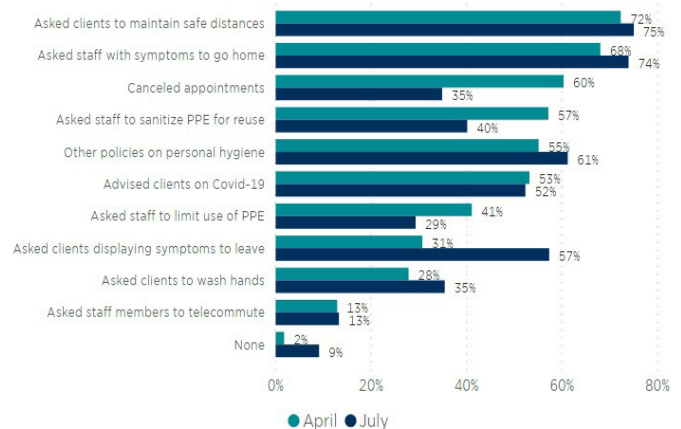


Figure 2: Public health procedures in clinics during COVID. From AVMA.org: Covid-19 Veterinary Survey Results 2021.

With each passing month, however, clients became less accepting of these new ways of doing business and more demanding of favorable treatment. Many veterinarians and critical practice support staff just left the field. The result was widely reported as a ‘crisis in veterinary practice’ leading to [5] a drastic reduction in office traffic, operational hours and days of service and the revision of workable staffing schedules. Despite the implementation of these changes, staff still had to be available for surgery and in-clinic care, particularly for those animals with chronic conditions.

In response, a third of the practices adopted telemedicine [6] as a means of maintaining contact with clients and evaluat-

ing patient care. Unfortunately, that did not work well for those pets in rehabilitation programs or with chronic conditions such as otitis, joint disease or gingivitis that can cause persistent pain and quickly exacerbate the problem if left untreated.

Concerned clients reported that pets with these conditions worsened during the pandemic because they were unable to be seen by their veterinarians in a timely manner. Already limited appointments were triaged even further, often triggering conflict between practitioners' and clients' assessments of the urgency of the medical situation.

Laser therapy is a routine, in-house treatment modality used in many practices to deal with frequently seen problems, e.g., ear infections and luxating patellae, [7] as well as rehabilitation, convalescence or chronic cases that require recurring clinic visits. But office time is already at a premium, and staff available for managing these treatments can often be more effective when assigned to emergencies and more serious cases. When longstanding, twice-weekly treatment appointments must be set aside, suffering and anguish by both pets and their caregivers can be aggravated, adding to pandemic-related mental health strain already experienced by hospital staff.

The Center for Devices and Radiological Health of the U.S. Food and Drug Administration (FDA) has approved the use of lasers for the treatment of many medical disorders, and it has become an established product in human medicine [8]. The B-Cure Laser Vet is now available for pets as a hand-held device to be used as an adjunct therapy to extend the effectiveness of in-clinic laser sessions. By enabling caregivers to maintain home-based treatments as an alternative to frequent office visits, hospital traffic can be reduced while still maintaining a high level of patient care.

The authors herein advocate engaging pet owners in the use of a safe, lightweight, hand-held Low-Level Laser Therapy (LLLT) device to maintain continuum of care at home. Clients accepting this option are empowered to become active partners in their animals' care, driving increased loyalty, treatment plan compliance and more successful outcomes, freeing staff to care for patients requiring acute care.

Background

One hundred years after Einstein introduced the concept that led to the development of the laser, what began as an interesting theory has developed into a flourishing technology with applications that touch innumerable aspects of industry, manufacturing, health care and everyday life [9].

An early therapeutic research application of laser was in cardiovascular surgery research in 1963. Since then, studies, refinement and investigations into the life sciences and medical and surgical clinical applications have resulted in numerous beneficial innovations and breakthrough functions that improve quality of life and patient outcomes [8].

As frequently happens with unconventional approaches to patient care, acceptance was slow and only grudgingly acknowledged in the field. Not knowing how to classify it, practitioners viewed healing with light as an 'alternative' or 'complementary' methodology rather than accepting it as a practical standard of care as had human medicine, surgery and dentistry. The unhurried adoption by veterinarians was due, in part, to the 'newness' of the science and skepticism how 'just a light' could find a place in the profession. It was simply too problematic for many

practitioners to accept. Additionally, reports of a few serious adverse events made practitioners wary of its uses and offered an excuse to demur, at least in the short term. From this very uncertain beginning, however, word spread anecdotally about the many cases that were unresponsive to prevailing standard treatment protocols but were successfully treated with lasers.

Thousands of scientific papers have been published that consistently document the positive, diverse and efficacious uses of light technology in therapeutic and surgical applications. Numerous research studies and clinical trials have described both the palliative effect and anti-inflammatory value lasers represent for both human and veterinary medicine. Given the frequency of adverse events associated with NSAIDs, PMB's safety profile provides a persuasive argument for its widespread adoption to accelerate healing, provide pain relief and decrease inflammation [10].

The scientific community now has a much better understanding and appreciation of how and why light healing works. Depending on the specific wavelength produced by the device when placed on or near the skin, the transcutaneous penetration of light generates changes at the cellular level, just like the sun's rays can darken the skin. When laser treatments are directed at damaged or diseased tissue, the cellular transformations induced can accelerate wound healing, stimulate the regeneration of compromised tissue and reduce painful inflammation.

The FDA has approved laser therapy for the treatment of pain, and according to pubmed.gov, over 4000 science research and clinical studies discussing lasers have been published. The adverse events initially associated with lasers used in clinicals have been significantly reduced by: continued improvement of device design; precise wavelength production; wider area under treatment; and depth of penetration only deep enough to treat inflamed joints or damaged tissues (Figure 3).

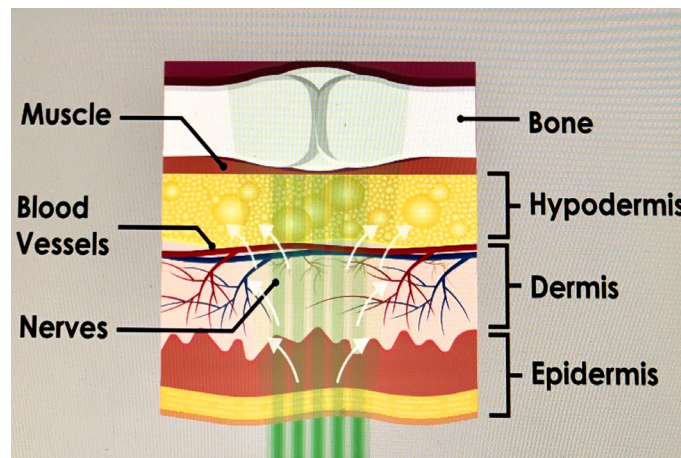


Figure 3: Drawing of tissue types effected by laser light therapy.

While the Class 2, 3 and 4 laser equipment typically utilized in human and veterinary hospitals must be labeled with a hazard classification, the B-Cure Laser Vet used in this study is registered as a Class 1 device, with no requirement for protective goggles for either pet parents or animals being treated.

Many veterinary hospitals include lasers in a variety of surgical procedures, as well as for: routine medical care; treatment of animals with both acute and chronic conditions; and rehabilitation therapy. A typical protocol may call for patients to receive twice a week laser treatment over an extended period.

The authors' studies evaluated how clients responded when a veterinary hospital routinely using in-clinic lasers to treat a variety of inflammatory-based conditions were offered an opportunity to continue treatment at home. A random sampling of candidates presented with inflammatory conditions (lick granuloma, joint disease, chronic otitis externa and feline gingivitis) were screened for enrollment. Twenty candidates were enrolled, of which fifteen completed the study.

Owners were instructed in the use of the B-Cure Laser Vet device (emitting light at a wavelength of 808nm and delivered with a penetration depth of 4 cm). Canine treatment sites included the external ear, carpus, knee joint and lumbosacral spine. Feline indications studied were limited to gingivitis. Re-checks at two weeks evaluated health status improvement for the patients receiving twice-daily treatments, with application times determined by the severity of the condition. While there was significant heterogeneity in the patient sampling, treatment areas and length of procedures, the positive interpretation of the results, especially from a practicing clinician's perspective, calls for the serious consideration of the inclusion of laser treatment therapy in routine veterinary practice, especially as an at-home adjunct to in-clinic treatment [11,12].

Study overview

Detailed Description

This is a multisite, unblinded, open-label trial of patients who have presented with routine inflammatory conditions evidencing chronicity.

Owners of twenty patients chosen at random during regular hospital visits will receive the loan of a handheld laser device to treat their pets twice a day at home, constituting a single treatment group. The device produces a single light beam at 808 nM wavelength over the treatment area. The attending veterinarian will determine the length of treatment sessions by assessing the severity and duration of the presenting indication.

Following the examination on Baseline Day 1, data will then be documented at clinic visits on Days 14 and 28. The primary aim, as reported by the pet owners, will be to identify patients' levels of inflammatory discomfort or pain. A secondary objective will be to determine the willingness and ability of owners to comply with the at-home treatment schedule.

The trial in dogs and cats enrolled patients of either sex over one year of age who presented with inflammatory conditions that had been treated for longer than six months.

The use of a B-Cure Laser Vet device at remote locations (n=17) showed statistically significant improvement in pain scores using veterinarian and owner visual assessments.

At both the interim (14 days) and final analysis (28 days), the laser treatments were effective at relieving pain. There were no adverse events reported.

This study demonstrates that laser therapy is a relatively fast-acting, safe treatment modality for the reduction of inflammation in dogs with osteoarthritis (OA) of the stifle and lumbosacral spine, gingivitis, chronic otitis externa and acral lick granuloma.

Seventeen of the twenty patients completed the trial, having followed the treatment protocol established for each animal with agreement from the owner. Two patients did not receive consistent treatment and were dropped from the study. Of the remaining animals, two exhibited a significant reduction in inflammation and pain scores. Ten of them showed moderate improvement, while three exhibited either mild or no discernable change from baseline.

Treating Inflammation Using Lasers

Clinical Discussion

Laser's Anti-inflammatory Mode of Action

A cornerstone of scientific discovery is the ability of investigators to verify by replication the findings reported by other researchers. One of the most consistently reproducible outcomes of the many laser studies that have been conducted across a broad array of indications is the ability of lasers or LED light to reduce acute and chronic inflammation. From a practice perspective, the fact that the response of various tissues exposed to laser light is not confined to a single tissue type is significant. Light therapy can: reduce inflammation and pain in treating joint disease, traumatic injuries or chronic and acute wounds, including those involving deep tissue; prevent tissue damage caused by cell death; or promote wound healing for many diseases [10,13,14].

An explanation of how this process functions was investigated by the National Aeronautics and Space Administration (NASA): Landmark research was conducted that provided a springboard for studies that further elucidated the effects of lasers at the cellular level and the resultant impacts on trauma and diseases.

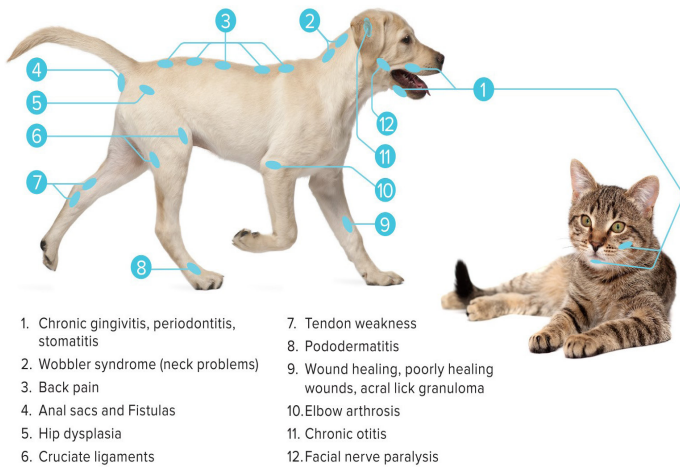
Just as the energy from sunlight triggers plant mitochondria to generate adenosine triphosphate (ATP) as an energy source that drives cellular metabolism, the energy from lasers stimulates metabolic processes at the cellular level.

When tissue stress results in cell damage or ischemia, cells produce mitochondrial nitric acid (MtNO) which binds to cytochrome C oxidase (CcO) and displaces oxygen. The oxygen depletion downgrades ATP synthesis and leads to oxidative stress, destabilizing the production of free radicals and antioxidants, which results in the tissue damage recognized as inflammation [15-18].

A laser's effect on damaged tissues occurs through the light energy that is absorbed by CcO, releasing MtNO and increasing ATP, thus reducing oxidative stress.

In the process, the cells in blood and lymph that have been stimulated by the localized light can travel, resulting in remote systemic effects that can be attributed to the use of the laser.

Lasers offer a transcutaneous, non-invasive process that can be directed at many different tissue types, including: lymph nodes, to lessen edema and inflammation; [19] trauma sites, to stimulate healing and reduce inflammation; [20,21] and nerves, to diminish pain [20-24] (Figure 4).



- | | |
|--|---|
| 1. Chronic gingivitis, periodontitis, stomatitis | 7. Tendon weakness |
| 2. Wobbler syndrome (neck problems) | 8. Pododermatitis |
| 3. Back pain | 9. Wound healing, poorly healing wounds, acral lick granuloma |
| 4. Anal sacs and Fistulas | 10. Elbow arthrosis |
| 5. Hip dysplasia | 11. Chronic otitis |
| 6. Cruciate ligaments | 12. Facial nerve paralysis |

Figure 4: Canine and feline laser treatment sites and conditions.

Lasers Reduces Non-Inflammatory Inflammation

Arthritis is categorized as either inflammatory, a complicated autoimmune disease, or non-inflammatory. Osteoarthritis (OA) is the most common arthropathy in dogs and cats, and despite being classified as non-inflammatory, it results from inflammatory changes in the joint that are caused by loss of synovial fluid and the degradation of healthy cartilage which functions to prevent bone-on-bone contact. Being attached to bones, muscles and tendons, any disorder involving joints can have a profound effect on function and wellbeing for both affected pets and caregivers [25].

OA in pets was once accepted as being associated with normal wear-and-tear and the aging processes, leading to cartilage breakdown. Better quality diets and advances in health and veterinary care have increased the longevity of dogs and cats. But the sedentary lifestyles of many companion animals have led to a substantial increase in obesity and one of the main causes of OA. Over the past ten years, obesity in dogs has increased by 66%, and the feline population has undergone a startling 150% surge. The increased body weight places additional stress on joints, causing inflammation of the membrane lining, the genesis of OA. Rather than being confined to older animals, OA is now diagnosed at all stages of pets' lives and is one of the most common reasons for veterinary clinic visits where the inflammation, swelling, pain and loss of function associated with OA are preferentially managed medically rather than surgically [26,27].

Chronic Inflammation

Case Studies

Unfortunately, there is never a dearth of cases in veterinary practice because of some form of inflammation. The nature and variety of inflammatory disorders, the many systems that can be affected, and the negative impacts it can have on function and wellness make the effectual management and control of immune-mediated ailments of critical importance.

The widespread acceptance and use of lasers for clinical applications in human medicine make it a technology worthy of growing in popularity as a non-invasive treatment modality in veterinary medicine.

The following cases are examples of the use of a laser in treating routine conditions seen in clinical practice and how the technology can facilitate healing with the support of an owner committed to enhancing the treatment and care of their pets during and post-pandemic.

Degenerative Disc Disease

Clinical Discussion

Canine Degenerative Disc Disease (DDD) has many causes and a descriptive nomenclature that is as varied as the etiologies that ultimately lead to spinal inflammation and pain: lumbosacral disease, spinal cauda equina syndrome, lumbosacral stenosis, degenerative lumbosacral stenosis, lumbosacral spondylopathy, spondylolisthesis and more.

Chondrodystrophic breeds are genetically the most common breeds at risk and include Dachshunds, Beagles, Shih Tzus, Lhasa apsos and Pekingese, among others. Non-Chondrodystrophic breeds frequently affected are German Shepherds, Labrador Retrievers and Doberman pinschers. Athletic, military and police dogs are also susceptible to lumbosacral problems. In general, the most subtle cause of vertebral and joint disease is obesity. Regardless of the site of arthritis, frequent results are pain, loss of function, disease or illness.

Laser therapy is particularly effective in ameliorating the inflammation that is at the core of many joint ailments. This conclusion is borne out by the extensive use of lasers in treating people with osteoarthritis.

Baseline: Day 1 (10/14/2021)

A 60 lbs, male, 13-year-old German Shorthair Pointer presented with a history of hind end weakness, back discomfort and soreness (Figure 5a).

At the initial evaluation, it was clinically established that the patient was struggling with back pain: When just mild pressure was applied to the T11-L3 area, he would immediately sit down to avoid palpation and pain.

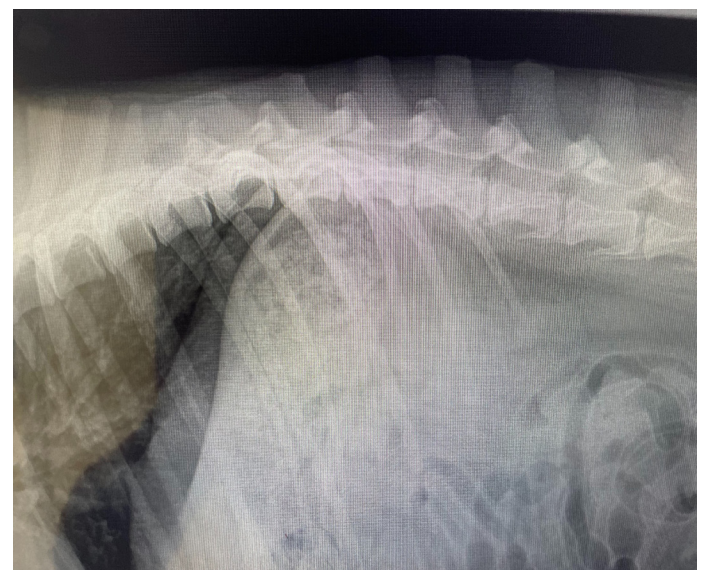

Figure 5a: Thoracolumbar Disc Disease at T11-T13.




Figure 5b: Example of lumbosacral laser treatment.

The treatment protocol called for the B-Cure Laser Vet to be targeted at the T11-L3 area on both sides of the spinal processes for eight minutes, twice daily Figure 5b.

Recheck 1: Day 15 (10/29/2021)

- The owner reported that she had been compliant with the BID treatment sessions.
- Unsteadiness and weakness in the dog’s back end were not observed.
- The pet has been showing extra bouts of “puppy energy” which had been long absent.
- Prior to the laser treatments, the dog had been reluctant to jump into the car. Currently there is no such hesitation.

Recheck 2: Day 29 (11/12/21)

- Owner compliance continued as did the dog’s improved clinical response.
- The owner noted that the dog did not have as much “puppy-like energy” as he had earlier, but that he “was doing really, really well”.

Clinician’s notes

Objective evaluation of the patient in the exam room using digital thermography coupled with the owner’s subjective experience after the first two weeks of laser use were “amazing”: The animal was more comfortable, increasing his performance confidence. Overall, the laser treatment was a great success for this patient.

The owner’s protocol compliance was critical to achieving a positive outcome for this dog. But so, too, was the understanding that the product’s safety profile was well established. She valued the fact that she had played an active and pivotal role in the alleviation of her pet’s pain and the improvement of his quality of life.

Digital thermography in veterinary practice is used to identify areas of inflammation caused by increased blood flow and elevated body temperature. A non-invasive remote infrared camera scans the skin and measures the surface temperature, which is displayed as a multicolored image (Figure 5c).

Canine Body Surface Temperature (BST) readings are lower than rectal temperatures (101.0 to 102.5 oF). Median BST values differ based on the length and type of the animal’s coat, namely [38(28)].

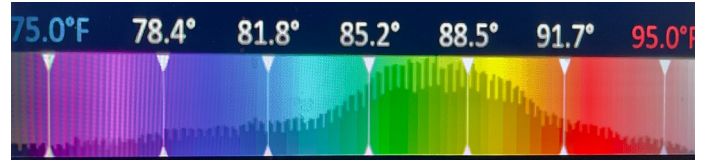


Figure 5c: Digital thermography temperature/color scale. www.digatherm.com

Coat Type	BST
Short coat (SC)	89.2°F
Long coat (LC)	82.7°F
Double coat (DC)	82.9°F
Curly coat (CC)	85.7°F

The baseline thermographic reading for this patient was 93.2°F, well above the norm of 89.2°F. The extent of inflammation seen in red was dramatic (Figure 5d).

At Recheck #1, the digital thermograph showed that there had been a drastic drop in inflammation to 88.7°F. It was apparent that the area of inflammation had been significantly reduced from that observed at baseline (Figure 5e).

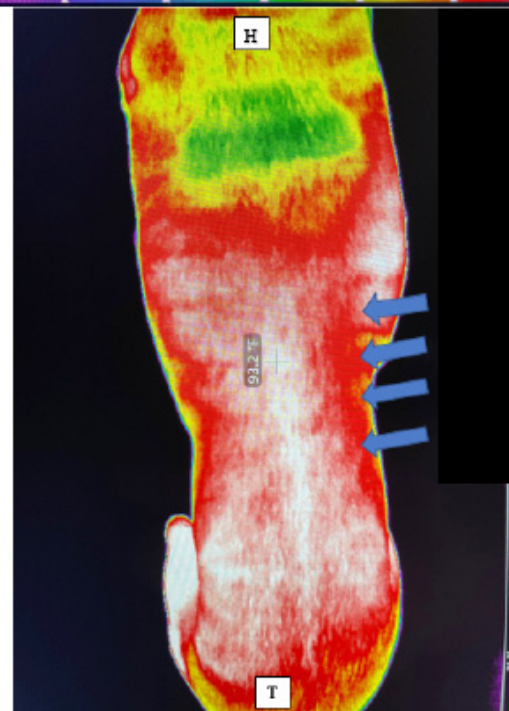
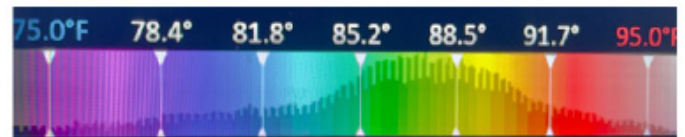


Figure 5d: Baseline Day 1. Looking down at spine.

Red represents inflamed tissue on either side of the vertebral column. BST = 93.2°F.

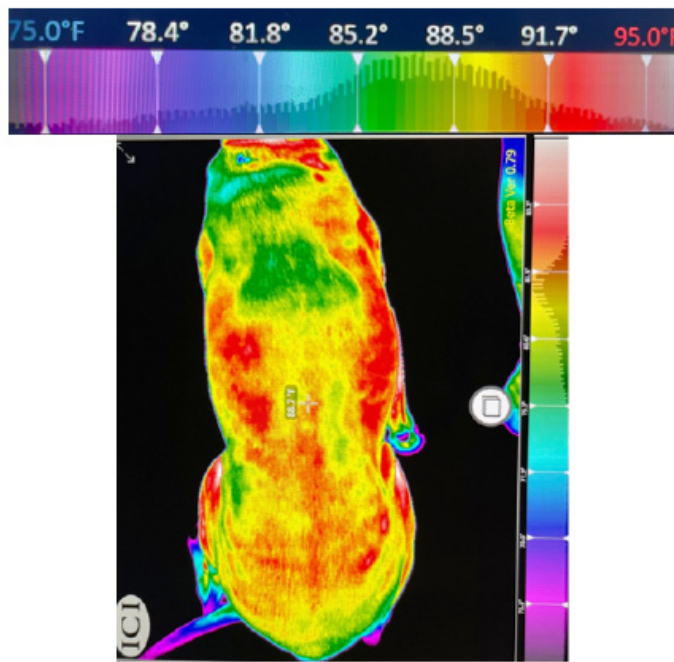


Figure 5: Recheck #1. After two weeks of laser treatments, the inflammation has decreased. BST = 88.7°F.

Canine Stifle Joint

Clinical discussion

One of the most frequently identified canine problems in practice today is the presentation of rear limb lameness. The most common diagnosis is anterior cruciate tear and/or luxating patellae.

Human and animal studies have shown the ability of lasers to provide faster healing from ACL trauma.

An ACL tear in people is usually an acute trauma after running or making a sudden change in direction. Canine ACL tears, however, more typically occur after minor, repetitive stressors weaken the ligament enough so that a small jump or walking up stairs is enough to completely tear the ligament.

Lifestyle also influences the susceptibility to ACL tears: Routine, modest activities like walking on-leash may be interspersed with a bout of intense exercise like running in the park. Being overweight greatly increases the risk of ACL injury, especially during this type of activity.

Case #1

Baseline: Day 1 (10/28/2021)

A 22 lbs, 12-year-old male German Spitz, with a history of intermittent left hind lameness, was first diagnosed on 3/26/21 with stifle instability. Carprofen and an over-the-counter (OTC) joint supplement were dispensed to the owner for in-home treatment.

The patient continued to limp and presented again on 10/28/2021. Physical examination elicited a cranial draw sign accompanied by effusion and stifle instability. From presenting history and examination, a diagnosis of a partial tear of the anterior cruciate ligament (ACL) was made. Age and other factors ruled out ACL surgery as a treatment option.

A regimen of the B-Cure Laser Vet was offered, targeting an area directly over the lateral surface of the knee joint and patella. Due to the dog's small size, it was felt the one location be ad-

equate. Four-minute sessions, twice a day were recommended.

Recheck 1: Day 14 (11/11/2021)


- Within two days of initiation of the laser treatments, the owner reported that the dog was again able to sit upright, his increased strength having improved his ability to stand up from a sitting position.
- Limping was reduced, and he was walking faster and able to make sharper turns.
- The patient was no longer, “bunny hopping” to climb stairs, but was stepping up using both legs.
- The Spitz did not struggle when trying to lie down or to change position when at rest.

Recheck 2: Day 32 (11/29/2021)

- The owner reported that the improvements were continuing and consistent.
- The dog was “getting up really well and even running,” and that overall, he was just “a happier guy.”

Clinician’s notes

Although stifle effusion was still present at the second recheck, the pain reduction was evidenced by the animal’s gait and overall improved behavior, enriching the quality of life for both the patient and caregivers. The owner considered the results a great success and opted to continue the at-home treatments.



Video 1: Case 1 Baseline Day 1.



Video 2: Case 1 Recheck Day 32.

Case #2**Baseline: Day 1 (10/25/2021)**

An 8-year-old Dachshund presented with a history of intermittent limping on the left rear leg for four weeks prior to the exam. The owner described episodes of “tap, tap, tap” toe-touching throughout the day and had observed occasional leg tremors.

Physical examination revealed a decided decrease in range of motion and a ‘click’ in the left stifle with mild effusion. Performing a left hip extension caused a ‘click-pop’ movement in the left stifle.

Laser treatments were proposed, focusing the beam directly over the lateral surface of the knee joint. It was assessed that the patient was small enough that targeting one location, for minutes, twice per day would be adequate therapy time. The client was to continue offering an OTC joint supplement and carprofen and gabapentin PRN were dispensed.

Recheck 1: Day (11/11/2021)

- The owner reported that the dog was doing “really well”.
- No limping was observed on the left rear leg.
- Very pleased with the dog’s improvement, the client chose to continue the twice daily treatments for another two weeks.

Recheck 2: Day 17 (11/29/2021)

Since the previous visit, the dog was admitted for obstruction surgery and repair of a preexisting pericardial hernia.

Although the owner was unable to continue the laser sessions, she reported that there had been no signs of limping once the laser regimen had begun four weeks earlier.

Clinician’s notes

Unfortunately, the underlying cause of the limp was never confirmed, and the attending veterinarian never observed the dog’s limp because it occurred intermittently.

A post-B-Cure behavior video was prevented by the intervening surgery. Nonetheless, the owner was convinced that her dog had improved quickly after initiating the treatments.

Case #3**Baseline: Day 1 (10/29/2021)**

A 12-year-old, male Shepard-mix presented with a history of bilateral anterior cruciate ligament injuries accompanied by bilateral stifle effusion. The initial orthopedic examination in 2012 identified a full ACL tear on the right and in 2013, a partial left tear.

Baseline examination confirmed the earlier diagnoses and the presence of pronounced, bilateral joint effusion and crepitus.

Laser treatments focused on the lateral surface of each stifle for four minutes, twice a day. No other supplements or medications were offered.

Recheck 1: (11/12/2021)

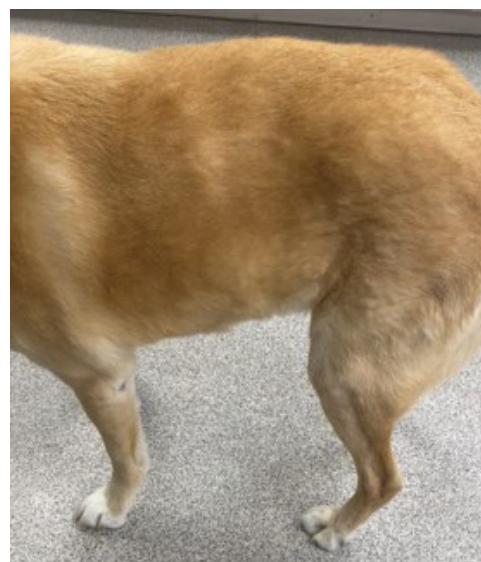The client did not return for the two-week revisit.

Recheck 2: Day 39 (12/6/2021)


- The owner reported that the dog was doing “really well”, had more “pep in his step” and was walking with confidence.
- She had been compliant with the laser treatments for the first two weeks, but because of “life and kids” could not make the scheduled 11/12/2021 revisit and was unable to treat the dog for two weeks. Both twice daily treatments were restarted this week.
- Consistent with his age, the patient had been sedate but had become progressively more playful over the previous two weeks.

Clinician’s notes

In the opinion of the attending veterinarian, there was improvement since the initial visit, and the laser treatment had had a positive impact on the dog’s comfort level by reducing the pain associated with the cruciate damage without the need for NSAIDs or nutritional supplements.

**Video 3:** Case 3.

Baseline Day 1

**Video 4:** Case 3.

Recheck Day 39

Case #4

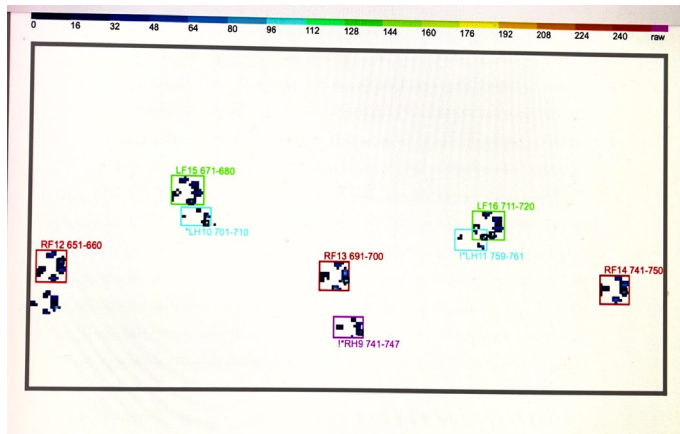


Figure 6a: Note narrowed gait- common sign of hip dysplasia.

Baseline: Day 1 (10/29/2021)

At Baseline, the patient was seen because she had been showing signs of rear end pain over the previous two weeks. She was relaxed when the owner brought her into the exam room but became apprehensive and aggressive when an attempt was made to touch the pelvic area.

X-rays were taken: The pelvic views revealed poor acetabular coverage of the femoral heads with mild subluxation of the joints. Additionally, radiographs of the elbows revealed mild degenerative joint disease on the left with periarticular osteophytes and enthesophytes. A diagnosis of hip dysplasia (HD) was made.

The clinician concluded that the pain caused by the bilateral hip dysplasia contributed to the patient’s impaired gait and her anxiety.

A dynamic gait analysis revealed a narrowed stance Figure 6a, an abnormality consistent with the diagnosis of canine hip dysplasia.

A course of B-Cure Laser Vet therapy was prescribed for four minutes each for both hips and the left elbow.




Figure 6b: Return to a more normal stance and gait.

Recheck 1: Day 15 (11/12/2021)

The client reported that the patient had slipped going down stairs and bruised her elbow. The recheck was rescheduled.

Recheck 2: Day 38 (11/26/2021)

- Except for a week after the dog’s fall, the owner was able to maintain a regular treatment schedule.
- While still apprehensive when her back was touched, the dog was not aggressive.
- The dynamic gait analysis showed a more normal paw strike pattern Figure 6b.
- The recommendation that the laser sessions be continued on a regular basis was given based on: progressive nature of hip dysplasia; concerns about the possible adverse side effects of long-term NSAID usage; and the potential for the joint disease of the elbow to be further aggravated when weight was shifted from the rear legs.

Clinician’s notes

Hip dysplasia is recognized as the most common orthopedic condition in medium and large size dogs, with an especially high prevalence (10-70%) in certain pure breeds [29,39]

To alleviate the pain associated with HD, some dogs will adjust their stance and walk or stand with their hind legs closer together. Figure 6a. Patients experiencing severe pain will become aggressive in an attempt to avoid having to move or in response to unwanted or painful contact.

Chronic Otitis Externa

Clinical discussion

Otitis Externa (OE) is a common and often painful inflammatory condition affecting the canine ear canal and pinna. OE is among the most frequent diagnoses in veterinary practice, with an incidence reported between 7-20% [30].

Allergic dermatitis and resultant infection are primary causes of canine OE. While anatomy can play a role in predisposing some dogs to OE, the cyclic nature of the conditions which incline dogs to OE, are primarily what leads to the propensity for chronicity. The identification and elimination of elements that may facilitate the development of OE are key to the successful resolution and treatment of the problem. Reducing the inflammatory response in the canal and on the pinna are essential components required for a reduction of the signs and symptoms associated with OE [31-33].

Because the use of lasers to treat OE does not require contact with medication or swabs, it is a practical choice in routine treatment protocols for ear problems, either as a standalone or in conjunction with oral and topical medications. This is especially significant in dogs who have experienced repeated bouts of otitis and whose canals may be reduced in diameter or even nonexistent.

Baseline: Day 1 (10/29/2021)

An 11-year-old, 89 lbs, Body Condition Score (BCS) 7/9 mixed-breed dog was presented with a severe unilateral ear infection.

The vertical ear canal was virtually nonexistent on initial exam. A sample of the exudate from the top of the canal was taken for culture and sensitivity, revealing a combination of Pseudomonas and B-streptococcus.

The attending veterinarian wrote prescriptions for: a compounded topical otic medication; a six-week course of oral marbofloxacin; laser treatments of four minutes, twice a day, targeting two sites approximating the track of the vertical ear canal; and a multipurpose, twice daily, antimicrobial/antifungal ear wash to be given as an in-home treatment.

Recheck 1: Day 14 (11/12/2021)

- The owner reported that she did not fill the prescriptions for either the compounded ear or oral medications because of the expense. Additionally, she lost the ear flush. Thus, at the time of this recheck, only the B-Cure Laser had been used.
- Upon examination, there was no odor, and the inflammation had lessened, revealing a patent canal.
- The client's preference was to hold off on using any prescription ear medications, but she stated that she would start to flush the ear and continue using the laser.

Recheck 2: Day 14 (11/29/2021)

- The owner reported that she had been noncompliant for the previous two weeks, having used neither the ear flush nor the laser treatment.
- She requested a referral to a dermatologist, and an appointment was made for 12/14/21.

Clinician's notes

- The results seen at the first recheck were truly surprising: The lining of the canal had shrunk, allowing the vertical canal to be visualized.
- On the second visit, the odor from the left ear had returned, with visible pus in the vertical canal.
- Compliance matters: After the significant improvement seen at the first visit, the fact that the owner did not continue treatments was disappointing.

Feline Gingivitis

Clinical discussion

Gingivitis is an inflammation of the gums, usually accompanied by hyperplasia, bleeding, hyperemia, viral and/or bacterial infection and odor.

Causes for inflammation may be the result of: viral infections, e.g., feline viral rhinotracheitis (FVR); calicivirus (FCV); feline leukemia virus (FeLV); and/or feline immunodeficiency virus (FIV); or bacteria, e.g., Bartonella, plaque buildup or autoimmune disease [34].

While bacteria are frequently involved, they are rarely the primary cause of inflamed gums. The inflammatory process can extend to the root of the teeth, causing progressive dental decay and bone loss.

Plaque, the bacterial film that forms on teeth, can trigger aggressive gingival inflammation that starts around an affected tooth and can quickly progress to the surrounding tissue of the mouth and tongue.

Tooth extraction is frequently conducted, often in an unsuccessful attempt to reduce the inflammation.

Case #1

Baseline: Day 1 (10/29/2021)

A 5-year-old, 12 lbs, spayed BCS 5/9 Sphinx presented with a history of chronic oral disease (initially diagnosed on 3/20/2021) with inflammation along the gingival line (Figure 7a).

Tests for FeLV/FIV and Bartonellosis were negative. The cat was seen again on 8/30/21 because the gingivitis had rapidly progressed to gingivostomatitis with periodontal disease. There had been a rapid progression to an advanced stage of disease, despite having been previously treated with antibiotics and steroids.

The size of the patient allowed the laser beam to completely cover both the upper and lower dental arcades from canines to rear molars. One application per side for four minutes, twice a day was recommended. The probe did not have to be in contact with the skin, and the patient was relaxed during the early treatments.

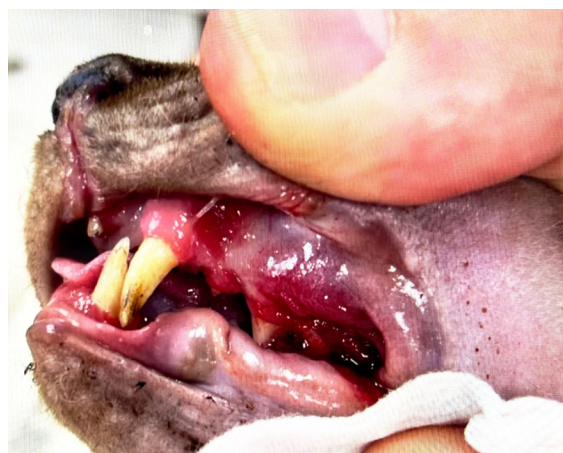


Figure 7a: Gingivostomatitis before laser treatment.

Recheck 1: (11/12/2021)

According to the owner, the greatest challenge with the treatment sessions centered on the beeping of the timer. The patient eventually did acclimate to it, but the cat was sometimes "not in the mood". Despite this, the inflammation that was initially noted had improved.

Recheck 2: (11/29/2021)

The owner reported that towards the end of the treatment schedule, the patient began objecting to the handling.

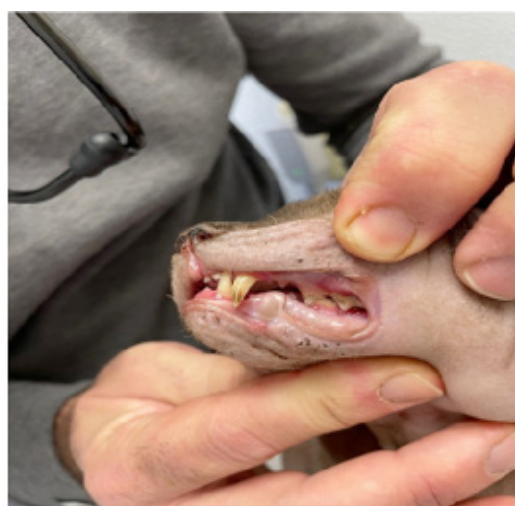

Figure 7b: After treatment with B-Cure Laser Vet.

Clinician's notes

The attending veterinarian was disappointed because there had been an expectation of better results. For at-home treatment to be successful, protocol compliance by the owner and the patient's willingness to sit for the duration of the session is required.

Despite limited compliance, there was improvement, Figure 7b but the option of continued at-home treatment for this patient was not a practical solution.

Case #2

Presented was a 10-year-old, castrated, domestic short-haired cat weighing 12 lbs with a BCS 5/9.

There was advanced upper arcade gingivitis and hyperemia, and the lower premolar 1, premolar 2 and upper canine were absent. (Figure 8a).

Treatment sessions of four minutes, twice a day were recommended.

Recheck 1: (11/12/2021)

The owner stated she had not been compliant for the first two weeks. There was no noticeable improvement from the Baseline examination.

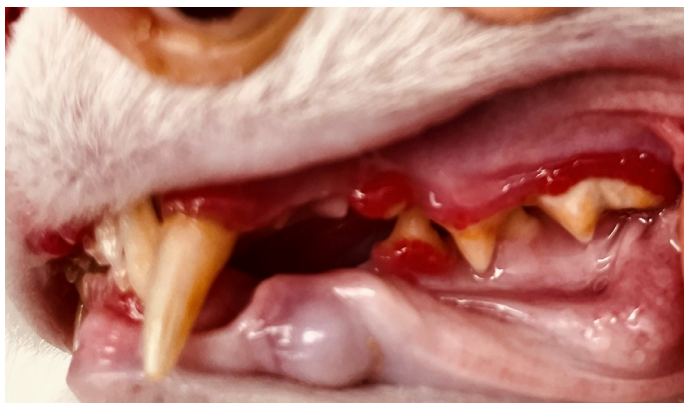

Figure 8a: Gingivitis before B-Cure Laser Vet Treatment.

Recheck 2: (11/29/2021)

The owner reported that she had been more compliant over the past two weeks.

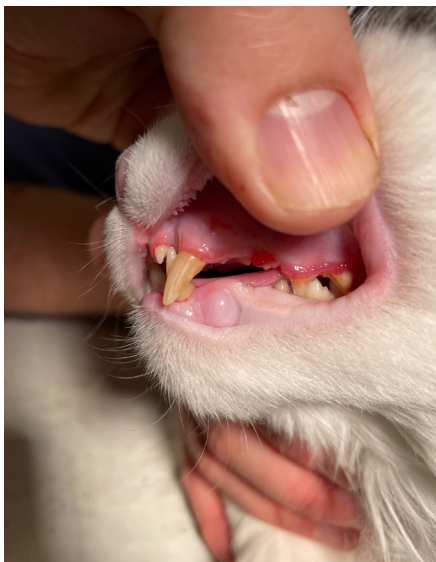

Figure 8b: Post-treatment with B Cure Laser Vet.

Clinician's notes

There was noticeable improvement in the gingival hyperemia, and the cat was less resistant to oral examination. Although the condition was not fully resolved, it was recommended that at least a once daily treatment be continued. Figure 8b.

Acral Lick Granuloma

Clinical discussion

Lick granulomas are pruritic lesions that develop as the result of excessive licking, primarily at the dorsal carpus, metacarpus or metatarsus. The lesions appear as firm, raised alopecic plaques surrounded by saliva-stained fur.

Multifactorial etiologies can lead to granulomas and may include: boredom, joint pain, allergies, wounds, trauma, foreign body or psychological stressors, like separation anxiety. The one common presenting feature is constant licking [35]. Whatever the causal agent is that initiates inflammation, licking of the site elicits further irritation and the cycle that initiates the development of the lesion.

Medications and bandages are easily licked or chewed off. Antibiotics and intralesional steroid injections and surgery can be effective but may only temporarily reduce inflammation of the deeply affected skin once compulsive behavior develops [36-38].

Treatment Day (11/1 - 11/29/2021)

A 12-year-old, female Golden Retriever, 85 lbs, BCS 7/9 was referred to the laser study by a veterinarian who was treating the patient for chronic acral lick granuloma. Previously diagnosed with arthritis at the left carpus, it was assumed that the inflammation fixated the dog's attention to a readily accessible area. To alleviate the discomfort, she started to lick the site. This caused additional inflammation, which triggered further licking, and a vicious cycle was set in motion.

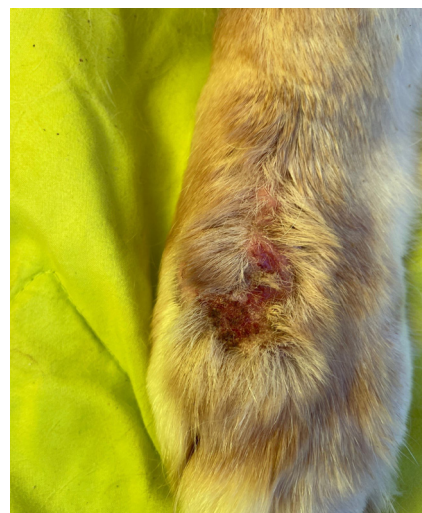

Figure 9a: Day 1.

Baseline: Day 1 (11/1/2021)

The treatment protocol called for targeting the area over the lesion, Figure 9a roughly divided into left and right halves, with each side receiving a four-minute treatment twice a day. No other medication was prescribed, and radiographs were planned at the conclusion of the study to determine the extent of the arthritis in the paw and to establish an appropriate treatment plan.

Recheck 1: Day 14 (11/15/2021)

The owner reported that the dog was no longer fixated on and continually licking the paw. There had been boosted wound healing, Figure 9b and the dog's gait had improved.

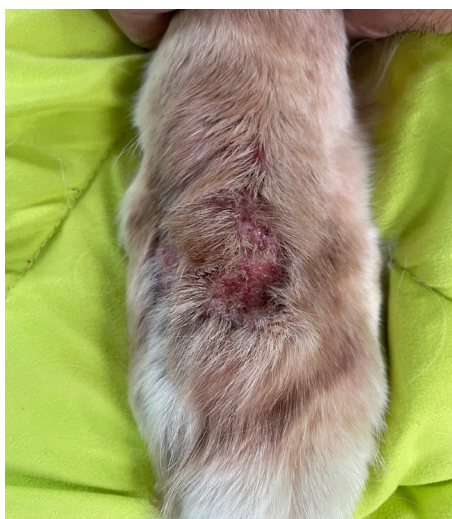


Figure 9b: Day 14.

Recheck 2: Day 28 (11/29/2021)

The owner reported that the dog's gait continued to improve and licking of the paw had ceased.

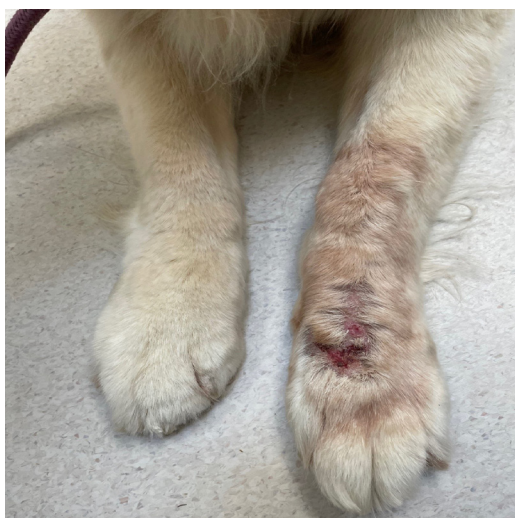

Figure 9c: Day 30.

Clinician's notes

Given the patient's history of having been previously treated for arthritis of the left forelimb, it was assumed that ongoing carpal pain induced the satiating behavior that led to the licking and chronic skin lesion.

The improvement of the skin was impressive and can be seen in the photos. Since no other products were used during the trial, wound healing was attributed to the use of the laser. The improvement in ambulation was even more impressive: The Retriever was once again pulling the owner across the parking lot!

Pain or irritation in distal limbs, both acute and chronic, can easily initiate attempts by the patient at behavioral satiation of the affected area through licking. The dermatitis thus produced causes further inflammation and the formation of a chronic lick granuloma, [39] the condition this patient experienced. Lesion improvement with the laser treatments was gradual but consistent, as can be seen in Figure 9c. The attending veterinarian focused on managing the dermic inflammation and did not anticipate gait improvement as a secondary benefit of the treatments.

However, x-rays showed no indication of any arthritic changes in the distal forelimb. Understanding that both the licking and limping were the results of the skin inflammation, a recommendation of a continuing, but reduced, regimen of laser treatments was considered.

Conclusion

Given the documentation and testing of innumerable applications, the B-Cure Laser Vet has demonstrated its value as an adjunct modality in veterinary practice.

The ability for clients to manage their pets' medical conditions at home can augment the quality of patient care and reinforce their positive relationships with their veterinarians.

Conflict of interest statement: J. Ehrenzweig received a stipend from the manufacturer for directing this work. No other known conflicts of interest exist for this study.

Appendix

Tables:

[A] Indication	ID	Patient					Presenting clinical sign	Visit 1 Baseline Day 1	Visit 2 Recheck 1 day 14	Visit 3 Recheck 1 Day 14	Visit 3 Recheck 2 Day 28
		Species	Sex	Age	Weight	BCS					
OA DDD	DDD Case #1	C	M	13	60	5/9	Inflammation	3	1	1	1
							Pain	3	1	1	1
							Function	3	1	1	1
OA Stifle	Stifle Case #1	C	M	12	22	7/9	Inflammation	4	2	2	2
							Pain	4	2	2	2
							Function	4	1	1	1
OA Stifle	Stifle Case #2	C	M	8	20	5/9	Inflammation	3	0	0	0
							Pain	2	0	0	0
							Function	2	0	0	0
OA Stifle	Stifle Case #3	C	M	12	62	6/9	Inflammation	4	Missed	2	2
							Pain	4		2	2
							Function	4		2	2

OA HD	HDTX Case #1	C	M	4	48	4/9	Inflammation	3	Missed	2	2
							Pain	3		2	2
							Function	3		2	2
Chronic Otitis	Otitis Case #1	C	M	11	89	7/9	Inflammation	3	2	2	2
							Pain	3	1	2	2
							Head shaking	4	2	3	3
							Discharge	4	2	3	3
							Odor	4	2	3	3
Gingivitis	Gingivitis Case #1	F	SF	5	12	5/9	Hyperemia	4	2	2	2
							Swelling	4	2	2	2
							Stomatitis	4	3	2	2
							Pain	4	3	2	2
Gingivitis	Gingivitis Case #1	F	M	12	12	5/9	Hyperemia	3	2	2	2
							Swelling	3	2	2	2
							Stomatitis	3	2	2	2
							Pain	3	1	1	1
Lick Granuloma	LG Case #1	C	SF	12	85	5/9	Inflammation	3	2	2	2
							Pain	3	1	1	1
							Function	4	2	1	1
							Licking	4	1	1	1

Pain, Inflammation Scoring: 0: Normal; 1: Minor; 2: Moderate; 3: Severe; 4: Extreme.

[B]	Visit	1	2	3	4	5	6	7	8	9	10	Total Visits		
												Visit 1	Visit 2	Visit 3
OA DDD Case #1	1	2	2	4	0	0	0	2	1	0	0	11	9	9
	2	2	2	2	0	0	0	2	1	0	0			
	3	2	2	2	0	0	0	1	1	0	0			
OA Stifle Case #1	1	3	3	3	3	3	3	3	3	3	2	29	13	10
	2	1	1	1	1	1	1	2	2	2	1			
	3	1	1	1	1	1	1	1	1	1	1			
OA Stifle Case #2	1	1	1	2	1	1	1	1	0	1	0	9	0	0
	2	0	0	0	0	0	0	0	0	0	0			
	3	0	0	0	0	0	0	0	0	0	0			
OA Stifle Case #3	1	4	4	4	3	3	3	3	3	3	3	33	-	20
	2	-	-	-	-	-	-	-	-	-	-			
	3	2	2	2	2	2	2	2	2	2	2			
OA HD TX Case #1	1	1	2	2	1	2	2	0	4	4	0	18	-	16
	2	-	-	-	-	-	-	-	-	-	-			
	3	3	2	2	2	2	2	0	2	1	0			
Chronic Otitis Case#1	1	1	1	4	2	0	0	2	2	2	1	15	13	13
	2	1	1	2	2	0	0	2	2	2	1			
	3	1	1	2	2	0	0	2	2	2	1			
Gingivitis Case #1	1	1	1	4	2	0	0	2	2	2	1	15	13	13
	2	1	1	2	2	0	0	2	2	2	1			
	3	1	1	2	2	0	0	2	2	2	1			
Gingivitis Case #2	1	1	1	3	1	0	0	0	0	0	0	6	4	4
	2	1	1	1	1	0	0	0	0	0	0			
	3	1	1	1	1	0	0	0	0	0	0			
Lick Granuloma Case #1	1	4	3	4	3	4	2	3	2	3	3	31	15	12
	2	2	1	1	2	2	2	1	1	1	1			
	3	2	1	1	1	1	2	1	1	1	1			

Quality of Life Indicators

1: Happy, Bouncy; 2: Happy, Content; 3: Comfortable; 4: Quiet; 5: Rigid; 6: Restless; 7: Indifferent; 8: Nervous, Anxious, Fearful; 9: Hunched, Tense; 10: Depressed, Unresponsive.

[C] Indication	ID	Patient					Presenting Clinical Sign	Visit 1 Baseline Day 1	Visit 2 Recheck 1 Day 14	Visit 3 Recheck2 Day 28
		Species	Sex	Age	Weight	BCS				
OA DDD	DDD Case #2	C	SF	11	58	6/9	Inflammation	2	2	2
							Pain	2	2	1
							Function	1	1	1
OA Stifle	Stifle Case #3	C	M	12	22	7/9	Inflammation	3	3	2
							Pain	4	3	2
							Function	4	2	2
Otitis	Otitis Case #2	C	SF	8	20	56/9	Inflammation	3	3	2
							Pain	2	2	2
							Head shaking	3	1	2
							Discharge	1	1	1
							Odor	1	1	0
Chronic Otitis	Otitis Case #3	C	M	12	62	6/9	Inflammation	3	3	2
							Pain	3	3	2
							Head shaking	3	2	2
							Discharge	2	2	2
							Odor	2	1	1
Otitis	Otitis Case #4	C	M	14	78	8/9	Inflammation	3	3	3
							Pain	2	2	2
							Head shaking	3	2	2
							Discharge	3	2	2
							Odor	3	2	2
Otitis	Otitis Case #5	C	M	8	69	5/9	Inflammation	2	1	2
							Pain	3	2	2
							Head shaking	4	4	3
							Discharge	3	2	3
							Odor	2	2	3
Gingivitis	Gingivitis Case #3	C	F	8	39	6/9	Hyperemia	3	2	1
							Swelling	2	2	1
							Stomatitis	2	3	2
							Pain	2	3	2
Gingivitis	Gingivitis Case #4	C	M	6	65	6/9	Hyperemia	3	2	2
							Swelling	1	2	2
							Stomatitis	1	2	2
							Pain	1	1	1
Pododermatitis	PD Case #1	C	M	10	55	8/9	Inflammation	3	3	2
							Pain	3	1	1
							Function	1	2	1
							Licking	3	2	2

Pain, Inflammation Scoring: 0: Normal; 1: Minor; 2: Moderate; 3: Severe; 4: Extreme.

References

1. Zinth Wolfgang, Laubereau Alfred, Kaiser Wolfgang. The Long Journey to the Laser and its Rapid Development after the European Physical Journal H, Historical Perspectives on Contemporary Physics. 2011; 36: 153-181.
2. Hamblin, Michael. Photobiomodulation or Low-Level Laser Therapy, Journal of Biophotonics. 2016; 9: 1122-1124.
3. ASPCA Pandemic Pet Ownership Survey. 2021.
4. American Veterinary Medical Association: Resources-tools. Animal-health-and-welfare in COVID-19.
5. Banfield Releases State of Pet Health Report. 2019.
6. Using telemedicine to help care for veterinary patients during COVID-19. 2021.
7. Fessehav, H., Laser Therapy and its Potential Application in Veterinary Practice- A Review, School of Veterinary Medicine, Wolaita Sodo University, Ethiopia
8. Choy J. History of Lasers in Medicine, Thoracic Cardiovascular Surgeon. 1988; 36: 114-117.
9. Zinth W, Laubereau A, Kaiser W. The long journey to the laser and its rapid development after 1960, The European Physical Journal H. 2011; 36: 153-181.
10. Cotler HB, Chow RT, Hamblin MR, Carroll J. The Use of Low Level Laser Therapy (LLLT) OFR Musculoskeletal Pain. MOJ Orthop Rheumatol. 2015.
11. Bjordal J, Couppe C, Chow RT, Tuner J, Ljunggren EA. A systematic review of low-level laser therapy with location-specific doses for pain from chronic joint disorders, Australian Journal of Physiotherapy. 2003; 49: 107-116.
12. Cotler HB. A NASA discovery has current applications in orthopedics, Current Orthopedic Practice. 2015; 26: 72-74.
13. Hamblin MR. Mechanisms and applications of the anti-inflammatory effects of Photobiomodulation, AIMS Biophysics. 2017; 4: 337-361.
14. Karu TI. Mitochondrial signaling in mammalian cells activated by red and near-IR radiation. Photochem Photobiol. 2008; 84: 1091-1099.
15. Ehrreigh SJ, Furchatt RF. Relaxation of mammalian smooth muscles by visible and ultraviolet radiation. Nature. 1968; 218: 682-684.
16. Mitka M. Nobel Prize winners are announced: Three discoveries of nitric oxide activity. J Am Med Assoc. 1998; 280: 1648.
17. Palacios-Callender M, Quintero M, Hollis VS, Roger J Springett, Salvador Moncada, et al. Endogenous NO regulates superoxide production at low oxygen concentrations by modifying the redox states of cytochrome C oxidase. Proc Matl Acad Sci USA. 2004; 101: 7630-7365.
18. Pizzino G, Irrera N, Cucinotta M, Giovanni Pallio, Federica Mannino, et al. Oxidative Stress: Harms and Benefits for Human Health. Oxid Med Cell Longev. 2017.
19. Sharma SK, Kharkwal GB, Sajo M, Ying-Ying Huang, Luis De Taboada, et al. Dose response effects of 810 nm laser light on mouse primary cortical neurons. Laser Surg Med. 2011; 43: 851-859.
20. Omar MTA, Shaheen AAM, Zofar H. A systematic review of the effect of low-level laser therapy on the management of breast cancer-related lymphedema. Support Care Cancer. 2012; 20: 2977-2984.
21. Stergioulas A. Low level laser treatment can reduce edema in second-degree ankle sprain. J Clin Las Med Surg. 2004; 22: 125-128.
22. Konstantinovic LM, Cutovic MR, Milovanovic AN, Stevan J Jovic, Aleksandra S Dragin, et al. Low-level laser therapy for acute neck pain with radiculopathy; a double-blind placebo-controlled randomized study. Pain Med. 2010; 11: 1169-1178.
23. Chen K-H, Hong C-Z, Hsu HC, Kuo FC, Hsieh YL. Electrophysiological effects of a therapeutic laser on myofascial trigger spots of rabbit skeletal muscles. Am J Phys Med Rehabil. 2008; 87: 1006-1014.
24. Smith K, Heckert R, Gerst H, Anders JJ, Byrnes KR, et al. Light promotes regeneration and functional recovery and alters the immune response after spinal cord injury. Laser Surg Med. 2005; 36: 171-185.
25. <https://veteriankey.com/diseases-of-the-joints/>
26. <https://www.banfield.com/Home/pet-health/State-of-pet-health>
27. Yeesuk Kim, Hyun-Cheol Oh, Jang Won Park, In-Sung Kim, Jun-Young Kim, et al, Diagnosis and Treatment of Inflammatory Joint Disease, Hip Pelvis. 2017; 29: 211-222.
28. Claire J Kwon, Cord M Brundage. Quantifying body surface temperature differences in canine coat types using infrared thermography, Journal of Thermal Biology. 2019; 82: 18-22.
29. Seltzer S. Acral lick granuloma: Stopping the itch-lick cycle, DVM360. 2019.
30. Kaimio M, Saijonmaa-Koulumies L and Laitinen-Vapaavuori O. Survey of otitis externa in American Cocker Spaniels in Finland, Acta Vet Scand. Published online. 2017; 59: 14.
31. Koch S. The Challenge of Chronic Otitis, in Dogs: From Diagnosis to Treatment. Issue Today's Veterinary Practice. 2022.
32. <https://face4pets.wordpress.com/2019/06/27/banfield-releases-2019-state-of-pet-health-report/>.
33. Dan G O'Neill, Andrea V Volk, Teresa Soares, David B Church, Dave C Brodbelt et al. Frequency and predisposing factors for canine otitis externa in the UK-a primary veterinary care epidemiological view. Canine Medicine and Genetics. 2021; 8: 7,.
34. Da Bin Lee, MedVet, Boaz Arzi. An Update on Feline Chronic Gingivostomatitis, Vet Clin North Am Small Anim Pract. 2020; 50: 973-982.
35. Shumaker AK. Diagnosis and Treatment of Canine Acral Lick Dermatitis, Vet Clin North Am Small Anim Pract. 2019; 49: 105-123.
36. Bartels, et al. Use of diode laser energy (808 nm) for selective photothermolysis of contaminated wounds. Photonics West. 1995.
37. Denerolle P, White SD, Taylor TS, Vandenabeele SI, Organic diseases mimicking acral lick dermatitis in six dogs, J Am Anim Hosp Assoc. 2007; 43: 215-220.
38. https://www.petmd.com/dog/general-health/evr_dg_acral_lick_granuloma_a_dermatology_nightmare.
39. ICM Lavrijsen, HCM Heuven, B Meij, LFH Theyse, RC Napa, et al. Prevalence and co-occurrence of hip dysplasia and elbow dysplasia in Dutch purebred dogs, Preventive Veterinary Medicine. 2014; 114: 114-122.