



Gonadal Outcome Following Testicular Tuberculosis: A Case Report and Review of the Literature

*Dibingue Clehaude; Abdi El Moustapha**; Al Affi Mahmoud; Gallouo Messian; Moataz Amine; Dakir Mohamed; Debbagh Adil; Aboutaieb Rachid

IBN Rochd Hospital Center Casablanca, Morocco.

***Corresponding Author(s): Abdi El Moustapha**

IBN Rochd Hospital Center Casablanca, Morocco.

Email: davecf05@hotmail.fr

Abstract

The WHO classifies urogenital tuberculosis as a severe type of TB that can be complicated by serious functional sequelae and occasionally necessitates surgical treatment. We provide a clinical case of a purulent right testicular TB melt managed by a right Orchidectomy and continued anti-tuberculosis medication, with a successful outcome (clinical and paraclinical with normal scrotal ultrasound as well as spermogram). In males, genital involvement can occur by the expansion of a urinary site via a retrograde ductal tract or through a haematogenous route. The most common sequelae of genital involvement is reduced fertility, seen as oligospermia or azoospermia. Because genital TB is an uncommon and severe type of tuberculosis, early and effective treatment is essential in order to preserve the male's reproductive function.

Received: Jan 01, 2021

Accepted: Jan 31, 2022

Published Online: Feb 04, 2022

Journal: Journal of Tuberculosis

Publisher: MedDocs Publishers LLC

Online edition: <http://meddocsonline.org/>

Copyright: © Moustapha AE (2022). *This Article is distributed under the terms of Creative Commons Attribution 4.0 International License*

Keywords: Tuberculosis; Testicle; Fertility.

Introduction

Extrapulmonary Tuberculosis (EPT) is a public health problem in Morocco, accounting for roughly 48 percent of all reported cases [1]. After lymph node, pleural, and osteoarticular involvement, the urogenital location is the fourth most prevalent in Europe and North America. It affects between 1.3 and 16.9 percent of cases of extrapulmonary tuberculosis [2]. Urogenital Involvement (TBUG) is frequently linked to disseminated tuberculosis infection. Almost 40% of patients with urogenital tuberculosis have active lung involvement. The WHO classifies TBUG as a severe type of tuberculosis, implying that it might be accompanied by serious functional sequelae, necessitating surgical therapy in certain cases.

We present a clinical case of a purulent right testicular melt in a patient being treated for pulmonary TB and in the second phase of antibacillary therapy, whose treatment included a right orchietomy with continuation of antitubercular treatment and a favourable outcome (both clinical and paraclinical with normal scrotal ultrasound as well as spermogram).

Observation

Patient MX, 28 years old, without profession, single, who was admitted for large painful right bursa with fever. He was one week into the second phase of anti-tuberculosis treatment (2 tablets of rifampicin and isoniazid combination) for pulmo-



Cite this article: Clehaude D, Moustapha AE, Mahmoud AA, Messian G, Amine M, et al. Gonadal Outcome Following Testicular Tuberculosis: A Case Report and Review of the Literature. *J Tuberc.* 2022; 5(1): 1029.

nary tuberculosis and had a notion of tuberculosis contagion in his family (older brother).

He had no particular medical or surgical history.

For 4 months, he had been presenting with progressive right testicular pain, associated with burning miction, pyuria and a fever of 38 °C, and a progressive right scrotal swelling. The patient was self-medicating with anti-inflammatory drugs.

The clinical examination noted good general condition, with a temperature of 37.5 °C, a large, red, oedematous, painful, fluctuating right bursa with Prehn's sign present and the right cremasteric reflex retained. The contralateral testis was normal and the peripheral lymph nodes were free.

Hyperleukocytosis was noted at 14500/mm³ with a predominance of neutrophils, C-reactive protein at 190 mg/l, HIV and hepatitis serologies as well as testicular tumour markers were negative.

Scrotal ultrasound with Doppler showed a swollen, enlarged right testicle with a hypoechoic, heterogeneous area occupying the lower half of the testicle, lobulated, measuring 45/16 mm, poorly vascularised and associated with a medium-sized, septate hydrocele (Figure 1).

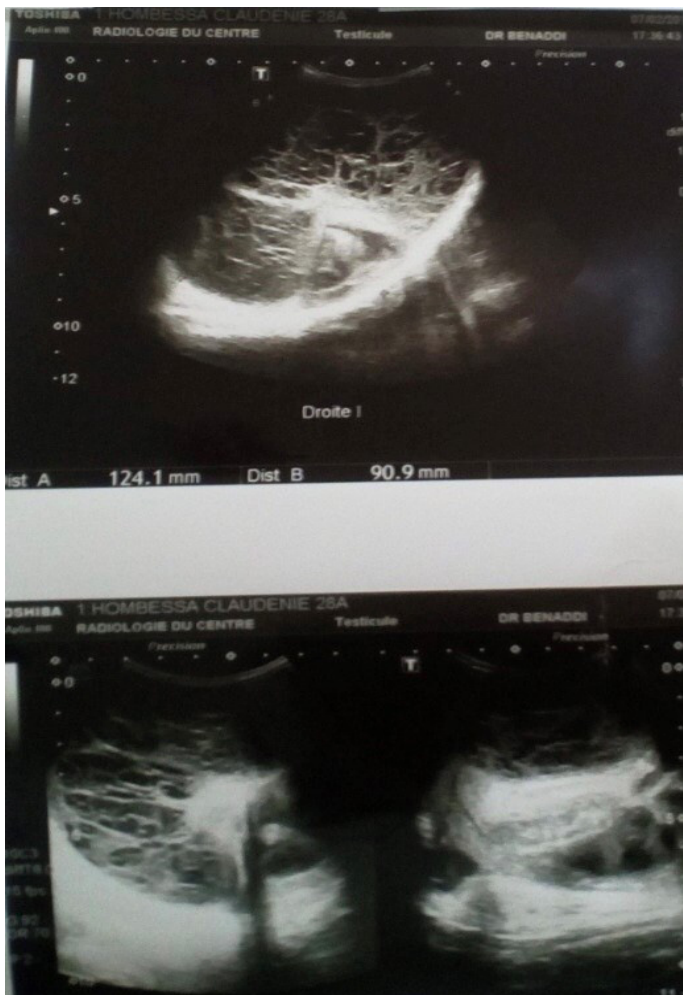

Figure 1: Scrotal ultrasound with Doppler showed a swollen, enlarged right testicle with a hypoechoic and heterogeneous.

A right scrototomy was performed, noting a multi-walled hydrocele with pus and an ischaemic testis with purulent contents and thickening of the vagina (Figure 2), followed by orchectomy and probabilistic antibiotic therapy (metronidazole 500 mgx³/d and ceftriaxone 1 g/d).

Histology of the surgical specimen showed epithelioid and gigante-cellular granulomas with caseous necrosis within the testicular parenchyma. Bacteriology showed the presence of mycobacterium tuberculosis after culture on Löwenstein-Jensen medium.

The patient was discharged at 2 days post-op; the evolution was satisfactory with a normal clinical and para-clinical examination (normal scarring of the scrotum, normal volume of the left testicle both clinically and on scrotal ultrasound with good vascularisation), a normal spermogram carried out at 3 months and a negative test for mycobacterium in the urine.

In the long term, he was seen again at 6 months and then one year with a favourable evolution. After six months of antituberculosis treatment, the patient was declared cured of bifocal tuberculosis.

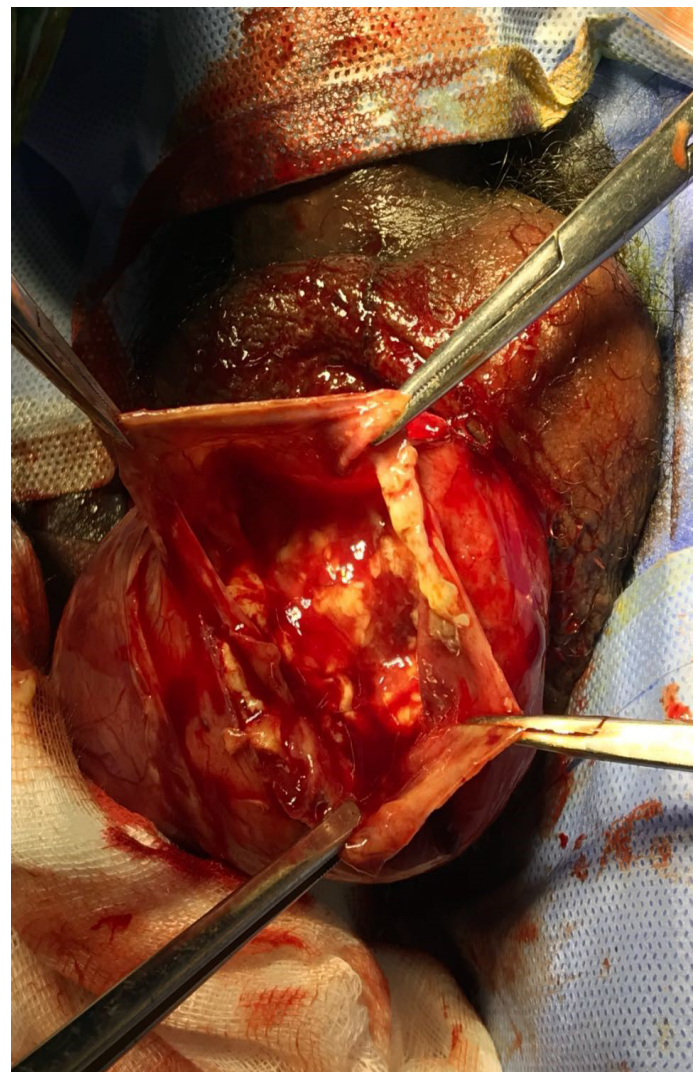


Figure 2: A right scrototomy, noting a multi-walled hydrocele with pus and an ischaemic testis with purulent contents and thickening of the vagina.

Discussion

Tuberculosis has been on the rise globally, particularly in developing countries, since the advent of HIV infection. It accounts for fewer than 5% of all human TBUGs [3]. Typically, urinary excretory tract abnormalities such as unilateral ureterohydronephrosis, ureteral stenosis, and a small bladder are present [4].

The average age of onset varies from 38 to 40 years. The disease develops preferentially in patients with a debilitating background [5].

In men, genital involvement can occur by extension of a urinary location via the retrograde ductal route or via the haematogenous route [3]. Testicular and prostatic involvement is more frequently accompanied by urinary tract involvement, unlike epididymal involvement, which is most often isolated [6]. In our patient, the unilateral nature of the lesion corresponds to the data in the literature. Only 10% of patients present bilateral orchiepididymitis in the series by GUEYE [5].

There are no specific clinical signs of genital tuberculosis. The picture is often that of a chronic orchiepididymitis evolving in a context of little pain except in the case of superinfection. Thus, the lack of response to non-specific antibiotic treatment or an incomplete response (in the case of superinfection) often points to the diagnosis of genital tuberculosis [7].

In our presentation, it is important to note the history of pulmonary tuberculosis, the progressive evolution and the resistance to outpatient treatment, which mainly points to a secondary location of genital tuberculosis.

Bacteriological examinations are of variable interest and effectiveness. As in the case of urinary tuberculosis, the main bacteriological examination is the ECBU in search of mycobacteria. Other samples can be taken (sperm culture) but are not very conclusive. The abnormalities found, such as leukospermia or oligospermia and a decrease in the volume of the ejaculate, remain aspecific [3]. In our patient, the bacteriological study noted the presence of mycobacterium tuberculosis after culture on Löwenstein-Jensen medium.

Although the ultrasound abnormalities are aspecific, testicular analysis may show homogeneous hypoechoic areas of the testicle associated with a hydrocele [8]. In our case, scrotal ultrasound coupled with Colour Doppler showed an enlarged right testicle with a hypoechoic, heterogeneous area occupying the lower half of the testicle, lobulated and measuring 45/16 mm, with little vascularity. A differential diagnosis including a testicular tumour cannot be ruled out hence the need to request tumour markers.

The medical treatment is the same as for urinary forms and includes quadritherapy and then dual therapy for a total of six months. However, surgery may be considered in case of fistula or purulent melting of the testicle [8]. After six months of anti-tuberculosis treatment, the patient was declared cured of bifocal tuberculosis.

The main sequelae of genital involvement is impaired fertility in the form of oligospermia or azoospermia due to reversible or irreversible organic damage to the genitalia. Infertility is predominantly excretory, due to seminal tract obstruction and rarely secretory secondary to bilateral testicular melting [9]. In our patient, the spermogram was normal, whereas the sequelae of this form of tuberculosis are functional.

Conclusion

To summarise, vaginal TB is an uncommon condition that is frequently a secondary focus of disseminated tuberculosis. Because of the functional complications it produces, it remains a severe type of TB, thus early and adequate treatment is necessary in order to preserve male reproductive function.

References

1. WHO, Global Tuberculosis Control Report. 2017.
2. European Centre for Disease Prevention and Control/WHO Regional Office for Europe. Tuberculosis surveillance and monitoring in Europe. Stockholm: ECDC. 2015.
3. Chandra S, Chandra H, Chauhan N, Gaur DS, Gupta H, et al. Male genitourinary tuberculosis-13 years' experience at a tertiary care center in India. *Southeast Asian J Trop Med Public Health*. 2012; 43: 364-369.
4. Figueiredo AA, Lucon AM, Junior RF, Srougi M. Epidemiology of urogenital tuberculosis worldwide. *Int J Urol*. 2008; 15: 827-832.
5. Richard Mallet, Marc Mouzin, Xavier Gamé, Frédéric Braud, Pascal Rischmann, et al. Acute epididymitis indicative of tertiary tuberculosis. *Progress in Urology*. 2001; 11: 542-545.
6. Jacob JT, Nguyen TML, Ray SM. Male genital tuberculosis. *Lancet Infect Dis*. 2008; 8: 335-342
7. M Ouedraogo, K Boncounou, SM Ouedraogo, S Hien, YJ Drabo. Epididymo-Testicular Tuberculosis: A Case Report. *Medicine of Africa*. 2001.
8. A Fillion, N Koutlidis, A Froissart, B Fantind. Investigation and management of genito-urinary tuberculosis. 2014: 6.
9. Al-Ghazo MA, Bani-Hani KE, Amarin ZO. Tuberculous epididymitis fertility in North Jordan. *Saudi Med J*. 2005; 26: 1212-1215.