



A Case of a 70year Old Operates with Severely Calcified Sinus of Valsalva Aneurysm: Did we Judge it Correctly in the First Place and Did we React Properly in a Rapidly Worsening Situation

Aysun Tulun*; Johannes M Albes

Department of Cardiac- and Vascular Surgery, Heart Center Brandenburg, University Hospital Brandenburg Medical School, Faculty of Health Sciences Brandenburg.

*Corresponding Author(s): Aysun Tulun

Department of Cardiac- and Vascular Surgery, Heart Center Brandenburg, University Hospital Brandenburg Medical School, Faculty of Health Sciences Brandenburg, Ladeburger Strasse 17, 16321 Bernau, Germany.
Tel: +49-3338-694510 & +49-3338-694544;
Email: tulun.aysun@immanuelalbertinen.de

Abstract

Surgery for a severely calcified sinus of Valsalva aneurysm can be challenging. We present a patient in whom a simplified approach did not suffice so that implantation of a composite graft was required combined with individual grafts to the coronary ostia instead of direct re-insertion into the prosthesis because of the high calcification load.

Received: Feb 09, 2024

Accepted: Mar 07, 2024

Published Online: Mar 14, 2024

Journal: Journal of Surgery Case Reports

Publisher: MedDocs Publishers LLC

Online edition: <http://meddocsonline.org/>

Copyright: © Tulun A (2024). *This Article is distributed under the terms of Creative Commons Attribution 4.0 International License*

Keywords: Aortic Surgery; Aneurysm; Sinus valsalva; Aortic root; Cabrol-Prosthesis.

Introduction

Surgery of the aortic root can be demanding. Despite elaborate preoperative diagnostics and planning the real situation can afford a complete shift of strategy. We describe a case of a patient with a severely calcified aortic root, who underwent surgery starting with a simple approach in order to reduce risk and surgical burden but who ended up with major surgery with some elements serving as a bail-out in an otherwise potentially deleterious situation.

Case presentation

A 70-year-old man presented with a large, calcified sinus of Valsalva aneurysm of the right ostial sinus and grade III aortic valve insufficiency. The preoperative CT confirmed the heavily calcified aneurysm. Coronary angiography revealed a very narrow, almost tiny right ostium, but otherwise no relevant stenosis. The indication for resection and aortic valve repair or replacement was given. The patient was operated on under moderate hypothermia. After x clamping and onset of cardiac



Cite this article: Tulun A, Albes J M. A Case of a 70year Old Operates with Severely Calcified Sinus of Valsalva Aneurysm: Did we Judge it Correctly in the First Place and Did we React Properly in a Rapidly Worsening Situation. *J Surg Case Rep.* 2024; 2(1); 1004.

arrest, the aorta was opened. The cusps of the aortic valve were already partially fibrotic. The cusps attached to the non-coronary/left coronary commissure showed a large defect. Reconstruction was therefore impossible. The aneurysm was heavily calcified and had large clots that had grown into the right ventricular/right ventricular wall. The right coronary ostium was so heavily calcified that it appeared porcelain-like. The left ostium was large but also heavily calcified. The usual procedure of primary implantation of the ostium into a valve-bearing conduit was therefore considered unsuitable at first glance. It was decided to avoid all possible negative consequences of dealing with these calcifications and simply not touch them instead. The valve was replaced with a 25 mm biological prosthesis. The aneurysm was reduced in size with mattress sutures and running sutures, utilizing those areas only moderately affected by calcifications. The paper-thin aorta was replaced with a 32 mm supracommissural prosthesis. The patient was successfully weaned from the ECC. However, a growing hematoma in the area of the right ventricle and the right atrial appendage appeared. TEE showed a peculiar paravalvular leakage and a large hematoma between the sinus and the adjacent right ventricular and right atrial structures while already protruding into the left atrial wall. While the cannulas were still in place, the aorta was clamped again and cardioplegia was administered. The patient was cooled down to 30° C. The aortic prosthesis was then detached from the commissural level of the aorta. The valve was inspected but showed no signs of a defect. The reduced sinus appeared to be intact. The biological prosthesis was removed and the situs inspected. The reduction plasty of the sinus was reopened. No specific defects were found. Nevertheless, it was now decided to implant a composite graft. Cardioplegia was administered intermittently via the ostia. However, application into the right ostium was only possible with the tip of the smallest of all available cannulas. Due to the ostial calcifications, it was decided to attach the left ostium to a 6 mm Dacron prosthesis and not to insert it into the main body of the prosthesis as usual. An end-to-end anastomosis with a Prolene 5-0 running suture was created. Blood cardioplegia was administered via this graft. Several additional sutures were required in some places to achieve a tight and therefore dry anastomosis. The right ostium was trimmed to remove the porcelain-like calcifications. A tiny stump of the right coronary artery then remained. In the meantime, a saphenous vein graft had been harvested, which was now used to create an end-to-end anastomosis to the right coronary artery stump with Prolene 7-0 running suture. Cardioplegia was then also administered via this graft. The prosthetic ring of a 23-mm bioprosthetic valve was attached to a 26-mm Dacron prosthesis, which served as a composite graft. The composite graft was implanted into the native annulus with 18 reinforced U-sutures and sutured in the usual manner. The previously implanted prosthesis was cut back until only a 1 cm wide segment remained distally. The main body of the composite graft was shortened and connected to the short remaining segment of the previously implanted prosthesis. The prosthesis-prosthesis anastomosis was performed with Prolene 5-0 running suture. The main body prosthesis was then de-aired and the X-clamp released. The main body was then clamped off laterally and incised. The prosthesis for the left coronary artery was placed on the right side in a spiral from back to top, shortened and anastomosed to the main body. The graft was de-aired and the lateral clamp removed. This graft was then clamped laterally, incised and the vein graft was shortened and securely anastomosed to the graft using Prolene 6-0. All vessels were de-aired again and the lateral clamp was removed. During

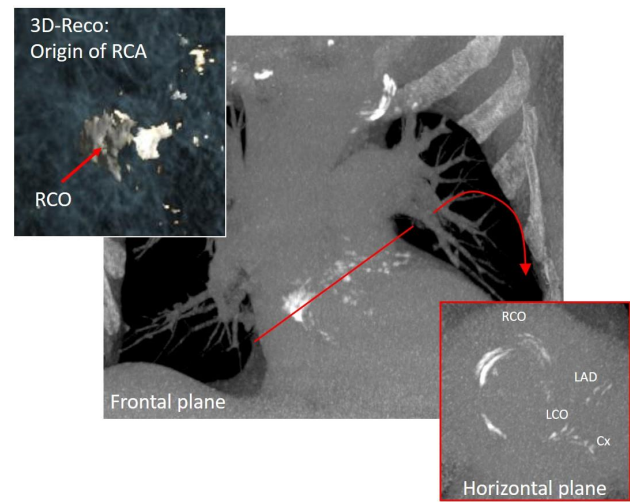


Figure 1: Preoperative 3d-CT reconstruction showing the severely calcified aortic root and coronary arteries.

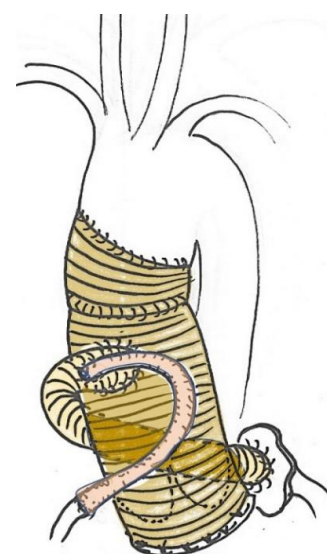


Figure 2: Artist's drawing of the intraoperative situation after completion of all steps. Note the 6 mm graft for the large left coronary ostium coming from the dorsal side and running diagonally cranially to the right anterior side of the main body. Also note the vein graft attached to the tiny right coronary artery after resection of the calcified ostium (see also Figure 1, left upper insert) and connected to LCO graft.

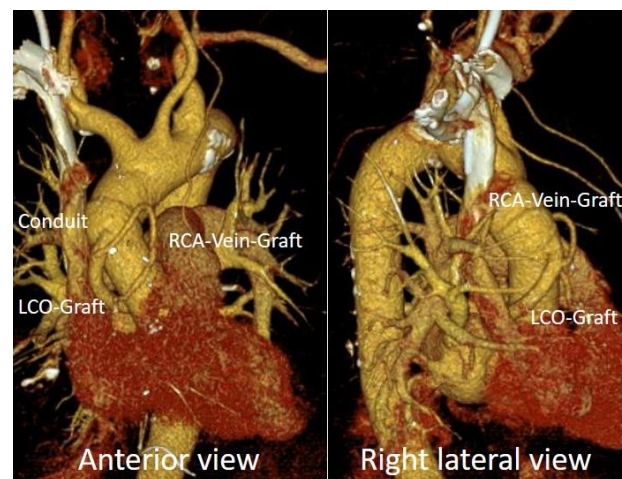


Figure 3: Postoperative 3D CT reconstruction. Note the prosthetic graft for the large left main coronary ostium and the small caliber vein graft for the corresponding small right coronary artery after resection of the right coronary ostium.

reperfusion, temporary pacing wires were attached to the right ventricle and right atrium. Prolonged reperfusion and rewarming were initiated. The patient was then weaned from the ECC. Echocardiography showed regular valve function. There were no new hematomas in the periaortic area. Protamine, blood and blood products were administered and prolonged surgical hemostasis was performed. All prostheses and the vein graft were irrigated with bacitracin/neomycin and then sprayed with a generous layer of autologous fibrin glue. After the site had dried, the sternum was closed with wires and subcutaneous and skin closure was performed. The patient was transferred to the intensive care unit. He was extubated on the second postoperative day. After 3 days on the ICU he was transferred to the intermediate care ward. Non-infectious instability of the sternum necessitated rewiring on the 6th postoperative day. The patient was then transferred to the normal ward. The further course was unremarkable. A unilateral pleural effusion was drained. The patient was discharged on the 18th postoperative day and is regularly seen in our outpatient clinic for follow-up care.

Comment

In non-routine scenarios, decision-making is always a challenge. Less is more is very often a wise approach, but not always. In this case, we were faced with a potentially fatal complication that occurred after such a “less is more” decision. Although the actual defect causing the growing hematoma could not be found, it was clear that it must have originated from the wall of the Valsalva aneurysm sinus [1]. The situation could only be successfully resolved by completely separating this area from the blood flow. However, the calcified ostia made a typical Bentall procedure risky and, in the case of the right ostium, downright impossible. The right ostium could not be mobilized and was far too small for implantation into the prosthesis. In contrast, the button of the dominant left ostium had a high calcification load. So, it was quite possible that a typical anastomosis to the main body of the prosthesis would have led to leakage, which would have been very complicated to treat after connecting the main body of the prosthesis to the cuff of the previously implanted prosthesis. The prosthesis offers a way out of this dilemma [2,3]. Thanks to the direct connection of both ostia, intermittent cardioplegia was possible without additional maneuvering. Alternatively, conventional vein grafts could have been implanted after closure of both ostia. However, a further region would have been involved, which could have led to potential bleeding problems, especially in view of the already long extracorporeal

perfusion time. In addition, 6 anastomoses would have been required, 3 distal and 3 proximal anastomoses to the prosthesis or to another vein graft instead of only 4. The prosthesis was rinsed with bacitracin/neomycin and then sprayed with autologous fibrin glue to create a bactericidal environment and thus avoid possible graft infection due to the very long operation time of 11 hours. However, there is no study that proves a specific benefit for the ascending aorta and the aortic arch [4-6].

Conclusion

“Good judgement comes from experience, experience comes from bad judgement”. Fortunately, we did not dare to react to the growing hematoma with another “small” approach and found an adequate rescue strategy intraoperatively to save the patient’s life. Direct ostial anastomoses can be performed tightly with absolute certainty, as they can be tested repeatedly with blood cardioplegia until complete tightness is achieved. In this way, bad surprises i.e. problematic areas that could require re X-clamping or significant blood loss can be avoided.

References

1. Deng Z, Liu Q, Liu H, Yuan J, Li J. Right sinus of Valsalva aneurysm rupture into the right ventricle in a rare cardiovascular case of syphilis. *Arch Med Sci.* 2023; 19(6): 1920-1922. doi: 10.5114/aoms/172098. PMID: 38058708; PMCID: PMC10696954.
2. Gelsomino S, Frassani R, Da P, Morocutti G, Masullo G, et al. The Annals of Thoracic Surgery. 2003; 75 (1): 126-131. doi: 10.1016/S0003-4975(02)04284-4.
3. Bachet J, Termignon JL, Goudot B, Dreyfus G, Piquois A, et al. Aortic root replacement with a composite graft. Factors influencing immediate and long-term results. *Eur J Cardiothorac Surg.* 1996; 10(3): 207-13. doi: 10.1016/s1010-7940(96)80298-3. PMID: 8664022.
4. Ricco JB, Assadian O. Antimicrobial silver grafts for prevention and treatment of vascular graft infection. *Semin Vasc Surg.* 2011; 24(4): 234-41. doi: 10.1053/j.semvascsurg.2011.10.006. PMID: 22230679.
5. Lew W, Moore W. Antibiotic-impregnated grafts for aortic reconstruction. *Semin Vasc Surg.* 2011; 24(4): 211-9. doi: 10.1053/j.semvascsurg.2011.10.015. PMID: 22230676.
6. Ostovar R, Albes JM. Unfortunate Accidental Twins: Two Patients with Endocarditis of a Valve-Bearing Conduit. *Thorac Cardiovasc Surg Rep.* 2023; 12(1): e44-e47. doi: 10.1055/s-0043-1770722. PMID: 37434778; PMCID: PMC10332900.