



# Study of Common Artifacts of Myocardial Perfusion Scan in Patients with Chronic Renal Failure and Liver Cirrhosis in Nuclear Medicine Ward of Namazi Hospital in 2019

Hossein Akbarialiabad<sup>1</sup>; Sepideh Hesami<sup>1</sup>; Seyed Alihossein Zahrayi<sup>1</sup>; Masoud Vafabin<sup>2</sup>; Farshid Gheisari<sup>3\*</sup>

<sup>1</sup>Student Research Committee, School of Medicine, Shiraz University of Medical Sciences, Shiraz, Iran

<sup>2</sup>Department of general surgery, Shiraz University of medical sciences, Shiraz medical school, Shiraz, Iran

<sup>3</sup>Nuclear Medicine Department, School of Medicine, Imam Hossein Square, Shiraz, Iran

**\*Corresponding Author(s): Farshid Gheisari**

Nuclear Medicine Department, School of Medicine,  
Imam Hossein Square, Shiraz, Iran

Tel: +98 916 301 1224; Email: fgheisari@gmail.com

Received: Jun 15, 2020

Accepted: Jul 17, 2020

Published Online: Jul 23, 2020

Journal: Journal of Radiology and Medical Imaging

Publisher: MedDocs Publishers LLC

Online edition: <http://meddocsonline.org/>

Copyright: © Gheisari F (2020). *This Article is distributed under the terms of Creative Commons Attribution 4.0 International License*

**Keywords:** Myocardial perfusion imaging; Liver cirrhosis; End-stage renal disease.

## Abstract

**Background and objective:** Myocardial Perfusion Imaging (MPI) is one of the successful techniques for the diagnosis of cardiovascular disease in both developing and developed countries. In this imaging technique, like other imaging techniques, there is the possibility of error and unintended side effects such as artifacts that can be associated with the device, user, and patient factors. Our study aims to assess the prevalence of artifacts in myocardial perfusion scans in patients with chronic renal failure and liver cirrhosis.

**Methods:** In a cross-sectional study in 2019, 90 male patients aged 45-65 years, who were referred to the Nuclear Medicine Department of Namazi Hospital, were divided into three groups of 30. Thirty patients with chronic renal disease, 30 patients with liver cirrhosis, who were a candidate for transplantation, and the control group was considered as the third group. Anterolateral, septal, and infarct artifacts were evaluated in all three groups and were documented by a nuclear medicine specialist.

**Results:** In this study, 20 (22.2%) of the patients who had a septal cardiac perfusion scan had artifacts, including 14 (46.7%) patients with chronic kidney disease, Four patients (13.3%) had liver cirrhosis and 2 (6.7%) controls. The prevalence of artifact prevalence in anterolateral cardiac perfusion scan was 22 (24.4%), including (20%) 6 patients with liver cirrhosis and 14 patients (46.7%) with chronic kidney disease and also two patients (6.7%) were in the control group. The frequency of inferior cardiac perfusion scan artifacts was 30 (33.3%), which included 18 patients (60%) with liver cirrhosis and four controls (13.3%), while the prevalence of artifacts in patients with chronic kidney disease was 8 (26.6%).



**Cite this article:** Akbarialiabad H, Hesami S, Zahrayi S A, Vafabin M, Gheisari F. Study of Common Artifacts of Myocardial Perfusion Scan in Patients with Chronic Renal Failure and Liver Cirrhosis in Nuclear Medicine Ward of Namazi Hospital in 2019. *J Radiol Med Imaging*. 2020; 3(1); 1032.

**Conclusion:** The results of the present study indicate that artifacts may be present in myocardial perfusion imaging in patients with dialysis-dependent renal failure as well as in advanced liver disease such as cirrhosis. These can interfere with the interpretation of the obtained images.

## Introduction

Cardiovascular disease is widely known as one of the most common diseases in developing and developed countries. In 2002, the American Heart Association reported 62 million Americans with cardiovascular disease, of which 32 million were women, and 30 million were men [1].

Besides, the damage caused by absenteeism and injury to the economy is very severe. Regardless of economic issues, the disease also has social and health consequences worldwide [2].

Given these issues, serious research on secondary prevention is an essential measure and has not yet been undertaken in research. There is no doubt that the first important step in the second level prevention is screening and recognizing the patients before severe disabilities occur [3].

Chronic renal failure (CKD) is a progressive and irreversible destruction of kidney function due to environmental and genetic causes [4,5]. The primary cause of CKD in adults is diabetic nephropathy and hypertension, whereas in children with CKD, hereditary, or congenital kidney disorders account for about 70-60% [5]. Due to a decrease in glomerular filtration rate, nephrons lose their function, resulting in the accumulation of metabolic waste products, disrupting the electrolyte balance, and consequently altering the body's normal hemostasis [4]. In patients with end-stage renal failure, cardiovascular diseases are the primary cause of death, which accounts for approximately 50% of deaths in patients undergoing chronic dialysis [4].

No ideal method for screening for cardiovascular disease has been recommended in high-risk patients. Currently, ESRD patients who are candidates for renal transplantation undergo cardiovascular disease screening by the noninvasive cardiac tests. If there is a disturbance in these studies' results, they are candidates for a more careful examination with invasive angiography [6].

Non-invasive tests have limitations, such as exercise testing due to ECG changes during rest in 25 to 30% of patients, lack of tachycardia (due to autonomic neuropathy) during testing, or more commonly due to decreased ability of mobility is limited [7].

The use of a myocardial perfusion scan with dipyridamole has been limited due to low positive predictive value (71%) [8]. Stress echocardiography has a sensitivity of 69% to 95% and specificity of 95% and is the preferred method compared to other non-invasive methods. However, the rate of transient AF rhythm in this method is 1 to 2%, which should be considered [9].

In identifying the risk of cardiac events, the use of a myocardial perfusion scan avoids unnecessary additional costs [10]. In a study by Hannoush et al., Positive predictive value for the scan was 91% and negative predictive value for 86% [11]. In other studies, myocardial perfusion scan sensitivity was 94%, specific-

ity was 94%, positive predictive value was 96%, and the negative predictive value was 92% [12,13].

Given that the use of myocardial perfusion scan detection in Iran has increased in recent years, based on Gholam Rezanjad et al., The criteria for patient referrals for scanning have been evaluated as appropriate.

In myocardial perfusion scan, the patient is scanned, with the radio isotopes, and then subjected to stress scan by drug injection or physical activity on the same day or the other day depending on the protocol performed at the respective center. The results of the two scans are compared, and the regional myocardial perfusion defect and associated vessels are identified [14]. One of the problems that may occur is due to technical factors; for example, the presence of large or dense breasts in women interferes with the interpretation of the hearts anterior and anterior wall defects. Also, the activity under the diaphragm interferes with the interpretation of the defects of the inferior wall of the heart [15]. Drugs labeled with Technetium-99m in cardiac scan profiles like tetrofosmin, sestamibi is mainly secreted through the hepatobiliary system [16,17]. Following this secretion of the gastrointestinal tract adjacent to the myocardium, it is exposed to a radioactive activity capable of producing artifacts in the resulting images [18,19].

Burrell et al. Acknowledged that myocardial perfusion imaging (myocardial perfusion scanning) is an important imaging technique in managing cardiovascular disease patients. Myocardial perfusion scanning plays a crucial role in the diagnosis of cardiovascular disease, the prognosis, the evaluation of the effectiveness of treatment, and the assessment of the viability. However, myocardial perfusion scanning is a complex process, with a variety of artifacts and problems that can limit its clinical utility. These factors may be related to the patient (including unique aspects of the patient's heart), nuclear medical equipment, or technician actions [15].

In Loghin et al.'s study, it was found that lesions recorded in cardiac perfusion imaging images are common and cause artificial defects predicted by diaphragm transition, body mass index, and heart size. Multiple imaging sequences and visual optimization, computation of neutral imaging depth and diffusion, substantially reduce artifacts to identify mild perfusion defects of coronary atherosclerosis that are detectable as a basis for severe lifestyle and pharmacological treatment [20].

## Materials and Methods

### Type of Study

A cross-sectional study was performed in the nuclear medicine department of Namazi Hospital affiliated to Shiraz University of Medical Sciences.

### Population understudy and sample size

The study population included all those referred to the Nuclear Medicine Department of Namazi Hospital of Shiraz for the cardiac perfusion scans. The sample size consisted of 90 patients divided into three groups of 30 each.

### Inclusion criteria

Male subjects ranging in age from 45 to 65 years were willing to participate in the study. After consent was obtained, healthy subjects, as well as chronic renal disease patients with liver cirrhosis, participated in this study.

**Exclusion criteria**

Exclusion criteria included females and persons younger than 45 years and over 65 and those without chronic kidney disease or liver cirrhosis.

**Method of Study**

Subjects in this study were divided into three groups of 30 patients, one group consisting of patients with chronic renal disease, the second group of patients with liver cirrhosis that were candidates for transplantation, and the third group of patients was patients requiring cardiac perfusion scan without any renal and hepatic problems. The last group was considered as a control group. Individual characteristics, scan results, and echocardiography of all three groups were recorded in the questionnaire. After a nuclear perfusion scan, septal, anterolateral, and inferior artifacts were evaluated in all three groups, and all documented by Nuclear Medicine Specialist.

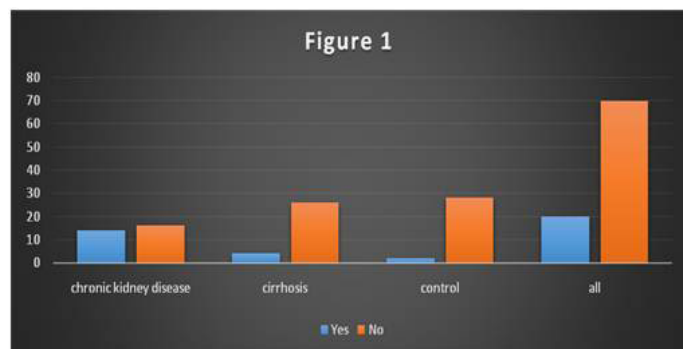
**Statistical analysis of findings**

Statistical analysis was performed using SPSS software (version 22). The findings of this study were expressed as absolute frequency (number) and relative frequency (percentage) as frequency and percentage. The parametric data of this research were evaluated using a T-test, and the nonparametric data were compared statistically using the Chi-square test. In this study, the difference with P-value less than or equal to 0.05 was considered statistically significant.

**Results**

In this study, 90 male subjects, ranging from 45 to 65, with a mean age of  $53 \pm 3.3$ , were studied to determine the prevalence of cardiac perfusion scan artifacts. This study included 30 people with chronic kidney disease, 30 people with liver cirrhosis, and 30 healthy people with kidney and liver disease as the control group. In the present study, all patients were evaluated for the prevalence of cardiac perfusion scan artifacts by Septal, Anterolateral, and Inferior methods.

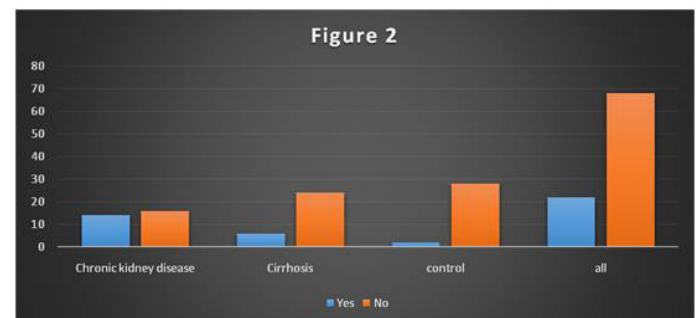
Overall, 20 (22.2%) of the artifacts were found in all patients who underwent septal cardiac perfusion, with 14 out of 30 patients (46.7%) with chronic kidney disease. The artifact was found in 4 (13.3%) of patients with liver cirrhosis. The prevalence of septal cardiac perfusion scans in the control group was 2 (6.7%) (Figure 1).



**Figure 1:** Frequency of septal cardiac perfusion artifact scans in patients with liver cirrhosis and chronic kidney disease.

Statistical analysis showed that there was a significant difference in the prevalence of septal cardiac perfusion scintigraphy among patients with cirrhosis, chronic kidney disease, and control group ( $p = 0.00$ ).

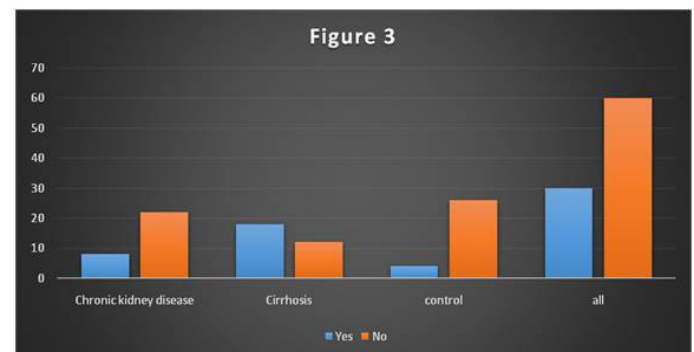
In the present study, the prevalence of artifacts in the anterolateral cardiac perfusion scan was investigated. In a total of 90 patients, 22 (24.4%) had artifacts. The frequency of cardiac perfusion scan artifacts in patients with liver cirrhosis was 6 (20%) and in patients with chronic kidney disease was 14 (46.7%). In the control group, two patients (6.7%) had anterolateral cardiac perfusion artifacts (Figure 2).



**Figure 2:** Frequency of anterolateral cardiac perfusion scan artifact prevalence in patients with liver cirrhosis and chronic kidney disease.

Statistical analysis showed that there was a significant difference in the prevalence of anterolateral cardiac perfusion scans among patients with cirrhosis, chronic kidney disease, and control group ( $p = 0.00$ ).

This study also investigated the prevalence and frequency of inferior cardiac perfusion scans in patients with liver cirrhosis, patients with the chronic renal disease compared to the control groups. In a total of 90 patients, the frequency of artifacts was 30 (33%). The frequency of cardiac perfusion scan artifacts in patients with liver cirrhosis was 18 (60%) and in patients with chronic kidney disease was 8 (26.6%). In the control group, two patients (6.7%) had inferior cardiac perfusion artifacts (Figure 3).



**Figure 3:** Frequency of inferior cardiac perfusion scanning artifact prevalence in patients with liver cirrhosis and chronic kidney disease.

Statistical analysis showed that the prevalence of inferior cardiac perfusion scintigraphy was significantly different between patients with cirrhosis, chronic kidney disease, and control group ( $p = 0.00$ ).

**Discussion**

Myocardial perfusion scan at rest and with drug stress identifies flow-limiting coronary artery stenosis as a regional perfusion defect [21,22]. Myocardial perfusion scans also show a mild decrease in blood flow storage (coronary arteries), indicating non-obstructive coronary artery disease as a basis for long-term treatment before significant stenosis [23,24]. Early detection of

cardiovascular disease using myocardial perfusion imaging requires accurate and artifact-free differentiation [25,26]. However, some patient-related factors and imaging modalities may cause false positives and artificial abnormalities in myocardial perfusion scan images [27,29].

Various causes and factors can compromise myocardial perfusion scanning. These factors may be patient-related, equipment, or technician, as mentioned. Both the technician and the physician need to be aware of these potential error sources, take steps to limit them, correct them if possible, and if they cannot be eliminated, the interpreter should be aware of the potential impacts of artifacts on images.

In the present study, the incidence of septal, anterolateral, and inferior cardiac perfusion scans concerning chronic kidney disease and liver cirrhosis, was estimated to be 26.6% on average.

In this study, the incidence of artifact incidence in patients who underwent septal cardiac perfusion scan was 22.2%. The observations showed that the incidence of artifact incidence in patients with chronic kidney disease was significantly higher than those with liver cirrhosis and healthy subjects.

Dasselaar et al [30]. showed that hemodialysis causes a severe decrease in myocardial blood flow. Because myocardial blood flow decreases early in the hemodialysis period, not only hypovolemia but also acute dialysis-related factors are also involved in artifacts. Decreased hemodialysis-dependent myocardial blood flow may lead to cardiac problems in dialysis patients.

Patients with renal disease often have coronary artery disease, as well. In these patients, the 5-year survival rate is less than 50%, and cardiovascular disease accounts for nearly half of all deaths in end-stage renal disease patients. Renal disease is often caused by hypertension or diabetes, both of which are essential risk factors for cardiovascular disease. Other patients develop hypertension after the onset of kidney disease. These comorbidities partly contribute to the increased prevalence of the cardiovascular disease in the renal patient [31].

Havel et al [32]. also found that the combined evaluation of myocardial perfusion imaging and coronary artery calcium could help determine prognosis in end-stage renal disease. In contrast, severe perfusion abnormalities in the SPET-gate and CAC score 1000 is predictive of the successive heart events. That study also suggests artifacts in myocardial perfusion imaging in patients with advanced kidney disease that can be compensated by adjuvant techniques.

The present study also investigated the frequency of Inferior cardiac perfusion scan artifacts in patients with liver cirrhosis and those with the chronic renal disease compared to control groups. In general, the frequency of Inferior cardiac perfusion scan artifacts was 33.3%. In patients with chronic kidney disease, 26.6% of artifacts were observed in inferior cardiac perfusion scans. Whereas the frequency was 60% of patients with liver cirrhosis, it was significantly higher in the control group and patients with chronic disease.

The prevalence of artifacts in the anterolateral cardiac perfusion scan was 24.4%, with the highest prevalence in patients with chronic kidney disease (46.7%). However, the frequency of cardiac perfusion scan artifacts in patients with cirrhosis was 20% and in the control group was 6.7%, which was statistically

significant ( $p < 0.05$ ).

Zoghbi et al. [33] also found in a study of the usefulness of preoperative myocardial perfusion imaging in predicting prognosis after liver transplantation that myocardial perfusion imaging could reveal unique findings such as ascites and spleen, which can produce artifacts and may interfere with accurate image interpretation. Their study, consistent with the current study, showed artifacts in myocardial perfusion imaging in patients with liver transplant candidates such as cirrhosis.

Davidson et al. [34] also found that stress myocardial perfusion imaging has poor predictive value for coronary artery disease in liver transplant candidates. Coronary angiography has a primary screening role for this population, especially in patients with multiple cardiac risk factors or a known history of coronary artery disease.

A study also found that the progression of renal failure and poor cardiac perfusion imaging in patients with advanced cirrhosis and ascites may be related to systolic cardiac dysfunction [35].

One of the strengths of this study is the significant sample size of patients undergoing liver cirrhosis as well as dialysis-dependent patients with chronic kidney disease, which has helped enrich the study and strengthen the results. In the present study, we investigated the efficacy of artifacts in cardiac perfusion imaging in patients using Inferior, Anterolateral and Septal techniques and the association of each of these techniques with the aforementioned liver and kidney diseases.

### Limitations

The limitations of the present study are the lack of evaluation of cardiac perfusion imaging artifacts in female patients with liver cirrhosis and chronic kidney disease compared to men. Other limitations of this study are the lack of determination of the type of artifact and its association with these diseases.

### Conclusion

The results of the present study indicate that artifacts may be present in myocardial perfusion imaging in patients with dialysis-dependent advanced renal failure as well as in advanced liver disease such as cirrhosis, and these artifacts may interfere with the interpretation of the resulting images.

### References

1. Gregoratos G, Abrams J, Epstein AE, Freedman RA, Hayes DL, et al. ACC/AHA/NASPE 2002 guideline update for implantation of cardiac pacemakers and antiarrhythmia devices-summary article: a report of the American College of Cardiology/American Heart Association Task Force on Practice Guidelines (ACC/AHA/NASPE Committee to Update the 1998 Pacemaker Guidelines). *Journal of the American College of Cardiology*. 2002; 40: 1703-1719.
2. Ginter E. Prevention of cardiovascular diseases: the Finnish experience and current situation. *Bratislavské lékařské listy*. 1997; 98: 67-72.
3. Yusuf S, Reddy S, Ôunpuu S, Anand S. Global burden of cardiovascular diseases: Part I: General considerations, the epidemiologic transition, risk factors, and impact of urbanization. *Circulation*. 2001; 104: 2746-2753.
4. Webster AC, Nagler EV, Morton RL, Masson P. Chronic kidney disease. *The Lancet*. 2017; 389: 1238-1252.

5. Hill NR, Fatoba ST, Oke JL, Hirst JA, O'Callaghan CA, et al. Global prevalence of chronic kidney disease—A systematic review and meta-analysis. *PloS one*. 2016; 11: e0158765.
6. Chen J, Budoff MJ, Reilly MP, Yang W, Rosas SE, et al. Coronary artery calcification and risk of cardiovascular disease and death among patients with chronic kidney disease. *JAMA cardiology*. 2017; 2: 635-643.
7. Di Lullo L, Rivera R, Barbera V, Bellasi A, Cozzolino M, et al. Sudden cardiac death and chronic kidney disease: from pathophysiology to treatment strategies. *International journal of cardiology*. 2016; 217: 16-27.
8. Johnson NP, Gould KL. Regadenoson versus dipyridamole hyperventilation for cardiac PET imaging. *JACC: Cardiovascular Imaging*. 2015; 8: 438-447.
9. Pham MT, Nguyen NV, Hoang VM, Nguyen NL. *Stress Electrocardiogram Instrumentation: Principles and Structure*. 2016.
10. errington de Gonzalez A, Kim K-P, Smith-Bindman R, McAreavey D. Myocardial perfusion scans: projected population cancer risks from current levels of use in the United States. *Circulation*. 2010; 122: 2403-2410.
11. Sachdev V, Hannoush H, Sidenko S, Saba SG, Sears-Rogan P, et al. Are echocardiography and CMR really discordant in mitral regurgitation? *JACC: Cardiovascular Imaging*. 2017; 10: 823-824.
12. de Jong MC, Genders TS, van Geuns R-J, Moelker A, Hunink MM. Diagnostic performance of stress myocardial perfusion imaging for coronary artery disease: A systematic review and meta-analysis. *European radiology*. 2012; 22: 1881-1895.
13. Kellman P, Arai AE. Imaging sequences for first pass perfusion—a review. *Journal of Cardiovascular Magnetic Resonance*. 2007; 9: 525-537
14. de Jong MC, Genders TS, van Geuns R-J, Moelker A, Hunink MM. Diagnostic performance of stress myocardial perfusion imaging for coronary artery disease: A systematic review and meta-analysis. *European radiology*. 2012; 22:1881-1895.
15. Burrell S, MacDonald A. Artifacts and pitfalls in myocardial perfusion imaging. *Journal of nuclear medicine technology*. 2006; 34: 193-211.
16. Iskandrian AE, Garcia EV. *Nuclear cardiac imaging: principles and applications*: Oxford University Press; 2008.
17. Ghibellini G, Vasist L, Leslie E, Heizer W, Kowalsky R, Calvo B, et al. In vitro—in vivo correlation of hepatobiliary drug clearance in humans. *Clinical Pharmacology & Therapeutics*. 2007; 81: 406-413.
18. Garcia E. Optimal specificity of thallium-201 SPECT through recognition of imaging artefacts. *J Nucl Med*. 1989; 30: 441-449.
19. FOX L, HIXSON D. Frequency of extra-cardiac activity and its effect on <sup>99m</sup>Tc-MIBI cardiac SPET interpretation. *Nuclear medicine communications*. 1996;17:851-856.
20. Loghin C, Sdringola S, Gould KL. Common artifacts in PET myocardial perfusion images due to attenuation—emission misregistration: clinical significance, causes, and solutions. *Journal of Nuclear Medicine*. 2004; 45: 1029-1039.
21. Campisi R, Marengo FD. Myocardial Perfusion Imaging for the Evaluation of Ischemic Heart Disease in Women. *Current Cardiovascular Imaging Reports*. 2019; 12: 4.
22. Johnson NP. Cardiac PET. *Annals of Nuclear Cardiology*. 2019: 19-00085.
23. Yoshinaga K, Manabe O. Positron Emission Tomography Myocardial Perfusion Imaging. *Clinical Nuclear Cardiology: Practical Applications and Future Directions*. 2018; 2: 67-86.
24. Qayyum A, Kastrup J. Measuring myocardial perfusion: the role of PET, MRI and CT. *Clinical radiology*. 2015; 70:576-584.
25. Villines TC. Myocardium in jeopardy: The hemodynamic implications of stenosis proximity and severity on coronary CTA. *Journal of cardiovascular computed tomography*. 2018; 12: 255-256.
26. Wan N, Travin MI. Cardiac PET assessment of myocardial microvascular flow may help identify subclinical left ventricular dysfunction and increased risk from aortic stenosis. Springer. 2019.
27. Yusuf S, Reddy S, Ôunpuu S, Anand S. Global burden of cardiovascular diseases: part I: general considerations, the epidemiologic transition, risk factors, and impact of urbanization. *Circulation*. 2001; 104: 2746-2753.
28. Townsend N, Wilson L, Bhatnagar P, Wickramasinghe K, Rayner M, et al. Cardiovascular disease in Europe: epidemiological update 2016. *European heart journal*. 2016; 37: 3232-3245.
29. Townsend N, Nichols M, Scarborough P, Rayner M. Cardiovascular disease in Europe—epidemiological update 2015. *European heart journal*. 2015; 36: 2696-2705.
30. Dasselaar JJ, Slart RH, Knip M, Pruim J, Tio RA, et al. Haemodialysis is associated with a pronounced fall in myocardial perfusion. *Nephrology Dialysis Transplantation*. 2008; 24: 604-610.
31. Sorrell VL, editor *Diagnostic tools and management strategies for coronary artery disease in patients with end-stage renal disease*. *Seminars in nephrology*; 2001: Elsevier.
32. Havel M, Kaminek M, Metelkova I, Budikova M, Henzlova L, et al. Prognostic value of myocardial perfusion imaging and coronary artery calcium measurements in patients with end-stage renal disease. *Hell J Nucl Med*. 2015; 18: 199-206.
33. Zoghbi GJ, Patel AD, Ershadi RE, Heo J, Bynon JS, et al. Usefulness of preoperative stress perfusion imaging in predicting prognosis after liver transplantation. *The American Journal of Cardiology*. 2003; 92: 1066-1071.
34. Davidson CJ, Gheorghide M, Flaherty JD, Elliot MD, Reddy SP, et al. Predictive value of stress myocardial perfusion imaging in liver transplant candidates. *American Journal of Cardiology*. 2002; 89: 359-360.
35. Krag A, Bendtsen F, Henriksen JH, Møller S. Low cardiac output predicts development of hepatorenal syndrome and survival in patients with cirrhosis and ascites. *Gut*. 2010; 59: 105-110.