



# Radiographic Imaging of Covid-19: Paeditric Cases- Is Chest X- Ray Dependable in Diagnosing Covid – 19 in Children? An Experience of a Tertiary Care Paediatric Centre of North India

Sangeeta Tripathy<sup>1\*</sup>; BKS Chauhan<sup>2</sup>; Umesh Shukla<sup>3</sup>; Devajit Nath<sup>4</sup>

<sup>1</sup>Department of Radiology, Super Speciality Paediatric Hospital and Post Graduate Teaching Institute (SSPH&PGTI) Sector-30, Noida, India -201303.

<sup>2</sup>Retired Radiologist, Dr. BKS Chauhan, Delhi, India.

<sup>3</sup>Department of Gastroenterology, Super Speciality Paediatric Hospital and Post Graduate Teaching Institute (SSPH&PGTI) Sector-30, Noida, India -201303.

<sup>4</sup>Department of Pathology, Super Speciality Paediatric Hospital and Post Graduate Teaching Institute (SSPH&PGTI) Sector-30, Noida, India -201303.

## \*Corresponding Author(s): Sangeeta Tripathy

Department of Radiology, Superspeciality Paediatric Hospital & Postgraduate Teaching Institute, Sector – 30, Noida, India 201303.

Tel: 72-8900-2268, Fax: 91-11-28745741;

Email: dr.sangeetatripathy@yahoo.co.in

## Abstract

**Introduction:** The Corona Virus disease (COVID-19) is declared as pandemic by WHO on 11th March 2020. This is an infectious disease caused by novel corona virus SARS-CoV-2. Children seems to be relatively unaffected by this virus or other closely related corona viruses. Definitive diagnosis of COVID-19 requires a positive RT-PCR test. X-Ray chest & CT-Chest is not used to diagnose COVID-19 but helpful in assessing disease progression & complications. Only 1.2% to 1.7% of the paediatric COVID-19 cases have been reported from USA and China respectively. US data of pediatric COVID-19 cases as of August 27<sup>th</sup> 2020: Cumulative child cases-4, 76,439 which is 9.5% of cumulative percent children of total cases. As the pandemic progresses, portable chest X-ray will play an important role because of its ready availability as RT-PCR has long turnover time and in places where limited access to RT-PCR is there.

**Method:** A single centre retrospective, observational study of confirmed COVID-19 pediatric patients admitted to SSPH & PGTI, NOIDA, North India during March 2020 to July 2020 were enrolled in the study. The RT-PCR positive COVID-19 patients CXRs were analyzed for their patterns and its progression in children and also follow up CXR if required were assessed for finding out complications if any. This study also proves that CXR is the first line tool for detecting the COVID-19 disease in areas of world where limited access to RTPCR is there or long turnaround time of

Received: Sep 21, 2020

Accepted: Oct 28, 2020

Published Online: Nov 02, 2020

Journal: Journal of Radiology and Medical Imaging

Publisher: MedDocs Publishers LLC

Online edition: <http://meddocsonline.org/>

Copyright: © Tripathy S (2020). This Article is distributed under the terms of Creative Commons Attribution 4.0 International License

**Keywords:** SARS-CoV-2; Pandemic; CXRs; CT Chest; Paediatric

**Cite this article:** Tripathy S, Chauhan BKS, Shukla U, Nath D. Radiographic Imaging of Covid-19: Paeditric Cases-Is Chest X- Ray Dependable in Diagnosing Covid – 19 in Children? An Experience of a Tertiary Care Paediatric Centre of North India. J Radiol Med Imaging. 2020; 3(1); 1035.



## RTPCR.

**Result:** Abnormal chest X-Ray found in (n=6), 29%. CXR is the first line tool for detection of COVID-19. Ground glass opacities and consolidation are most common findings with involvement of left lung in almost all cases. Peripheral lung involvement, bilateral lung involvement also found in CXRs. In contrast to adults where follow up CXRs are more due to disease course and comorbidities, in children its number is very less.

**Conclusion:** Paediatric Corona virus disease (COVID-19) is mild in children and young. They present with mild symptoms or are asymptomatic. Children have better prognosis in comparison to adults and with rare mortality. CXR play an important role as first line tool in detecting the disease especially in places where access to RTPCR is not there or due to prolonged turnaround time of RTPCR.

## Introduction

Paediatric age group account for 1-5% of diagnosed COVID-19 cases. Paediatric corona virus disease (COVID-19) infection is relatively mild as compared to adults with rare mortality. Prognosis appear to be better in children & infected children are mostly asymptomatic & hence diagnosis is difficult without population screening globally. The US has reported a percentage of 1.7% of paediatric COVID-19 out of 1,49,082 confirmed cases between 12<sup>th</sup> Feb & 2<sup>nd</sup> April 2020.

The diagnosis of COVID-19 was according to the Ministry of Health & FW (MOHFW), Govt. Of India (GOI) guidelines & confirmed by RT-PCR performed on nasopharyngeal and throat swab sample of the patient.

SARS-CoV-2 has a higher transmission capability compared with closely related Viruses causing severe acute respiratory syndrome SARS (2002-2003) & MERS. Children & young adults are less severely affected in India than adults. The American college of Radiology (ACR) noted that CT suite decontamination required after scanning of COVID-19 patients may disrupt the radiological service availability & suggest that portable chest X-Ray may be used to minimise the risk of Cross infection.

The probable reasons being COVID-19 is milder in children are:-

1. In paediatric lungs & other tissue, increased expression of ACE 2 gives further protection and helps in uneventful clinical scenario [22].
2. In children there is hindrance of virus entry into lung pneumocytes as there is higher frequency of beating lung cilia in children [22].
3. Due to decreased generation of thrombin & fibrin formation, children have low risk of COVID-19 associated acute respiratory distress syndrome.
4. Less exposure of children to pollutants and particulate matter, protect lung & airways.
5. Lack of co-morbidities in children protects their lungs & airways.
6. Children do not face cytokine storm & thus do not face severe complications normally.
7. The exposure of children to various vaccines [23] as per

universal immunization programme in India helps in immune system activation in children.

8. Children are relatively free from physical & mental stress which protects them.

## Aim

1. To establish the role of chest x-ray (CXR) in identifying paediatric pulmonary lesions in COVID-19.
2. To establish the role of CXR (Chest X-Ray) as primary tool for identification of disease.
3. To find out the disease pattern in children & its progression.
4. To follow up lung abnormalities by CXR if required.

## Material and method

A single centre, retrospective, observational study of COVID-19 pediatric patients from our tertiary care paediatric hospital, SSPH & PGTI, NOIDA, North India, has been done where all the lab confirmed corona virus disease cases have been included. CXRs taken from 19<sup>th</sup> March 2020 to 31<sup>st</sup> July 2020 were collected & analyzed.

The CXRs were done by a portable 100mA X-Ray machine stationed in COVID-19 ward whenever there is need during the clinical course. The CXRs were analysed & degree and type of lung involvement were found on CXRs and follow up CXRs if required.

The demographic data and radiological findings of the enrolled patients were recorded. The patterns of manifestations and degree of severity in CXRs were documented & lung abnormalities in follow up CXRs if there, were also recorded for monitoring of patients.

**Table 1:** Demographic profile of the Cases under study (n-93).

S. No	Age Group	No. of Patient	Percentage of Patient
1	0-1 month	4	4%
2	1 month -1 year	12	13%
3	1 year – 10 year	54	58%
4	10 years – 18 years	23	25%

The youngest case in our study is of 3 days who recovered in due course of time. The median age is 7 years in our study.

**Table 2:** Number of cases gender wise.

S. No.	Gender	Number of cases	Percentage of cases
1	Male	56	60%
2	Female	37	40%

Male children constitute about 60% of cases whereas female patients were 40% in our study.

**Table 3:** Clinical features - Patients presented at the time of admission (n=93).

S. No.	Clinical presentation	Number of cases	Percentage of cases
1	Asymptomatic	49	53%
2	Fever	11	12%
3	Cough	8	09%
4	Running nose	1	01%
5	Sore throat	6	06%
6	vomiting	3	03%
7	Redness of eye	3	03%
8	Rash	1	01%
9	Diarrhoea	0	0%
10	Tiredness	3	03%
11	Body Pain	4	04%
12	Breathlessness	5	05%

Out of the total children, (n=49) 53% were asymptomatic, fever (n=11) 12% and cough (n=8) 9% were most frequent symptoms.

**Table 4:** Co-morbidities found in our study (n=93).

S. No	Co-morbidities	Number of Cases	Percentage of cases
1	History of trauma with orbital fracture, Chest trauma	1	01%
2	Coeliac disease	1	01%
3	AML	1	01%
4	PTB	1	01%
5	Oral ulcers	1	01%
6	DMD	1	01%

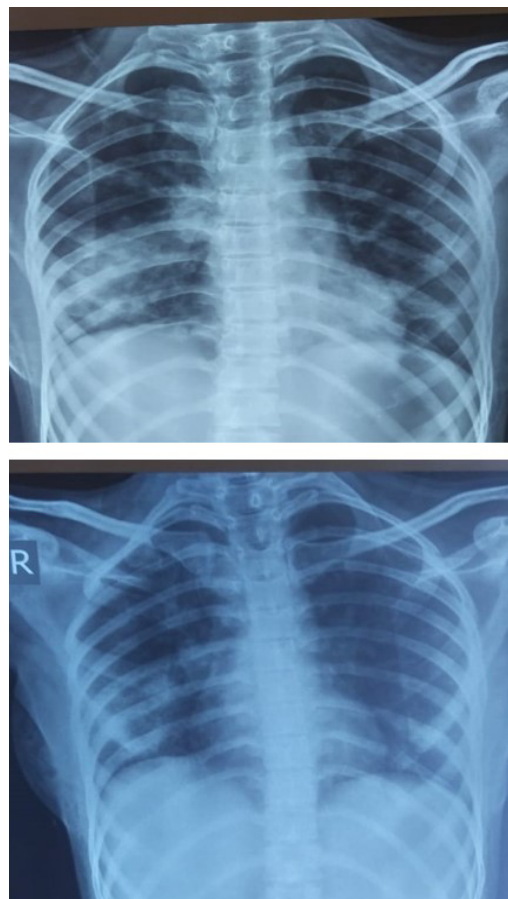
**Table 5:** Contact in family/locality.

S. No.	Contact/noncontact	Number of cases	Percentage of cases
1	Contact	80	86%
2	Noncontact	13	14%

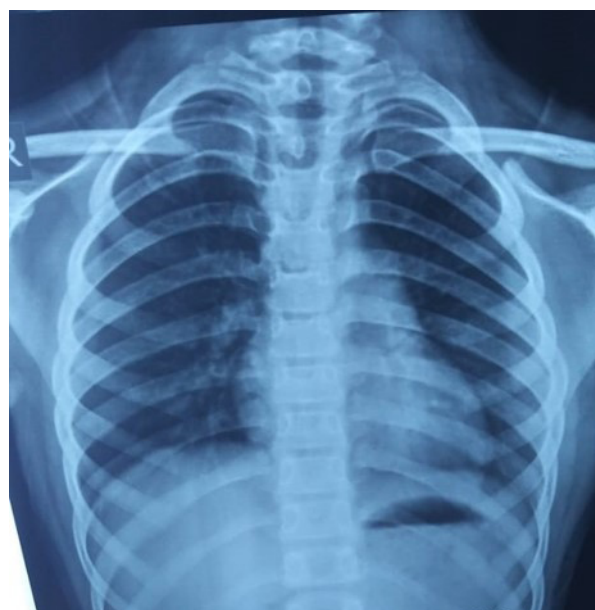**Table 6:** Radiographic findings on CXR (Chest X-Ray) (n=21).

S. No.		Number of cases	Percentage of cases
1	Number of patients with normal CXR	15	71%
2	Number of patients with abnormal CXR	5	24%
3	Number of patients with normal CXR who later become abnormal	1	5%

As we get large number of patients who are asymptomatic or with mild symptoms, the CXR findings are normal in 15(71%) in our study, with mild CXR changes in (n=5) 24% of cases.



**Figure 1:** RLZ- Peripheral Consolidation Rt- Perihilar consolidation. Same patient showing Improvement. Also, LMZ & LLZ peripheral consolidation before improvement



**Figure 2:** GGO, LMZ& LLZ extending to Periphery.

**Table 7:** CXR features (Most common findings in CXRs).

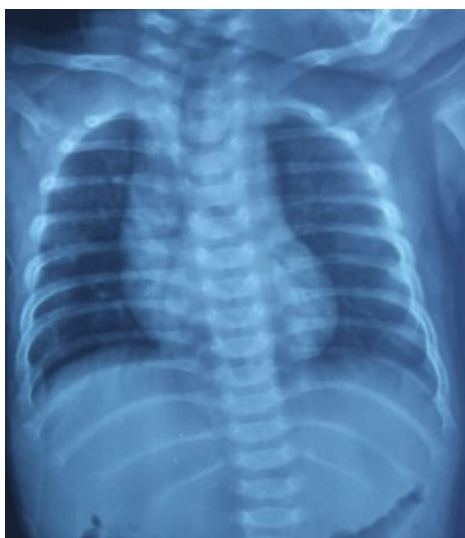S. No.		Number of cases	Percentage of cases
1	Consolidation	3	50%
2	Ground glass opacity (GGO)	3	50%

Consolidation and ground glass opacity account for 3 cases (50%) & 3 cases (50%) respectively.

**Table 8:** Shows degree of severity of lung involvement.

S. No.		Number of cases	Percentage of cases
1	Abnormal CXR –mild (<25%)	5	83%
2	Abnormal CXR-moderate (25-50%)	1	17%
3	No severe case	0	0%

In one child moderate involvement of both lungs noted, who is suffering from AML. No severe involvement case found in this study.

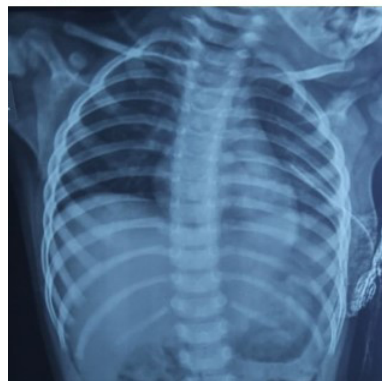
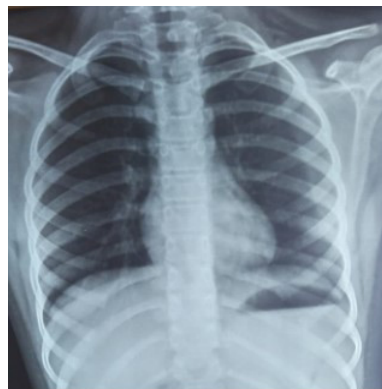
**Figure 3:** GGO LMZ

**Table 9:** Localization of abnormalities in CXRs.

S. No.		Number of cases	Percentage of cases
1	Lower zone consolidation/GGO	3	50%
2	Peripheral consolidation/GGO	2	33%
3	Bilateral lung involvement	1	17%
4	Perihilar consolidation	1	17%
5	Left lung involvement	6	100%
6	Right lung involvement	1	17%

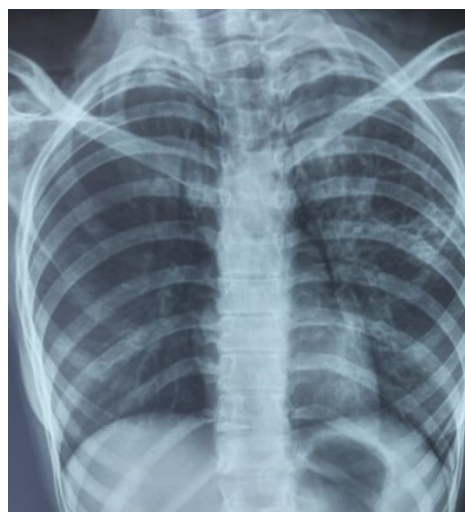
No multifocal or diffuse involvement of lung found in our study. Left lung involvement noted in all six cases.



**Figure 4:** (i) LLZ Peripheral opacity (ii) case of chest trauma With ICD tube insitu with minimal GGO LMZ.

**Table 10:** Other findings associated with CXRs due to persisting radiologically active lesion in Indian scenario.

S. No.		Number of cases	Percentage of cases
1	Cavity with infiltration (S/o active TB)	1	17%
2	Trauma chest with ICD tube in situ with mild LMZ GGO.	1	17%



**Figure 5:** Infiltration LMZ & LLZ thin walled cavity LMZ.

**Discussion**

COVID-19 pandemic has come with an unprecedented health crisis since December 2019.

The American college of Radiology (ACR) observed that CT suite decontamination required after scanning of COVID-19 pa-

tients may disrupt the radiology service availability and suggest the portable chest X-Ray (CXR) may be used to minimize the risk of cross infection [1]. Currently, the Society of Thoracic Radiology and American College of Radiology (ACR) do not support the use of chest CT for routine screening of COVID-19 [2].

Most of the infections are asymptomatic in children and many are not reported. Many have mild symptoms and milder form of the disease compared to adults [4]. Children comprise of 1-5% of diagnosed COVID-19 cases [3]. Asymptomatic, mild and moderate cases account for 90% of all COVID-19 children with fewer severe cases compare to adults [4,5].

The clinical profile of coronal virus disease infection in children is variable and information from developing countries is not readily available except in china [6]. Most of the COVID-19 children are secondary cases and get infection from intrafamily transmission [7]. In our study we found intrafamily contact & locality contact in 80 cases (86%) as found by Jiena oc et al [7].

US data of paediatric COVID-19 cases as of 27<sup>th</sup> August 2020; Cumulative child cases 4,76,439 which is 9.5% of cumulative percent children of total cases.

The median age of infection is 6.7 years (range newborn to 15years) as per one study [5], in our study, the median age is 7 years which is similar to the study mentioned above(range newborn to 18 years). The male children comprising (n=56) 60% of cases in our study. The neonate comprise (n=4) 4% of cases and large number of cases noted in 1-10 years age group (n=54), 58% of cases in our study.

The most common clinical features noticed at the onset in children are fever (50%) and mild cough (38%) [7,15]. In our study we observed, fever (12%) & cough (9%) as major symptoms. Children have more upper respiratory features [4,10,15]. as has been found in our study (n=20) 22%. Asymptomatic cases account for (n=49) 53% cases.

Clinical course of COVID-19 in children have been less severe than adults in our study which is consistent with other reports published on COVID-19 in children [16].

In a metaanalysis by Meena et al [10] study which showed that even among the symptomatic COVID-19 cases severe manifestations are found in fewer. They further noted that fever and respiratory symptoms are most common, though many children have gastrointestinal manifestations [10]. GI manifestations may be sole manifestation of COVID-19 [17]. However, we have few (n=3) 14% of cases.

Co-morbidities found in (n=6) 6% of cases in our study in COVID-19 ward in sharp contrast to the study done by Banerjee et al [19]. This may be due to better health of children in this region.

Paediatric patients have less extensive involvement on imaging [21]. CXR findings helps in identifying the lung lesion in children and children with milder disease should not routinely need CT chest in view of high radiation exposure [11]. First imaging study done in most of the centres in COVID-19 patients is CXR. Clinical literature reviewed by Foust and colleagues noted that studies on chest radiography findings in patients with COVID-19 were relatively scarce, more so in paediatric patients.

The most common imaging pattern in CXR in COVID-19 children is bilateral, peripheral predominant, Ground glass opac-

ity or consolidation in mid or lower lung zones as described by Foust & Lee of Boston Children's Hospital and other hospitals around the world [8,18]. In our study lower zone consolidation is (n=3) 50% of cases which is consistent with above study. In CXR peripherally located consolidation is noted with multilobar involvement [12]. In our study we found peripheral consolidation in (n=2) 33% of cases.

Both unilateral and bilateral opacities noted in paediatric COVID-19 patients, though bilateral opacities are more often seen. In our study, we found bilateral lung involvement in (n=1) 17% cases and one lung involvement (left lung involvement) in (n=6) cases, 100% cases. Consolidation is most often found in paediatric patients. In our study consolidation and GGO noted in children with COVID-19 in (n=3) 50% cases respectively. No multifocal or diffuse involvement found in our study.

In our study as reported by authors normal CXR found in (n=15) 71% of cases & abnormal CXR found in (n=6) 29% of cases, because many children with COVID-19 are with mild symptoms or asymptomatic. Mild abnormalities in CXR (n=5) 83% found in our study with moderate abnormality in one CXR (n=1) 17% case.

Children who were immunocompromised were not at greater risk of severe COVID-19 probably due to the fact that a functional host innate immune response is the main driver for lung damage as described by Antiga et al [14]. In our study a child (case of AML), there is improvement of consolidation (bilateral, peripheral) within two weeks who had a moderate course of the disease during hospitalization.

India being a country where tuberculosis is rampant, we experienced a case of active pulmonary TB with thin walled cavity which constitute (n=1) 17% of cases.

Negative CXR does not exclude pulmonary involvement in patients with lab confirmed COVID-19. CXR also helps in identification of alternative diagnosis especially if typical CXR findings of COVID-19 not found. Further sequential CXRs are required in children with COVID-19 to monitor response to supportive measures, assess clinical deterioration etc. & post recovery CXR may be required in cases if child has symptom after negative RTPCR [20].

### Conclusion

Many of paediatric group COVID-19 patients having mild symptoms due to mild infection and many were asymptomatic. The commonest presentations were fever and upper respiratory symptoms.

The role of radiographic examination (CXR) is basically involved in initial diagnosis, evaluation of disease progress, for follow up CXR and in post recovery cases if required.

CXR is very essential in diagnosis of lung abnormalities in children as CT chest is not recommended because of high radiation to children. Therefore, CXR in children with COVID-19 is of vital importance.

### Limitation of the study

1. There is sparse literature available in use of CXR in COVID-19 in paediatric age group.
2. The Study is of observational study, retrospective study of single centre.

3. Further absence of basic CXR to identify preexisting lung abnormality if any.
4. Some of CXR have subtle change hence limiting the value especially if A-P view taken.

**Known facts about the topic:** Chest X-ray by portable X-Ray unit is the commonly used modality for detection & follow up of lung abnormalities to avoid the risk of cross infection (American college of Radiology). Due to infection control issue by patient transport to CT suite, & non availability of CT in parts of world, CXR has proved to be one of the early and useful methods of identification of lung lesion even though negative CXR does not exclude diagnosis of COVID-19. Further in children to avoid radiation, CT chest is not used. Currently the Society of Thoracic Radiology and ACR (American college of Radiology) do not support the use of Chest CT for routine screening of COVID-19.

**Added information from the study:** This study from a tertiary care paediatric centre of NOIDA, North India, is obtained to identify paediatric pulmonary abnormalities in COVID-19 and also to establish role of CXR as first line tool for detection/diagnosis of COVID-19 due to easy availability of portable X-Ray units worldwide and reduced radiation dose to children besides reducing the infection, avoiding the burden to CT, and in certain cases removing the need for CT. Further CXR plays an important role in follow up study whenever required and monitoring in severely ill patients (though severely ill patients in paediatric population is less).

**Funding:** Self

**Conflict of interest:** None

**Ethics committee approval:** Approval of exemption for informed consent applied to ethics committee. It is a retrospective study and an observation study with no direct involvement of patients and hence no patient identifiers were included.

**Author contribution:** The authors of the manuscript declare an equal contribution of the study.

**Acknowledgement:** We are thankful to the Department of Paediatric, SSPH&PGTI, NODA, INDIA, for their support in carrying out the study.

I, thank my X-Ray technicians for carrying out chest X-Ray of COVID-19 patients. We also thank our HCW for their untiring & selfless work.

## References

1. ACR recommendations for the use of chest radiography and computed radiography (CT) for suspected COVID-19 infection: American College of Radiology. *Economics/ACR-position-statements/recommendations for chest Radiography and CT for suspected COVID-19 infection.* 2020.
2. Society of Thoracic Radiology/American Society of Emergency Radiology COVID-19 position statement. 2020.
3. Ludvigsson JR. Systematic review of COVID-19 in Children show milder cases and a better prognosis than adults. *Acta paediatr.* 2020.
4. Dong Y, Mo X, Hu Y, Qi X, Jiang F, et al. Epidemiological characteristics of 2143 pediatric patients with 2019 corona virus Disease in china. *Paediatrics* 2020.
5. Lu X, Zhang L, Du H, SARS-CoV-2 infection in children. *N Engl J Med.* 2020; 23; 382; 317.
6. Cai J, Xu S, Lin D, Yang Z, Xu L, et al. A case series of children with novel Corona Virus infection: Clinical and epidemiological features. *Clin Infect Dis.* 2020.
7. Jiehao C, Jing X, Daojiong L, Lei X, Zhenghai Q, et al. A case series of children with 2019 novel corona virus infections: Clinical epidemiological features. *CID.* 2020.
8. Alice Mc Carthy et al. Radiology of COVID-19 infection in children: Imaging findings and recommendations. *Boston Children's Hospital.* May 25, 2020.
9. Shekerdemian LS, Mahmood NR, Wolf KK, Riggs BJ, Ross CE, et al. Characteristic & outcomes of children with Corona virus Disease 2019 (COVID-19) infections admitted to US end Candian pediatric intensive care units. *JAMA paediatr.* 2020; 10.
10. Meena J, Yadav J, Saini L, Yadav A, Kumar J. Clinical features and outcome of SARS-CoV-2 infection in children. *A systematic review and Meta analysis.* *Indian pediatr.* 2020; S097475591600203.
11. Kelvin AA, Halperin S. COVID-19 in children: the link in the transmission chain. *Lancet infect Dis.* 2020.
12. Li B, Shen J, Li LI, Yu C. Radiographic and clinical features of children with 2019 Novel coronavirus (COVID-19) pneumonia. *Indian paediatr.* 2020.
13. Xia W, Shao J, Guo X, Peng X, Hu D. Clinical & CT features in pediatric patients with COVID-19 infection: Different points from adults. *Pediatric pulmonology.* 2020
14. Antiga LD, Coronavirus and immunosuppressed patients. The facts during the third epidemic. *AASLD.* 2020.
15. Rodriguez-Morales AJ, Cardona-Ospina JA, Gutiérrez-Ocampo E, Villamizar-Peña R, Holguin-Rivera Y, et al. Clinical, laboratory and imaging features of COVID-19: A systematic review and meta-analysis. *Travel medicine and infectious disease.* 2020; 101623.
16. Chen A, Huang J, Liao Y, Liu Z, Chen D, Yang C, Yang R, Wei X. Differences in clinical and imaging presentation of pediatric patients with COVID-19 in comparison with adults. *Radiology: Cardiothoracic Imaging.* 2020; 2: e200117.
17. Tian Y, Rong L, Nian W, He Y. Review article: Gastrointestinal features in COVID-19 and the possibility of faecal transmission. *Aliment pharmacol Ther.* 2020; 51: 843-51.
18. Bayan Issa. Corona virus disease 2019 (COVID-19) in children. *25 Medscape.* 2020.
19. Banerjee S, Guha A, Das A, Nandy M, Mondal R. A preliminary report of COVID-19 in India. 2020.
20. Alexandra M Foust, Grace S Philips, winnie C Chu. International Expert consensus statement on chest Imaging in pediatric COVID-19. Patient management: imaging findings, imaging study and reporting imaging study recommendations. *Radiology: Cardiothoracic Imaging,* 2020; 2: 2.
21. Kumar J, Meena J, Yadav A, Yadav J. Radiological Findings of COVID-19 in Children: A Systematic Review and Meta-Analysis. *Journal of tropical pediatrics.* 2020.
22. Chilvers MA, Rutman A, O'callaghan C. Functional analysis of cilia and ciliated epithelial ultrastructure in healthy children and young adults. *Thorax.* 2003; 58: 333-338.
23. Prompetchara E, Ketloy C, Palaga T. Immune responses in COVID-19 and potential vaccines: Lessons learned from SARS & MERS epidemic. *Asian Pac J Allergy Immunol.* 2020; 38: 1-9.