



# Measurement of Normal Subcarinal Angle using Computed Tomography

**\*Corresponding Author(s): Sudil Paudyal**

Department of radiology, Tribhuvan University, Institute of Medicine, Maharajgunj Medical Campus, Kathmandu, NEPAL.

Email: sudlpaudyal@gmail.com

## Abstract

**Background:** Subcarinal Angle (SCA) is an angle of divergence of the right and left main stem bronchi. Change in tracheal bifurcation angle is an indirect marker of various cardiac, pulmonary and mediastinal pathologies. Helical Computed Tomography (CT) allows acquisition of volumetric set of data of the chest and can be used for accurate measurement of subcarinal angle using reconstructed image on a workstation using minimum intensity projection (MinIP). The objective of this study was to estimate normal Subcarinal Angle (SCA) of trachea by computed tomography, to compare with sex and age.

**Methodology:** A total of 130 (65 males and 65 females) in the age group 18-65 years who were subjected to CT chest for various indication in our department. Plain images were reconstructed into 1.5mm reformatted image and processed into minimum intensity projection (MinIP), for determination of subcarinal angle measuring tool provided at workstation was used.

**Results:** The median Subcarinal Angle (SCA) in adult population was (65 IQR = 22). The median subcarinal angle for male was 65 (IQR=22) and for female was 65 (IQR=27). There was weak negative correlation between subcarinal angle and age but statistically insignificant ( $p > 0.05$ ,  $r = -0.044$ ).

**Conclusion:** The median value of sub carinal angle is independent of age and gender. The median value was found to be 65o (IQR=22) among the adult population. There was negative correlation between sub carinal angle and age but statistically insignificant.

Received: Sep 23, 2022

Accepted: Oct 18, 2022

Published Online: Oct 20, 2022

Journal: Journal of Radiology and Medical Imaging

Publisher: MedDocs Publishers LLC

Online edition: <http://meddocsonline.org/>

Copyright: © Paudyal S (2022). *This Article is distributed under the terms of Creative Commons Attribution 4.0 International License*

**Keywords:** Trachea; Sub carinal angle; Computed Tomography; Minimum Intensity Projection.

## Introduction

Subcarinal Angle (SCA) is an angle of divergence of the right and left main stem bronchi. The subcarinal angle contributed by the right bronchus is small. It is more or less in the same line with the trachea, so lodgment of foreign body is more common in right bronchus. The knowledge regarding the subcarinal angle is of clinical importance because, bronchoscopy is easier in adults than neonates and children as it requires more skill to introduce the scope particularly on the left side which might

give a false interpretation of bronchial obstruction on failing to introduce the bronchoscope on the correct side [1]. The subcarinal angle indirectly helps in diagnosing some cardiovascular problems [2]. Increase or decrease in the SCA is mentioned as an indirect sign of pathology in the heart or mediastinum [3]. Many diseases of heart or mediastinum led to an increase or decrease in the SCA. Increase in the Subcarinal angle is mentioned as indirect sign of pathology in the heart or mediastinum such as left atrial enlargement, generalized cardiomegaly, lobar collapse, sub carinal mass or pleural effusion [4,5,6].



**Cite this article:** Paudyal S. Measurement of Normal Subcarinal Angle using Computed Tomography. J Radiol Med Imaging. 2022; 5(2): 1077.

The Subcarinal angle on chest radiograph ranges from 45-70 in adults according to Alavi et al., [7] The study of bronchial tree is done by both invasive and non-invasive techniques like cadaveric dissection, bronchogram, virtual bronchoscopy, computed tomography scan and Magnetic Resonance Imaging (MRI) scan [8]. Cadaveric studies are limited in application because of post-mortem changes and necessary tissue fixation techniques [9]. These types of studies were replaced by CT because of the ability to more easily and accessibly gather and study the different age groups. Computed tomography adds a 3-dimensional component to the understanding of tracheobronchial anatomy. It has proven to be an excellent technique for evaluating mediastinal structures and is an excellent method of displaying the cross-sectional anatomy of the trachea. Unlike autopsy and bronchoscopy, CT causes little or no disturbance of tracheal anatomy. Non-invasive CT area calculations may be useful in demonstrating and quantifying tracheal obstruction when mediastinal neoplasms are staged and, also to decide about treatment plan. The morphology of the trachea varies in healthy and diseased individuals. Changes in tracheal dimensions occur in a variety of conditions. Knowledge of normal tracheal dimensions is essential to the diagnosis of these conditions, in problems in respiratory physiology, and also in endotracheal intubation, endoscopy, and tracheostomy. In patients with left atrial enlargement, subcarinal lymphadenopathy, bronchogenic cyst, and mediastinitis, the subcarinal angle may be abnormally large [8].

Most of the previous studies assess the subcarinal angle on chest radiographs using a goniometer [3,10,11]. Helical Computed Tomography (CT) enables the acquisition of volumetric images of the chest and facilitates accurate measurements using reconstructed images on a workstation using minimum intensity projection (MinIP). MinIP is a data visualization process that allows detection of low intensity structures in a given volume as the algorithm uses all the data in a volume of interest to generate a single bidimensional image. [12] This study determined the factors which contribute to anatomic changes of Subcarinal angle. Such variations may contribute to diagnostic, congenital abnormalities, problems in respiratory physiology and pathologies like atrial enlargement, subcarinal lymphadenopathy, bronchogenic cyst and mediastinitis.

### Methodology

Descriptive cross-sectional study design was used in this study. This study was performed in Department of Radiology, Chitwan Medical College Teaching Hospital from November 2020 to April 2021, in patients who were referred for CT scan of chest. However, patients with a history of prior cardiothoracic surgery, distorting intra thoracic pathology and neck injury; who failed to hold their breath and patients with the disease condition fibrosis, metastases, bronchiectasis, Covid- 19 were excluded.

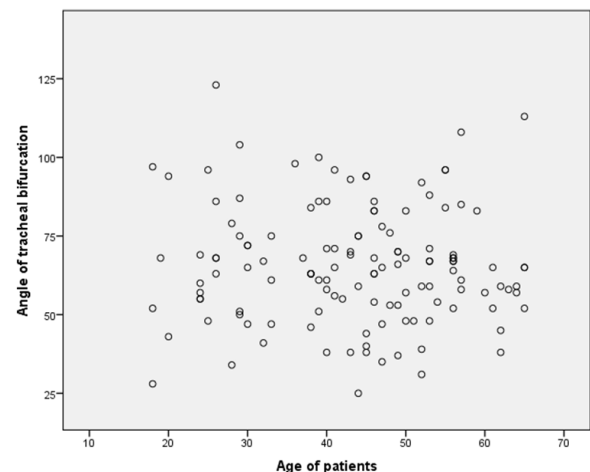
CT Imaging was performed on Siemens Somatom AS-128 slices multi detector CT with a single breath hold using 128x0.625 collimation, 120kVp and 200-250mAs. The rotation time and pitch of scan were 0.5 and 1.2 respectively. The image was acquired in 5mm thickness and reconstructed using reconstruction interval of 1mm into 1.5mm reformatted images. The images were viewed in MinIP in coronal plane at window width of 1600HU and centering of -600HU. Subcarinal Angle (SCA) was measured on coronal reformatted images using minimum intensity projection (MinIP). Subcarinal angle was determined by using the angle measurement tool of the DICOM software. The obtained data was analyzed using appropriate statistical

software after due reviewing of accuracy and completeness in terms of descriptive statistics.

### Results

A total of 130 patients' normal CT chest scan was used to measure subcarinal angle. There were 65(50%) male and 65 (50%) female patients with age ranging from 18-65 years (mean age 45). Applying *Kolmogorov Simron* test the age of patients and subcarinal angle did not follow the normality. Among the 130 patients, the subcarinal angle below 40 was found in 8.5% (11) of population, above 80 was found in 22.3% (29) of population and the maximum population that is 69.2% (90) had the angle ranging from 40-80, the minimum subcarinal angle being 25 and the maximum subcarinal angle being 123. The median of subcarinal angle found to be 65, IQR=22. The median subcarinal angle for males was 65 and mean rank was 65.23, for females median subcarinal angle was 65 and mean rank of subcarinal angle was 65.77. Applying Mann-Whitney U test P-value was found to be 0.935, which is statically insignificant.

The Spearman correlation test was applied between subcarinal angle and age and it was found statistically not significant ( $p > 0.05$ ) with negative correlation (Spearman's  $r = -0.168$ ,  $n = 130$ ,  $p$  value = 0.616).



**Figure 1:** Scatter diagram of correlation of Age with subcarinal angle showing weak negative correlation.

### Discussion

The subcarinal angle can have a wide range of normal values in patients and can vary significantly when measured by conventional radiographs. Computed Tomography adds a 3-dimensional component to the understanding of tracheobronchial anatomy. It has proven to be an excellent technique for evaluating mediastinal structure. Minimum intensity projection (MinIP) is a data visualization method that enables detection of low density structures in a given volume. This reformation technique allows the examination of fine anatomical details which is hard to assess using axial sections.

Applying *Kolmogorov Simron* test the variables i.e. gender, age of patients and subcarinal angle do not follow the normality. So, the values were calculated in median.

In this study, we measured sub-carinal angle on CT chest scan of adult patients in respect to age and sex. The normal SCA ranged from 35°-90° [13]. The median value of SCA was 65, IQR=22 in our study which was comparable to previous studies. Alavi et al [7] found that the mean SCA was  $57.16^\circ \pm 6.06^\circ$ . Similarly, Haskin et al [13] found the value to be  $60.8^\circ \pm SD11.8^\circ$ .

Choorat et al., [14] had reported the mean SCA to be  $62^{\circ} \pm 12.62^{\circ}$ . Krishnaiah M. [2] did a cadaveric study to find various dimensions of trachea. In 25 cadaver tracheas, mean subcarinal angle was  $77.80$  ( $50-130$ ). A study performed by N Karabulut [15] show that the mean interbronchial angle is  $77^{\circ} \pm 13^{\circ}$  (range  $49-109^{\circ}$ ) and the subcarinal angle is  $73^{\circ} \pm 16^{\circ}$  (range  $34-107^{\circ}$ ) which was comparable to our study. The upper limit of the SCA in our study was 123 where the upper limit of the SCA was 88 in the study by Choorat et al., [14] and about 84 in the study by Haskin et al [13]. The greater value cause concern of abnormality.

When it came to considering gender, study by Alavi et al [7]., found mean value to be  $56.4 \pm 5.66^{\circ}$  in males and  $57.73 \pm 6.37^{\circ}$  in females. In contradiction, the cadaveric study conducted by Anusuya Shrestha et al [16]., found that was significantly more in males ( $68.02 \pm 15.720$ ) than in females ( $60.14 \pm 17.710$ ). Murray et al. [10] stated larger IBA and SCA values in female patients but did not assess its statistical significance, whereas in our present study, the mean SCA of males was found to be  $65^{\circ}$  IQR=22 and that of females was  $65^{\circ}$ , IQR=27. There was no difference between the mean SCA of male and female; therefore, it was concluded that there was no relationship between the SCA with patients' gender.

In our study, we considered adult age group i.e.18 to 65 years and found that the SCA was higher in the age 18-61 years than 62 and above. We found that in the age group 18-28, the SCA was  $65.5^{\circ}$  (IQR=32), in 29-39, the angle measured  $65^{\circ}$  (IQR=29), in 40-50, the angle measured was  $65^{\circ}$  (IQR=23), in 51-61, the angle measured found to be  $67^{\circ}$  (IQR=27), in age group 62 and above the angle measured was  $58.5^{\circ}$  (IQR=15). Chunder and Guha [17] study found that the mean SCAs in the 0-15 years, 16-25 years, 26-40 years, 41-55 years, and > 55 years age groups were  $61.4^{\circ}$ ,  $52.9^{\circ}$ ,  $49.2^{\circ}$ ,  $48.2^{\circ}$ , and  $54^{\circ}$  in females and  $64.3^{\circ}$ ,  $56.4^{\circ}$ ,  $58.4^{\circ}$ ,  $57.1^{\circ}$ , and  $59.5^{\circ}$  in males. The study performed by the study conducted by Khade et al., [8] who demonstrated a decrease in the SCA with an increase in the age group which is similar to our study. Also, a study performed by Salome Francia et al [18]., found in the age group of 20-40 years, the mean SCA was  $70.38 \pm 3.85^{\circ}$ , and in the age group of 41-

60 years, it was  $69.25 \pm 2.88^{\circ}$  which was not statistically significant. The association of sub carinal with age was not statistically significant. Our study found that age has influence over SCA. There was weak negative correlation ( $r = -0.044$ ,  $n = 130$ ) between SCA and age, but no statistical significance. In contrast to our study, according to other studies, age did not have influence over SCA whereas the study performed by RK Jha et al [19] found weak negative correlation between age and subcarinal angle. The reason behind this may be rigid chest wall as ossification of ribs occurs in older age and downward growth of the lung also causes SCA to be narrower [19]. Calcification of the cartilage rings of the trachea is the common finding after age 40 years, increasing in frequency with age which may be one reason of decreasing SCA with increasing age [20].

### Conclusion

The value of sub carinal angle is independent of age and gender. There was negative correlation between sub carinal angle and age but statistically insignificant.

### References

- Srinivasan V. A Morphometric study of human adult trachea and left main stem bronchus and its clinical implication. Masters thesis, Madras Medical College, Chennai.2017.
- Krishnaiah M, Mrudula C. The study of bronchial tree. International Journal of Pharma and Bio Science.2011; 2: 166-172.
- Minnich DJ, Mathisen DJ. Anatomy of the trachea, carina, and bronchi. Thoracic surgery clinics. 2007; 17: 571-585.
- Chen JT, Putman CE, Hedlund LW, Dahmash NS, Roberts L. Widening of the subcarinal angle by pericardial effusion. American Journal of Roentgenology. 1982; 139: 883-887.
- Woodring JH. The lateral chest radiograph in the detection of pericardial effusion: a reevaluation. The Journal of the Kentucky Medical Association. 1998; 96: 218-224.
- McKenna Jr RJ, Ali MK, Ewer MS, Frazier OH. Pleural and pericardial effusions in cancer patients. Current problems in cancer. 1985; 9: 1-44.
- Alavi SM, Keasts TE, O'brien WM. The angle of tracheal bifurcation: its normal mensuration. American Journal of Roentgenology. 1970; 108: 546-549.
- Khade B, Waheed AR, Yadav N, Diwan CV. Study of sub carinal angle of human trachea by computerized tomography. Int J Anat Res. 2016; 4: 2828-2832.
- Reed JM, O'Connor DM, Myer CM. Magnetic resonance imaging determination of tracheal orientation in normal children: Practical implications. Archives of Otolaryngology-Head & Neck Surgery. 1996; 122: 605-608.
- Murray JG, Brown AL, Anagnostou EA, Senior R. Widening of the tracheal bifurcation on chest radiographs: value as a sign of left atrial enlargement. AJR. American journal of roentgenology. 1995; 164: 1089-1092.
- Lin C, Lee JH, Hsieh CM. The correlation between subcarinal angle and left atrial volume. Age (years old). 2012; 67: 15-96.
- Perandini S, Faccioli N, Zaccarella A, Re TJ, Mucelli RP. The diagnostic contribution of CT volumetric rendering techniques in routine practice. The Indian journal of radiology & imaging. 2010; 20: 92.
- Haskin PH, Goodman LR. Normal tracheal bifurcation angle: a reassessment. American Journal of Roentgenology. 1982; 139: 879-882.
- Choorat S, Totanarungroj K, Muangman N. Assessment of normal subcarinal angle on chest radiographs in adult Thai population. Siriraj Medical Journal. 2008; 60: 264-266.
- Karabulut N. CT assessment of tracheal carinal angle and its determinants. The British journal of radiology. 2005; 78: 787-790.
- Shrestha A, Ranjit N, Bhandari R, Adhikari B, Gautam J. Measurement of Subcarinal Angle: A Cadaveric study. Journal of Institute of Medicine Nepal. 2019; 41: 20-23.
- Chunder R, Nandi S, Guha R, Satyanarayana N. A morphometric study of human trachea and principal bronchi in different age groups in both sexes and its clinical implications. Nepal Medical College journal: NMCI. 2010; 12: 207-214.
- Fernandes SF, Pradhan A. Estimation of subcarinal angle using minimum intensity projection in computed tomography. Asian Journal of Pharmaceutical and Clinical Research. 2018; 11: 383-385.
- Jha RK, Gupta MK, Pant AR, Pandey NK. Measurement of the Sub-carinal Angle on the Normal Chest Radiograph of Adult at BPKIHS, Dharan, Nepal. Journal of BP Koirala Institute of Health Sciences. 2019; 2: 46-51.
- Grant LA, Griffin N. Grainger & Allison's Diagnostic Radiology Essentials E-Book. Elsevier Health Sciences. 2018.