



# Extensive Retroperitoneal Fibrosis Secondary to Spondylodiscitis: A Case Report

Massaro MG<sup>1</sup>; Borriello R<sup>1</sup>; Contegiacomo A<sup>2</sup>; Cianci R<sup>1\*</sup>; Gambassi G<sup>1</sup>

<sup>1</sup>Internal Medicine, Catholic University of the Sacred Heart, A Gemelli University Hospital Foundation, IRCCS, Rome, Italy.

<sup>2</sup>UOC of Radiology and Neuroradiology, Department of Diagnostic Imaging, Oncological Radiotherapy and Hematology, A Gemelli University Hospital Foundation, IRCCS, Rome, Italy.

## \*Corresponding Author(s): Rossella Cianci

Internal Medicine, Internal Medicine, Catholic University of the Sacred Heart, A Gemelli University Hospital Foundation, IRCCS, Rome, Italy.  
Email: rosselciani@gmail.com

## Abstract

Retroperitoneal fibrosis is a rare pathology and often its etiology is unknown. The retroperitoneal fibrosis secondary to infectious diseases are infrequent. A delay in diagnosis can lead to irreversible complications, as renal failure and renovascular arterial hypertension. We describe a case of retroperitoneal fibrosis diagnosed two years after an *Escherichia coli* spondylodiscitis.

Received: Feb 12, 2022

Accepted: Mar 02, 2022

Published Online: Mar 04, 2022

Journal: Journal of Radiology and Medical Imaging

Publisher: MedDocs Publishers LLC

Online edition: <http://meddocsonline.org/>

Copyright: © Cianci R (2022). This Article is distributed under the terms of Creative Commons Attribution 4.0 International License

**Keywords:** Retroperitoneal fibrosis; Spondylodiscitis; *Escherichia coli*; Periaortic tissue.

## Case presentation

A 75-year-old woman, three days after returning from a trip to Brazil lasting 10 days, presented with fever (max temperature 38°C) but no sore throat, cough, or dyspnea. For this reason, she performed a chest x-ray that was deemed purportedly negative but, anyway, she started an empiric antibiotic treatment with clarithromycin. After 7 days of treatment, temperature returned to normal and she felt like in her usual good health. However, 5 days after stopping antibiotic therapy, the patient presented a new febrile episode, and, at this juncture, she was advised to perform a CT scan. A chest CT scan completed without the

administration of contrast media documented clear lungs, no pleural effusion and regular cardiac shape, but indicated that around the descending aorta, starting adjacent to the D11-D12 vertebral bodies, there was a tissue of uncertain nature. In order to proceed to a further investigation, she was referred to the Emergency Department of our academic medical center to exclude a possible aortic dissection. The patient's prior medical history was notable only for a diagnosis of diabetes mellitus type II, and for recurrent lower urinary tract infections, with the last episode approximately three months earlier. The patient was not taking any medication.

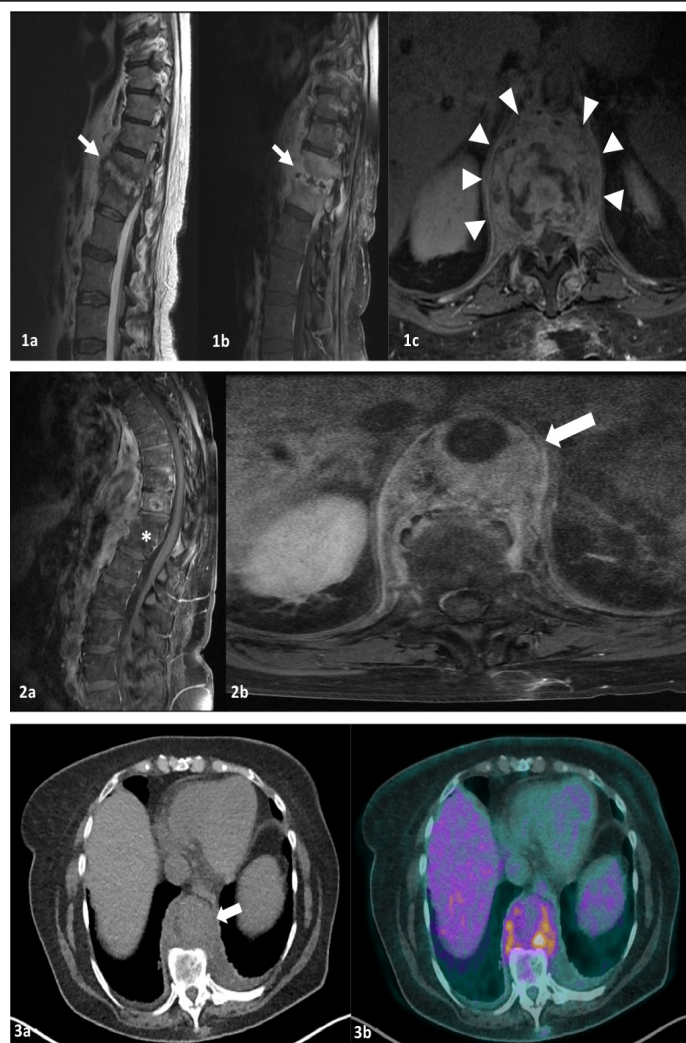


**Cite this article:** Massaro MG, Borriello R, Contegiacomo A, Cianci R, Gambassi G. Extensive Retroperitoneal Fibrosis Secondary to Spondylodiscitis: A Case Report. J Radiol Med Imaging. 2022; 5(1): 1069.

Two years earlier, however, the patient had been hospitalized for fever and low back pain and received a diagnosis of spondylodiscitis at the D11-D12 passage. On that occasion, she underwent an open, vertebral bone biopsy that documented an acute, purulent, inflammatory process but no malignant cells. Blood cultures identified the presence of a multi-sensitive *Escherichia coli*. The patient initiated an antibiotic treatment with ceftriaxone with rapid clinical and biochemical improvement. One month later, at a subsequent RM obtained to monitor the evolution of the lesion, it was documented an inflammatory/infectious signal alteration of the D11-D12 disc and a pathological sleeve tissue extending to the anterior epidural and to the pre-vertebral soft tissue up to the aorta posterior wall, without luminal reduction, nor medullary compression (**Figure 1, 1a and 1c**). For that reason, the patient continued the treatment with antibiotics for another month. After two months of continuous antibiotic treatment, the patient performed again an MRI. The imaging showed an almost complete resolution of the inflammatory signal alteration of the D11-D12 disc but the pathological tissue extending to the pre-vertebral soft tissue was substantially unchanged. About 6 months later, at a novel MRI there was an almost complete resolution of the inflammatory signal alteration at the D11-D12 disc and the pathological tissue extending to the pre-vertebral soft tissue was not documented. Since then, the patient reported good clinical conditions, until about 2 years later, when she came to our attention because of fever.

A new CT scan with the administration of contrast media documented that the Periaortic tissue had a prevalent fibrous component; it was arranged as a Periaortic sleeve and had a cranio-caudal extension going from the ascending aorta to the aortobisiliac bifurcation with involvement of the common iliac artery, bilaterally. The tissue also extended perirenally and around the pelvis with bilateral hydronephrosis. We therefore performed a spinal and abdomen MRI (**Figure 1, 2a and 2b**) that confirmed that the tissue around the aorta was originating from the paravertebral area. In order to exclude an infectious and/or an autoimmune etiology, additional laboratory tests were performed, including: serology for syphilis; urine and blood cultures; anti-nucleus antibodies, ANCA antibodies, ENA antibodies, anti-phospholipid antibodies and lupus anticoagulant, but they were all negative. No alteration of serum immunoglobulin concentration was found nor of protein electrophoresis. In addition, tumor markers (CYFRA 21-1, CA 19.9, CA 125, enolase) resulted normal. The erythrocyte sedimentation rate, however, was altered (69 mm/h; normal range. <30). A PET-CT exam indicated that the pre-vertebral and Periaortic tissue was metabolically active, pointing to an active Retroperitoneal Fibrosis (RF) (**Figure 1, 3a and 3b**). A video Thoracoscopy documented that the fibrotic tissue was extending to the parietal and mediastinal pleura and enveloping the thoracic aorta. The pathology examination of the tissue obtained with multiple biopsies documented the presence of an acellular, dense fibrosis with small foci of mesothelial hyperplasia and no evidence of malignant cells. Also, the presence of IgG4 and histiocytosis was excluded. The findings were taken as confirmatory of the clinical hypothesis of retroperitoneal fibrosis.

The patient developed bilateral hydronephrosis, with stage III renal failure and renovascular arterial hypertension. Medical therapy with valsartan, barnidipine, and doxazosin was initiated with moderate clinical benefit. The patient is currently waiting for ureteral stents placement. The creatinine level has remained stable at 1.66 mg/dl (eGFR using CKD-EPI formula: 30 ml/min) and fever did never recur.



**Figure 1:** T2-weighted images show high intensity signal of the D11-D12 intersomatic disc (arrow) (**1a**), which is enhanced at fat-suppressed, contrast-enhanced T1-weighted images (**1b**). Pathological tissue (arrowheads) extends to the anterior epidural and to the pre-vertebral soft tissue up to the aorta posterior wall without luminal reduction, nor medullary compression (**1c**). MRI findings show D11-D12 vertebral bodies fusion and endplates erosion associated with intersomatic disc degeneration (asterisk) (**2a**). A Periaortic sleeve of fibrotic tissue is evident and enhanced on contrast-enhanced T1-weighted images, extending from D7 upper body endplate to the lower body endplate of L1 (arrow) (**2b**). PET-CT images confirm circumferential thickening around the abdominal aorta and the presence of pathological tissue (arrow) (**3a**) lying in the pre-vertebral space, which shows a diffuse moderate FDG uptake (**3b**).

## Discussion

Retroperitoneal Fibrosis (RF) is a rare connective tissue disease with an annual prevalence of 1/100000 that occurs in people 40-60 years of age with a Males/Females ratio of 2:1 [1]. RF is characterized by the presence of fibrotic tissue with a chronic inflammatory cells infiltrate around the abdominal aorta and the common iliac arteries and even the ureters. In over 70% of cases, RF is defined as idiopathic. Identifiable causes (20-30%) include advanced malignant diseases such as lymphoma, sarcomas, multiple myeloma, carcinoid, gastrointestinal carcinomas; radiation therapy for retroperitoneal lesions; infectious organisms, including *Mycobacterium tuberculosis* and *Actinomyces*; drugs abuse especially derivatives of ergot alkaloids, such as methysergide and ergotamine [2]. Only two cases of RF following an episode of spondylodiscitis have been reported in the literature [3,4]. In both cases, as in our patient, spondylodiscitis

was diagnosed by vertebral bone biopsy. In the first case, RF was diagnosed during an episode of spondylodiscitis due to a *Prevotella* infection. After two months of antibiotic treatment, RF decreased with a clinically significant reduction of the associated symptoms. In the second case, as in our patient, the spondylodiscitis by *Mycobacterium tuberculosis* had occurred one year before the diagnosis of RF. In this patient, an ureterolysis was performed with subsequent placement of ureteral stents. But no pharmacological therapy was prescribed. At the subsequent follow up, a reduction in RF tissue was documented with an improvement of renal function.

Corticosteroids are the standard treatment for idiopathic forms of RF. Prednisone is usually the drug of choice and response to treatment appears greater in cases of IgG4-mediated RF. In the secondary forms of RF, on the other hand, the treatment strategy is essentially the removal of the cause [5]. Hence, the specific treatment and follow up for RF secondary to spondylodiscitis is not well known, also due to the small number of cases that have been reported. Regardless of the cause, however, regular follow-up monitoring should always be performed. A CT scan is usually done one month after the initiation of treatment, and then approximately every 4-6 months, to track changes in the extent of the fibrotic mass. Monitoring of renal function is also advised [5].

### Conclusion

Our patient developed an extensive RF two years after an episode of spondylodiscitis from *Escherichia coli* infection. RF is a rare disease and extremely variable in its presentation. In most cases, RF is idiopathic and can be managed with corticosteroids, especially if IgG4-mediated. RF secondary to spondylodiscitis are rare and poorly described in the medical literature. For these patients, resolution of the infection may not prevent the development of RF. The repeat of scans should be considered at regular intervals during the follow-up of these patients. A timely diagnosis of RF can prevent an irreversible kidney damage that is the main complication of this disease.

### Declaration

**Ethics approval:** This case concerns the medical management of a patient. All the procedures performed were in accordance with the ethical standards of the international ethics committee and with the 1964 Helsinki declaration and its later amendments.

**Author contributions collection and analysis of clinical data:** RC, MM, RB, GG. Analysis of imaging AC. Revision of the manuscript: RC, GG. Final approval of the manuscript: RC, MM, RB, AC, GG.

### References

1. Sica A, Casale B, Spada A, Di Dato MT, Sagnelli C, et al. Differential diagnosis: Retroperitoneal fibrosis and oncological diseases. *Open Med.* 2020; 15: 22-26.
2. Tanaka T, Masumori N. Current approach to diagnosis and management of retroperitoneal fibrosis. *Int J Urol.* 2020; 27: 387-394.
3. Salliot C, Lavie F, Azria A, Clerc D, Miquel A, et al. Retroperitoneal fibrosis secondary to spondylodiscitis after Infection with *Prevotella*. *J Rheumatol.* 2005; 32: 957-958.
4. Seth A, Ansari MS, Trikha V. Retroperitoneal fibrosis: A rare complication of Pott's disease. *J Urol.* 2001; 166: 622-623.
5. Zhao J, Li J, Zhang Z. Long-term outcomes and predictors of a large cohort of idiopathic retroperitoneal fibrosis patients: A retrospective study. *Scand J Rheumatol.* 2018; 00: 1-7.