



# Aneurysmal bone cyst of the fibular malleolus: Report of an additional case at rare site

Jean Marie Vianney Hope<sup>1\*</sup>; Mohamed Sidibe<sup>2</sup>; Jean Claude Sane<sup>3</sup>; Souleymane Diao<sup>2</sup>; Joseph Davy Diouf<sup>2</sup>; Anselme Noaga Nikiema<sup>2</sup>; Amadou Ndiassé Kassé<sup>2</sup>; Mouhamadou Habib Sy<sup>2</sup>

<sup>1</sup>Orthopedics and Trauma Surgery, Department of Rwanda Military Hospital (RMH), University of Rwanda, East Africa

<sup>2</sup>Orthopedics and Trauma Surgery, Department of Grand-Yoff General Hospital, Cheikh Anta Diop University of Dakar, Senegal

<sup>3</sup>Gaston Berger University of Saint-Louis, Senegal

## \*Corresponding Author(s): Jean MV Hope

Fellow West African College of Surgeons (FWACS), Orthopedics and Trauma Surgery, Department of Rwanda Military Hospital (RMH), University of Rwanda, East Africa

Tel: +250789364492, Fax: +250252586420,

ORCID ID: 0000-0003-1127-0586,

Email: zpawlak@xmission.com

## Abstract

Aneurysmal Bone Cyst (ABC) is a benign expansile lesions that may occur in any bone in the body, often affecting individuals during their second decade of life. In the modern English language literature, aneurysmal bone cyst occurring at the level of fibular malleolus is rare. Here, we report an additional such case arising from the fibular malleolus of a 16-year-old female patient successfully treated with en-bloc excision and ankle joint stabilization with tibiotalar joint arthrodesis by two cancellous screws and lateral ligament reconstruction.

Received: Nov 08, 2018

Accepted: Dec 12, 2018

Published Online: Dec 17, 2018

Journal: Journal of Orthopedics and Muscular System

Publisher: MedDocs Publishers LLC

Online edition: <http://meddocsonline.org/>

Copyright: © Hope JM (2018). This Article is distributed under the terms of Creative Commons Attribution 4.0 International License

## Introduction

As defined by the World Health Organization (WHO), the Aneurysmal Bone Cyst (ABC) is a benign tumor like lesion that is described as an expanding osteolytic lesion consisting of blood-filled spaces of variable size separated by connective tissue septa containing trabeculae or osteoid tissue and osteoclast giant cells [1,2]. It most often affects individuals during their second decade of life and may occur in any bone in the body [3,4,5,6]. However, it is generally considered rare, accounting for only 1-4% of all benign bone tumors [7]. The fibular localization is infrequent representing less than 7.3% of all ABCs [8]. The purpose of this study is to report an additional case of ABC of the fibular malleolus of a 16-year-old female patient treated with en-bloc excision and ankle joint stabilization.

## Case report

A 16-year-old girl with no pertinent past personal or family medical history presented with difficulty in movements of ankle joint and gradual distal right leg swelling since 6 months. She attributed these symptoms to a simple fall on her right ankle she sustained while walking. Physical examination was notable for limping and a mass of the lateral aspect of the distal one-fourth of the right leg. The mass was tender on palpation, hard in consistence, immobile in both planes; and hence clinically proving it was arising from the bone. It measured 8cm × 3 cm. Movements of the ankle joint were restricted due to pain. Blood investigations were in normal limits except slight increase in alkaline phosphatase at 167U/L.



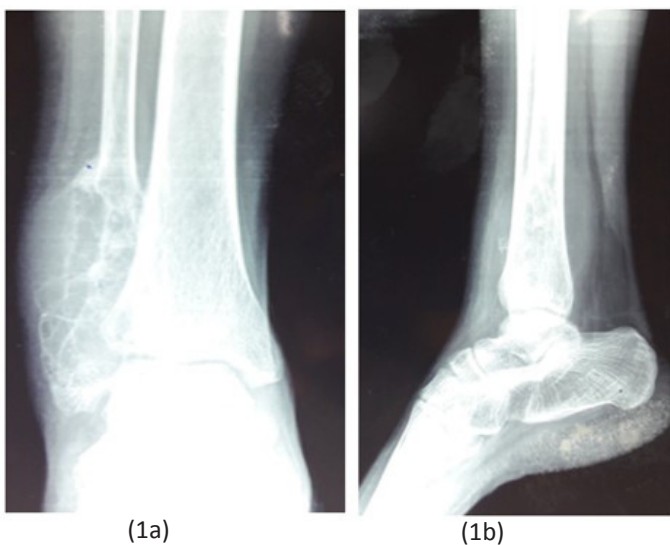
**Cite this article:** Hope JM, Sidibe M, Sane JC, Diao S, Diouf JD, et al. Aneurysmal bone cyst of the fibular malleolus: Report of an additional case at rare site. J Orthop Muscular Syst. 2018; 2: 1006.

Plain radiograph of the right ankle joint revealed an eccentrically placed expansile lytic lesion at distal end of fibula with extensive cortical thinning and multiple internal septations (Figure 1 a & b). Reconstructed sagittal and coronal Computed Tomography (CT) images were helpful in improved demonstration of some features, such as the cortical erosion, internal septations with calcified rim and eggshell appearance. Fluid-fluid levels can also be seen. No associated soft tissue mass was present (Figure 2 a & b).

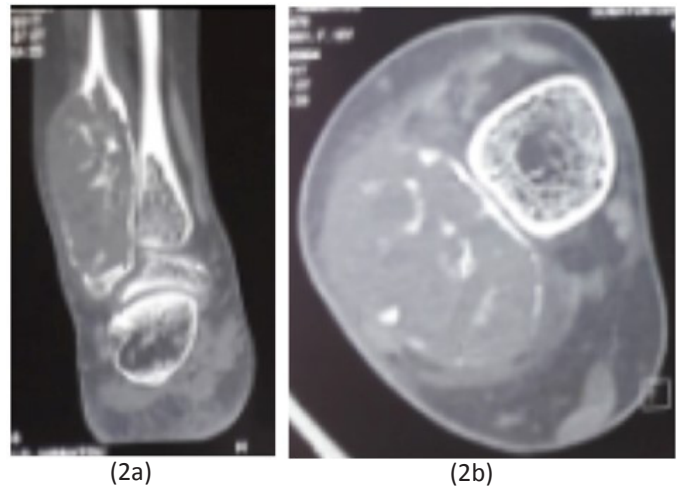
Biopsy was then carried out, and the specimen sent to the lab for histological examination. The gross appearance was that of a blood-soaked sponge surrounded by a thinned sub periosteal shell and containing cystic blood-filled cavities. The tissue within showed brownish intertwining septa. The stroma contained proliferative fibroblasts, spindle cells, areas of osteoid formation, and an uneven distribution of multinucleated giant cells that tended to surround the fluid-filled cavities in a “pigs at the trough” formation. Biopsy report also revealed the absence of malignant cells (Figure 3).

Under epidural anesthesia and tourniquet control, the patient was placed in supine position on operating table. The external approach centered on the lateral part of the middle of the fibula was performed. The skin incision begun to the lateral aspect of the middle of the leg and extended distally 1 cm below the end of lateral malleolus (Figure 4). She underwent en-bloc excision of the tumor and ankle joint stabilization by tibiotalar arthrodesis with two cancellous screws (Figure 5 a & b). The peroneus brevis tendon was transected proximally at its myotendinous junction and then sutured to the calcaneofibular and anterior talofibular ligaments in sequence and then tenodesed to the lateral distal tibia. No adjuvant therapy was administered. Postoperatively, the patient was immobilized in a cast for 6 weeks followed by gradual weight bearing of ankle joint. The patient made an eventful recovery with solid ankle joint fusion. The incision was by primary intension. The Musculoskeletal Tumor Society (MSTS) score was 94.7% and the American Orthopaedic Foot and Ankle Society (AOFAS) score was excellent. She was followed up to 5 years without recurrence.

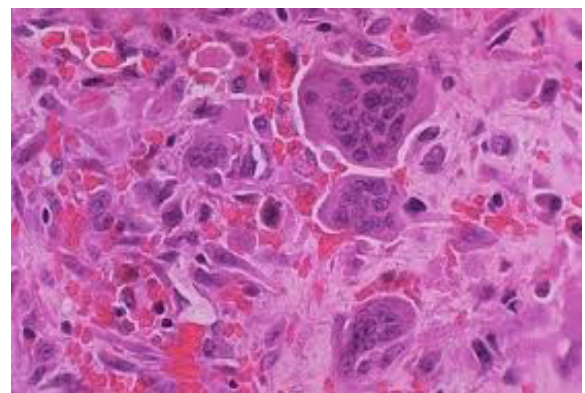
**Figures**



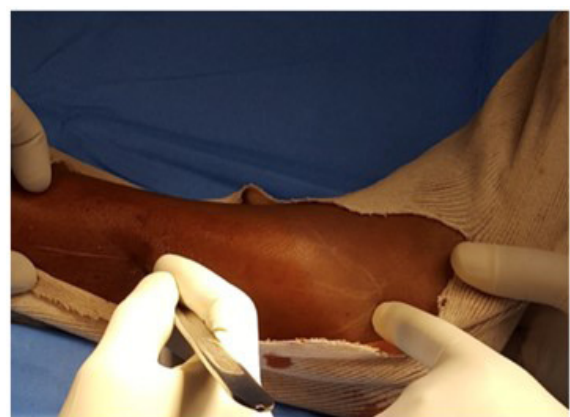**Figure 1:** Anteroposterior (1a) and lateral (1b) radiographs of the right ankle showing an eccentrically placed expanded osteolytic lesion of the fibular malleolus. It has well-defined margins and multiple internal



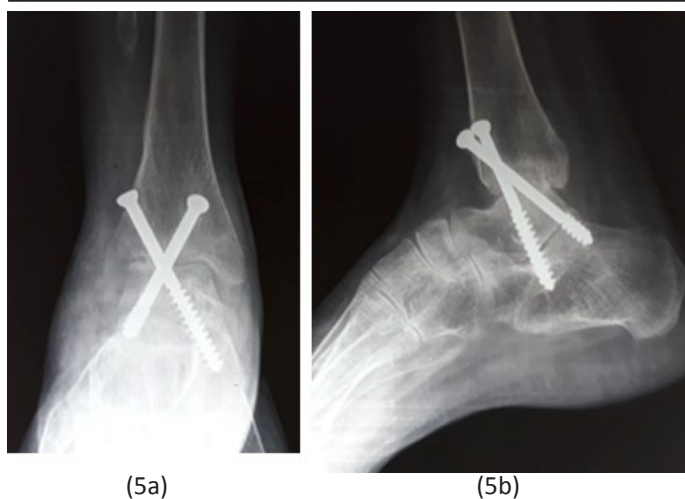
**Figure 2:** Reconstructed sagittal (2a) and coronal (2b) CT showing erosion of the margin of the expanded lesion, fluid-fluid levels, internal septations with calcified rim and eggshell appearance. No associated soft tissue mass was seen.



**Figure 3:** Photomicrograph of the excised ABC, at 40x magnification, showing highly vascular tumor with blood-filled spaces without endothelial lining. The tissue within shows intertwining septa. The stroma contains proliferative fibroblasts, spindle cells, areas of osteoid formation, uneven distribution of multinucleated giant cells that tend to surround the fluid-filled cavities in a “pigs at the trough” formation. No malignant cells are found.



**Figure 4:** Skin incision.



**Figure 5:** Anteroposterior (1a) and lateral (1b) postoperative radiographs showing the ankle joint arthrodesis with two cancellous screws.

### Discussion

Previously considered as a giant cell tumor variety, Jaffe and Lichtenstein first described ABC as its own entity in 1942, when they noted a peculiar blood-containing cyst of large size [9]. The true etiology and pathophysiology remain a mystery. Most investigators believe that ABCs are the result of a vascular malformation within the bone; however, the ultimate cause of the malformation is a topic of controversy. Three commonly theories are proposed. Firstly, ABCs occur as reaction secondary to another bony lesion including mainly giant cell tumors, fibrous dysplasia, osteoblastoma, chondromyxoid fibroma, non-ossifying fibroma, chondroblastoma, osteosarcoma, chondrosarcoma, unicameral or solitary bone cyst, hemangioendothelioma and metastatic carcinoma. ABCs in the presence of another lesion are called secondary ABCs. Secondly, ABCs may arise de novo; those that arise without evidence of another lesion are classified as primary ABCs. Thirdly, ABCs may arise in an area of previous trauma as results of either arteriovenous fistulas, venous blockage or local hemorrhage that initiates the formation of reactive osteolytic tissue [4,10,11,12,13]. The third theory may explain the occurrence of ABC in our case.

The age distribution of those with ABC is distinct, with the majority of lesions occurring in skeletally immature patients. It most often affects individuals during their second decade [3,4,5,6,14]. Some authors reported sex predilection with female predominance [15,16]. These findings concur with our case (16 years old female patient). Patients with an ABC usually present with pain, a mass, swelling, a pathologic fracture, or a combination of these symptoms in the affected area. The symptoms are usually present for several weeks to months before the diagnosis is made, and the patient may also have a history of a rapidly enlarging mass [17,18,19]. This is in line with our case who presented with pain, swelling and limited range of motion of the ankle joint over 6 months.

ABCs may affect any bone in the body; the long tubular bones being the most common sites, followed by the spine and the flat bones. In a published review of 897 cases of ABC, the reported rates of occurrence were high in tibia (17.5%), followed by femur (15.9%), vertebra (11.2%), pelvis (11.6%) and humerus (9.1%) while fibular localization represent 7.3% [8]. Other few cases of fibular localization have been reported [20,21,22,23]. Lesion at distal end of fibula is definitely a rare entity as pre-

sented in our case.

Radiographic findings usually consist of an eccentric lesion that appears cystic or lytic. Images may show expansion of the surrounding bone with a blown-out, ballooned, or soap-bubble appearance. Some views may show an eggshell-appearing bony rim surrounding the lesion. One may see the cystic spaces and, rarely, partially ossified septa [24]. These radiological findings have been found in our case. Capanna et al [25] described five morphologic types of ABC on the basis of radiographic findings whereas Lodwick radiographic grading with bone destruction distinguishes three grades [26]. The staging system of benign musculoskeletal neoplasms adopted by the Musculoskeletal Tumor Society (MSTS) was described by Enneking in 1986, who classified benign lesions into three broad categories with stage 1: latent (inactive); stage 2: active and stage 3: aggressive [27]. On the basis of radiographic findings, our case was classified Capanna morphologic type V and Lodwick grade III. Based on broad categories of Enneking, it was described as stage 2.

Some authors [22,28] have stressed the importance of physal preservation in the treatment of aneurysmal bone cysts even if lesions are likely to recur. By contrast, when a fibular location is considered, the expression “expendable bone” is sometimes used, justifying more aggressive treatment [28]. But, the mainstay of treatment has been intralesional curettage. Other surgical options include selective arterial embolization, and curettage with locally applied adjuvants such as liquid nitrogen, argon beam photocoagulation, or phenol [29,30]. The main reconstructive problems after resection are restoration of fibular length and instability of the ankle [21,22]. In our case, we performed en-bloc excision of the entire distal fibula. Stabilization of the tibiotalar joint was done by tibiotalar joint arthrodesis by two cancellous screws. We furthermore performed the reconstitution of lateral ligaments. No recurrence was seen after 5 years.

### Conclusion

We report an additional rare case of Aneurysmal Bone Cyst (ABC) arising from fibular malleolus of a 16-year-old female patient successfully treated with en-bloc excision and ankle joint stabilization with tibiotalar joint arthrodesis by two cancellous screws and lateral ligament reconstruction. The clinical and imaging features alone are non-specific, and the definitive diagnosis relies on pathological examination.

### Acknowledgement

We wish to thank Miss Larissa Musaninyange Mahoro for her support with English language editing.

### Ethical Approval

This article does not contain any studies with human participants or animals performed by any of the authors.

### Informed Consent

The informed consent was obtained from the child’s parents to publish the information, including his photograph.

### References

1. Leithner A, Windhager R, Lang S, Haas OA, Kainberger F, et al. Aneurysmal bone cyst. A population based epidemiologic study and literature review. *Clin Orthop Relat Res.* 1999; 6: 176-179.
2. Schajowicz F. Aneurysmal bone cyst. *Histologic Typing of Bone*



- Tumors. Berlin: Springer-Verlag. 1992; 37.
3. Brastianos P, Gokaslan Z, McCarthy EF. Aneurysmal bone cysts of the sacrum: a report of ten cases and review of the literature. *Iowa Orthop J.* 2009; 29: 74-78.
  4. Elangovan C, Kumar MS, Inigo A, Kasim A, Ram SM. Aneurysmal bone cyst secondary to giant cell tumor of bone: a case report. *Tejms.* 2011; 2: 38-40.
  5. Rapp TB, Ward JP, Alaia MJ. Aneurysmal bone cyst. *J Am Acad Orthop Surg.* 2012; 20: 233-241.
  6. Sun ZJ, Zhao YF, Yang RL, Zwahlen RA. Aneurysmal bone cysts of the jaws: analysis of 17 cases. *J Oral Maxillofac Surg.* 2010; 68: 2122-2128.
  7. Cottalorda J, Kohler R, Sales de Gauzy J, Chotel F, Mazda K, et al. Epidemiology of aneurysmal bone cysts in children: a multicentre study and literature review. *J Pediatr Orthop B.* 2004; 13: 389-394.
  8. Schreuder HW, Veth RP, Pruszczynski M, Lemmens JA, Koops HS, et al. Aneurysmal bone cysts treated by curettage, cryotherapy and bone grafting. *J Bone Joint Surg Br.* 1997; 79: 20-25.
  9. Jaffe HL, Lichtenstein L. Solitary unicameral bone cyst with emphasis on the roentgen picture, the pathologic appearance and the pathogenesis. *Arch Surg.* 1942; 44: 1004-1025.
  10. Kransdorf MJ, Sweet DE. Aneurysmal bone cyst: concept, controversy, clinical presentation, and imaging. *AJR Am J Roentgenol.* 1995; 164: 573-580.
  11. Cottalorda J, Bourelle S. Modern concepts of primary aneurysmal bone cyst. *Arch Orthop Trauma Surg.* 2007; 127: 105-114.
  12. Biesecker JL, Marcove RC, Huvos AG, Mike V. Aneurysmal bone cysts: a clinicopathologic study of 66 cases. *Cancer.* 1970; 26: 615-625.
  13. Szendrői M, Cser I, Konya A, Renyi-Vamos A. Aneurysmal bone cyst: a review of 52 primary and 16 secondary cases. *Arch Orthop Trauma Surg.* 1992; 111: 318-322.
  14. Mohamed OA. Outcome of aneurysmal bone cysts treated by extended curettage, cryosurgery and bone grafting. *IJOS.* 2015; 1: 09-14.
  15. Campanaeei M, Capanna R, Picci P. Unicameral and aneurysmal bone cysts. *Clin Orthop.* 1986; 204, 25-36.
  16. Gibbs CP, Hefele MC, Peabody TD, Montag AG, Aithal V, et al. Aneurysmal bone cyst of the extremities. Factors related to local recurrence after curettage with high-speed burr. *J Bone Joint Surg AM.* 1999; 81-A: 1671-1678.
  17. Clayer M. Injectable form of calcium sulphate as treatment of aneurysmal bone cysts. *ANZ J Surg.* 2008; 78: 366-370.
  18. Segall L, Cohen-Kerem R, Ngan BY, Forte V. Aneurysmal bone cysts of the head and neck in pediatric patients: a case series. *Int J Pediatr Otorhinolaryngol.* 2008; 72: 977-983.
  19. Burch S, Hu S, Berven S. Aneurysmal bone cysts of the spine. *Neurosurg Clin N Am.* 2008; 19: 41-47.
  20. Cottalorda J, Kohler R, Sales de Gauzy J, Chotel F, et al. Epidemiology of aneurysmal bone cysts in children: a multicenter study and literature review. *J Pediatr Orthop B.* 2004; 13: 389-394.
  21. Kumar VA, Naidu MJ, Mandava B. Aneurysmal bone cyst of distal fibula treated with en-bloc excision and ligamentous ankle stabilization: a rare case report. *IOSR-JDMS.* 2015; 14: 39-41.
  22. Lampasi M, Magnani M, Donzelli O. Aneurysmal bone cysts of the distal fibula in children. Long-term results of curettage and resection in nine patients. *J Bone Joint Surg.* 2007; 89: 1356-1362.
  23. Yu GV, DPM, Roth LS, Sellers CS. Aneurysmal bone cyst of the fibula. *J Foot Ankle Surg.* 1998; 37: 426-436.
  24. Boubbou M, Atarraf K, Chater L, Afifi A, Tizniti S. Aneurysmal bone cyst primary - about eight pediatric cases: radiological aspects and review of the literature. *Pan Afr Med J.* 2013; 15: 111.
  25. Capanna R, Bettelli G, Biagini R, Ruggieri P, Bertoni F, et al. Aneurysmal cysts of long bones. *Ital J Orthop Traumatol.* 1985; 11: 409-417.
  26. Lodwick GS. Radiographic diagnosis and grading of bone tumors with comments on computer evaluation. Presented at the Proceedings of the Fifth National Cancer Conference. Philadelphia. 1964; 17-19.
  27. Enneking WF. A system of staging musculoskeletal neoplasms. *Clin Orthop Relat Res.* 1986; 204: 9-24.
  28. Tsagozis P, Brosjö O. Current strategies for the treatment of aneurysmal bone cysts. *Orthop Rev.* 2015; 7: 106-110.
  29. Flont P, Kolacinska-Flont M, Niedzielski K. A comparison of cyst wall curettage and en bloc excision in the treatment of aneurysmal bone cysts. *World J Surg Oncol.* 2013; 11: 109.
  30. Oliveira MBDR, Meohas W, Carvalho GSDC, Rodrigues RR, Oliveira FCR, et al. Primary aneurysmal bone cyst of long bones treated with a single dose of calcitonin and methylprednisolone percutaneous intralesional injection: a case series and literature review. *J Orthop Oncol.* 2016; 3: 1-6.