



A Case of Ovarian Borderline Clear Cell Adenofibroma with Associated Granulosa Cell Tumour

Jack Heard¹; Mathieu Viau¹; Gabor Fischer^{3,4}; Nazila Azordegan^{3,4}; Gary Keeney⁵; Alon D Altman^{1,4,6*}

¹Department of Obstetrics Gynecology & Reproductive Sciences, University of Manitoba.

²Department of d'obstetrique et de gynecologie, Service d'oncologie gynécologique, Universite de Sherbrooke.

³Department of Pathology, University of Manitoba.

⁴Faculty of Health Sciences, University of Manitoba.

⁵Department of Laboratory Medicine and Pathology, Mayo Clinic.

⁶Research Institute of Oncology and Hematology (RIOH), Division of Gynecologic Oncology, Cancer Care Manitoba.

*Corresponding Author(s): Alon D Altman

Department of Obstetrics, Gynecology and Reproductive Sciences 820 Sherbrook Street Winnipeg, Manitoba, Canada R3A 1R9.

Tel: 1-204-787-3684 & 1-204-787-2314;

Email: alon.altman@cancercare.mb.ca

Abstract

A 63-year-old female was found to have an ovarian tumour during workup for microscopic hematuria. Histologic analysis after bilateral salpingo-oophorectomy revealed a borderline clear cell adenofibroma with focal microinvasion and associated granulosa cell tumour. There was no adjuvant chemotherapy or radiation therapy. Borderline clear cell carcinomas alone are rare and no cases of combined clear cell borderline tumour with granulosa cell tumour have been described in the literature to our knowledge. Review of evidence for treatment of each tumour alone suggests surgical excision as primary treatment, but recurrence rates of a combined tumour such as this are not known so long-term follow-up cannot be excluded.

Received: June 07, 2023

Accepted: June 16, 2023

Published Online: June 23, 2023

Journal: Journal of Gynecology Case Reports

Publisher: MedDocs Publishers LLC

Online edition: <http://meddocsonline.org/>

Copyright: © Altman AD (2023). *This Article is distributed under the terms of Creative Commons Attribution 4.0 International License*

Keywords: Borderline ovarian clear cell adenofibroma; Granulosa cell tumour; Case report.

Introduction

Borderline Ovarian Tumours (BOT) are epithelial ovarian tumours with more upregulated growth and cellular atypia than benign tumours, but do not have the destructive stromal invasion seen in invasive ovarian cancers [1]. Most BOTs are found in early stages and represent about 15% of all epithelial ovarian tumours [1,2]. Six histologic subtypes have been identified, the most common being serous and mucinous BOT.[1] Other subtypes include endometrioid, clear cell, seromucinous, and Brenner or transitional cell [1].

Most clear cell tumours of the ovary are overtly malignant, with less than 1% of all BOT being clear cell tumours [3]. Borderline clear cell tumours are composed of glands or cysts with cuboidal, flat, or hobnail cells with moderate nuclear atypia but no stromal invasion [1]. Granulosa Cell Tumours (GCT) are sex-cord stromal tumours of the ovary, accounting for less than 5% of all malignant ovarian tumours [4]. Given that these two tumours have never been reported to occur simultaneously in the same ovary, we present a case to describe the clinical behaviour and pathologic characteristics of this tumour.



Cite this article: Altman AD, Heard J, Viau M, Fischer G, Azordegan N, et al. A Case of Ovarian Borderline Clear Cell Adenofibroma with Associated Granulosa Cell Tumour. *J Gynecol Case Rep.* 2023; 2(1): 1008.

Case Presentation

A 63-year-old Caucasian female was found to have an ovarian mass after being investigated for microscopic hematuria. She had a history of hypertension and no surgical history. She had no family history of cancer, no smoking history, was postmenopausal with no hormone replacement therapy or bleeding. Normal Pap smear history, the last being 2 years previously.

Investigations started with an ultrasound showing an incidental 6cm heterogenous right adnexal mass, with non-shadowing bright speckles. CA-125 was elevated at 57.

A pelvic MRI confirmed an adnexal mass arising from the right ovary measuring 7.4 x 7.5 x 8.1cm. The mass was solid and characteristics were most in keeping with a fibrous tumour of the ovary.

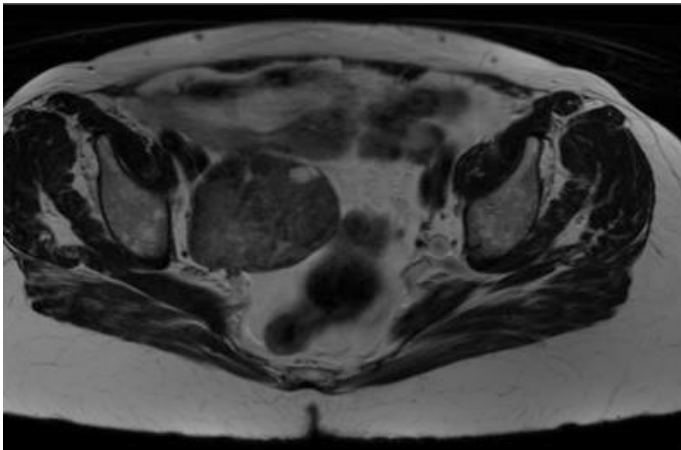


Figure 1: MRI shows a solid mass in the right adnexa.

The patient underwent a bilateral salpingo-oophorectomy and pelvic washings by laparotomy. A 12 x 8cm multinodular solid right adnexal mass was removed. The uterus appeared normal and was left in situ as per previous discussion with patient. There was no ascites or peritoneal thickening and the upper abdomen appeared normal.

Pathology revealed a 9 x 7.5 x 7cm firm, yellow-tan coloured mass. The surface was smooth and slightly nodular. A 1.6cm cyst containing clear yellow fluid was identified. The bulk of the tumour appeared to be an adenofibroma with no normal ovarian tissue seen on pathology. There were areas showing small glands lined by cells that range from flattened, cuboidal, to hobnail in appearance. Cytologic atypia was present. Majority of the tumour had the appearance of a borderline clear cell adenofibroma, with areas of microinvasion.

Areas of this adenofibroma showed granulosa cell differentiation with diffuse proliferation of rounded stromal cell clusters separated by a reticulin network. The overall impression was that this was a diffuse variant of granulosa cell tumour, combined with borderline clear cell adenofibroma. The slides were reviewed in external subspecialist consultation for confirmation.

All washings were negative for malignancy and the left ovary and fallopian tube had no evidence of neoplastic proliferation.

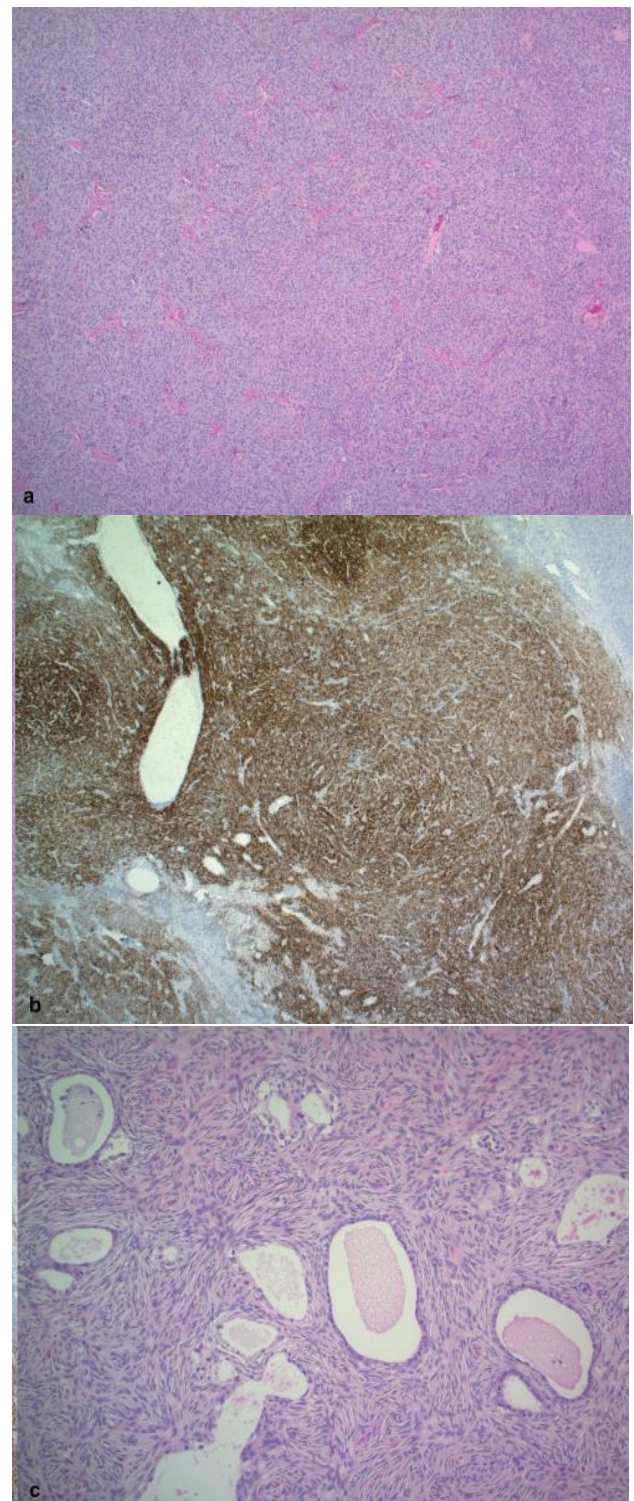


Figure 2: (a) Hematoxylin and Eosin (H&E) of granulosa cell tumour component. (b) Inhibin staining of granulosa cell tumour component. (c) Borderline clear cell adenofibroma component of tumour.

Post operatively, the patient's CA-125 decreased to 18.

Decision was made for no further adjuvant treatment in this case. The patient remains asymptomatic with no signs of disease recurrence 3 years post-surgery.

Discussion

With 75% all BOT being found primarily in FIGO stage 1, surgery alone is often curative with no need for adjuvant chemotherapy [1]. One case series including 12 clear cell borderline tumours found all cases as FIGO stage 1 and only a single case of bilateral ovarian involvement [5].

There is an association with cell tumours and endometriosis [1,6,7]. It has been proposed that clear cell BOT may have a progressive course from endometriosis to borderline to invasively malignant disease [7,8]. A high number of cases are associated with a foci of frank clear cell carcinoma and share similar immunohistochemistry profiles, thus the proposed progressive history [1]. Microinvasion as seen in our case is stromal invasion < 5mm in the greatest linear dimension, regardless of the number of microinvasive foci [1]. Microinvasion alone has no adverse effect on prognosis and is not an indication for adjuvant chemotherapy, but thorough sampling and immunohistochemical testing is recommended to rule out any areas of frankly invasive carcinoma [1].

Granulosa cell tumours have been managed similarly with surgical excision. Surgery can be conservative or fertility sparing in nature if no obvious advanced cancer is apparent, but in advanced disease optimal cytoreductive surgery is key for improved prognosis [4]. Most cases are unilateral and confined to the ovaries with 90% identified in stage 1. It is not associated with endometriosis. Both borderline clear cell and granulosa cell tumours typically present in postmenopausal women and have favourable prognosis [1,5]. The overall 5-year survival for patients with granulosa cell tumours is above 80% [9]. Recurrence of GCT can occur many years down the road with some presenting 20 to 30 years after initial surgery [10].

Conclusion

We presented a rare case of borderline clear cell adenofibroma with diffuse granulosa cell changes. At this time, review of literature suggests that this is the first case with concomitant clear cell BOT and granulosa cell tumors. Based on known pathogenesis, this may be a coincidental finding, but due to the rarity of both tumours, an association cannot be completely excluded. While surgery is likely curative, long-term follow-up cannot be omitted as there is some evidence that recurrence can occur with both clear cell BOT and GCT.

References

1. S Hauptmann, K Friedrich, R Redline, S Avril. 'Ovarian borderline tumors in the 2014 WHO classification: Evolving concepts and diagnostic criteria', *Virchows Arch.* 2017; 470: 125-142.
2. I Skirnisdottir, H Garmo, E Wilander, L Holmberg, 'Borderline ovarian tumors in Sweden 1960-2005: Trends in incidence and age at diagnosis compared to ovarian cancer', *Int. J. Cancer.* 2008; 123: 1897-1901.
3. P Kleebkaow, A Aue-aungkul, A Temtanakitpaisan, C Kietpeera-kool. 'Borderline Clear Cell Adenofibroma of the Ovary', *Case Rep. Pathol.* 2017; 2017: 1-4.
4. GCE Stuart, LM Dawson, 'Update on granulosa cell tumours of the ovary', *Curr.Opin. Obstet. Gynecol.* 2003; 15: 33-37.
5. C Uzan, M Dufeu-Lefebvre, R Fauvet, S Gouy, P Duvillard, et al, 'Management and prognosis of clear cell borderline ovarian tumor', *Int. J. Gynecol. Cancer.* 2012; 22: 993-999.
6. J. J. Wei, J. William, and S. Bulun, 'Endometriosis and ovarian cancer: A review of clinical, pathologic, and molecular aspects', *Int. J. Gynecol. Pathol.* 2011; 30: 553-568.
7. SM Vasenwala, HA Ansari, N Haider. 'Atypical Proliferating Clear Cell Adenofibroma of the Ovary : A Case Report', *Middle East J. Cancer.* 2013; 4: 87-90.
8. JL Liu, PY Chu, KT Yeh, RH Huang. 'Borderline clear cell adenofibroma with extensive hemorrhagic necrosis', *Hematol. Oncol. Stem Cell Ther.* 2010; 3: 158-160.
9. R. Tamura et al., 'Presentation of two patients with malignant granulosa cell tumors, with a review of the literature', *World J. Surg. Oncol.* 2012; 10: 2-6.
10. YC Chen, LC Chang, RS Soong, 'A late recurring and easily forgotten tumor: Ovarian granulosa cell tumor', *World J. Surg. Oncol.* 2012; 10: 2-5.