



# Ultrasonography Findings in Self-Induced Eye Trauma

**Bela P Delvadia BS<sup>1</sup>; Jessica McCann<sup>2</sup>; Zeba A Syed MD<sup>1,3</sup>**

<sup>1</sup>Cornea Service, Wills Eye Hospital, Philadelphia, PA, USA.

<sup>2</sup>Diagnostic Center, Wills Eye Hospital, Philadelphia, PA, USA.

<sup>3</sup>Sidney Kimmel Medical College, Thomas Jefferson University, Philadelphia, PA, USA.

**\*Corresponding Author(s): Zeba A Syed**

Assistant Professor of Clinical Ophthalmology, Sidney Kimmel Medical College, Thomas Jefferson University, Cornea Service, Wills Eye Hospital, 840 Walnut Street, Suite 920, Philadelphia, PA 19107, USA  
Tel: +1-215-928-3180; Email: zsyed@willseye.org

Received: Sep 03, 2020

Accepted: Oct 12, 2020

Published Online: Oct 16, 2020

Journal: Journal of Clinical Images

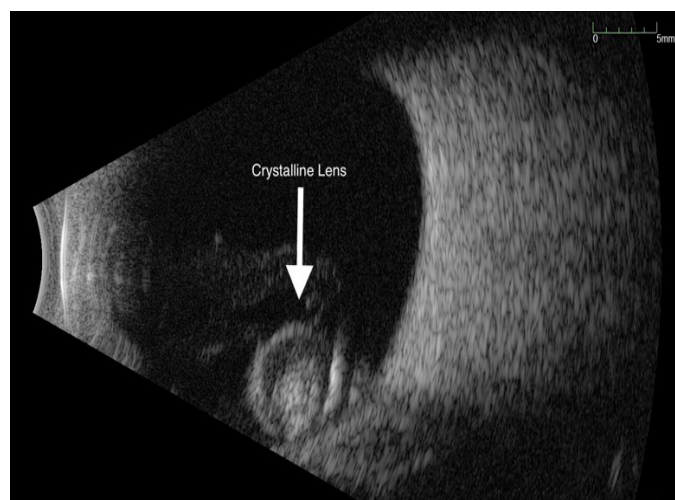
Publisher: MedDocs Publishers LLC

Online edition: <http://meddocsonline.org/>

Copyright: © Syed ZA (2020). *This Article is distributed under the terms of Creative Commons Attribution 4.0 International License*

## Clinical image description

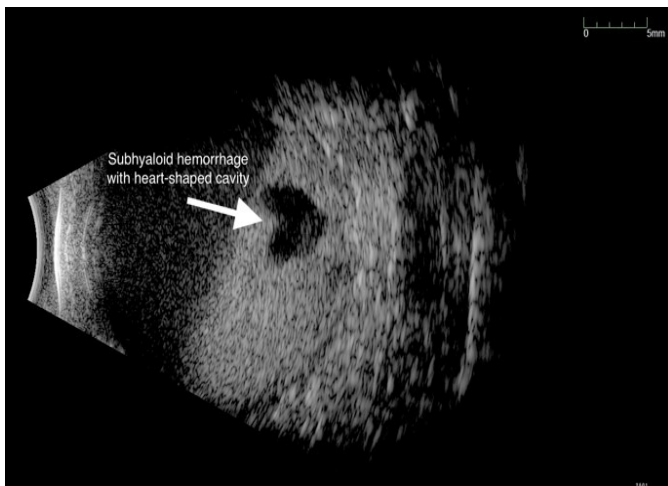
A 54-year-old developmentally delayed male exhibiting aggressive eye rubbing behavior presented to the Wills Eye Hospital comprehensive ophthalmology clinic for an eye examination. The patient had a known history of keratoconus and diabetes. Due to behavioral limitations, we were unable to determine the patient's visual acuity in the outpatient clinic. The patient was subsequently transferred to the operating room for an examination under anesthesia. Intraocular pressures were 20 mmHg in the right eye and 17 mmHg in the left eye. B-scan ultrasonography of the right eye demonstrated a crystalline lens in the vitreous cavity (Figure 1),



**Figure 1**



As the lens had become displaced secondary to self-induced eye trauma. B-scan ultrasonography of the left eye revealed a subhyaloid hemorrhage with an incidentally-noted heart-shaped cavity (Figure 2), also likely secondary to self-injurious behavior.



**Figure 2**