



# Total Elbow Implant in Adolescents

**\*Corresponding Author(s): Landino Cugola**

Department of Hand Surgery Unit, Ospedale Pederzoli,  
Peschiera del Garda (VR), Italy.  
Email: landino.c@hotmail.it

**Abstract**

A destroyed elbow with severely limited-without function and/or pain in adolescents can be treated by resection arthroplasty but not always the results are satisfactory like expected, because joint surfaces remain painful, incongruent and instable. The question should be: could be reasonable to implant a prosthesis?.

We refer three cases treated in this manner considering other alternatives not available.

Received: June 11, 2023

Accepted: June 23, 2023

Published Online: June 30, 2023

Journal: Journal of Clinical Images

Publisher: MedDocs Publishers LLC

Online edition: <http://meddocsonline.org/>

Copyright: © Cugola L (2023). *This Article is distributed under the terms of Creative Commons Attribution 4.0 International License*

**Keywords:** Elbow arthroplasty; Prosthesis; Teen-agers.

**Introduction**

In case of elbow destruction, as first choice, may be done an excision arthroplasty with interposition of cutis, lyodura or the like, but rehabilitation is generally demanding and time-consuming, less comfortable and uncertain outcome. The rate of residual pain can be high. Then, can a prosthetic implant be a reasonable alternative to biological arthroplasty in adolescents? This choice include the fact that an implanting operation is easier than biological athroplasty, the rehabilitation less painful and the recovery is faster and an elbow more stable and has a wider Range Of Motion ( ROM). The drawbacks, instead, could include the fact that it can potentially translate to less professional opportunities in the future, the implant duration and what to do in case of revision: New implant or arthodesis or other solution.

In literature no publication is reported on this topic [1-5].

**Material and Methods**

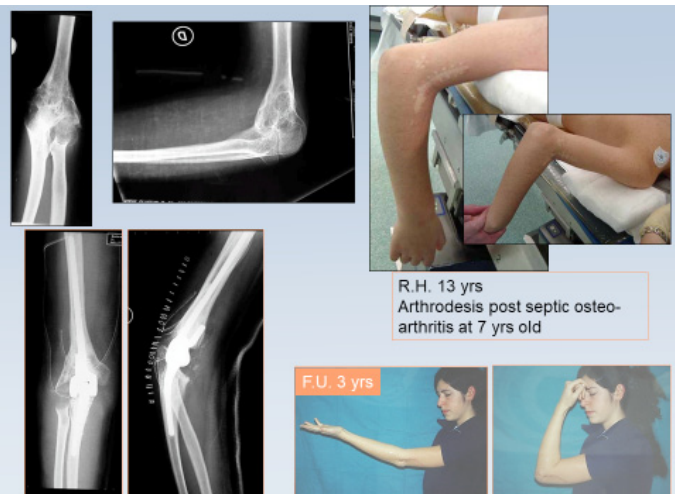WE have treated 3 cases with Morrey (2) and Discovery ( 1) implants.

First was girl 13 y. old (case 1) with stiff-ankilosed right elbow at 90° post septic osteoarthritis suffered at 7 years. To follow-up at 3 years ROM was 120° in flexion and -15° in extension.

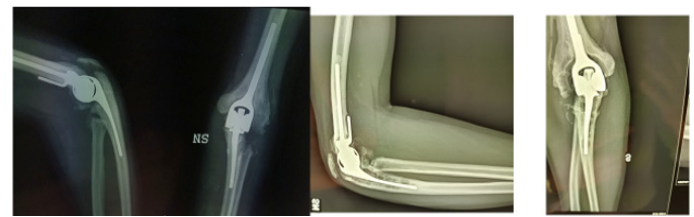
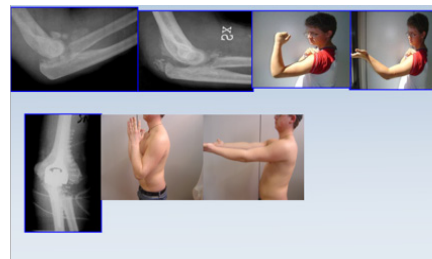Second patient (case 2): 14 years old boy with postraumatic stiff elbow treated by Morrey implant (injured 3 years before). At the follow-up, after 3 years, recovery was ROM 0°-80° painless.

Last patient: 15 years old boy, with destroyed joint in painful subluxated left elbow (complex trauma 2 years before) treated by Discovery implant. At follow-up, after 15 years, recovery was almost complete without pain. But after 17 years post-implant the elbow became slightly painful under strain. The x-rays show loosening in ulnar component: Frequent monitorings of the evolution will indicate what to do!.





Case 1



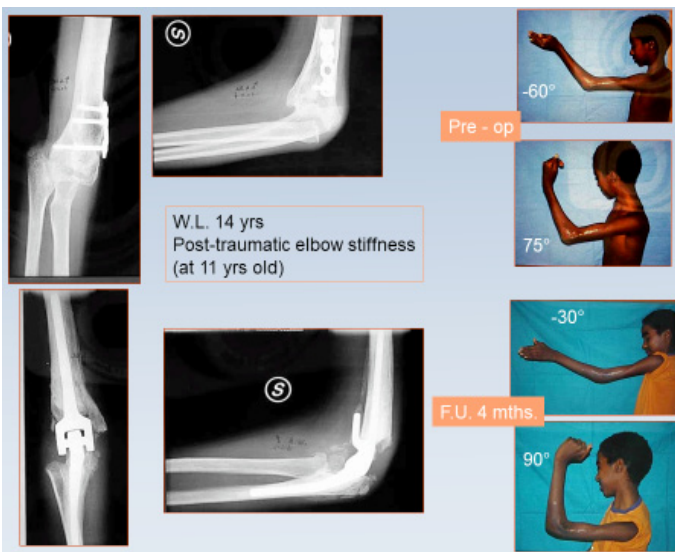
Case 3: X-ray and clinical pictures preoperative and postoperative implant. Below: Radiographic control at 15 years-no loosening; at 17 years-loosening in ulnar component.

### Conclusion

The question of the best way to treat a destroyed elbow in adolescents is: a-biological arthroplasty or b-prosthetic implant?. This still a matter of discussion. Because unsatisfactory results in our experience (also in literature-Lanzerath) with biological arthroplasty, we have choiced a prosthesis.

### Reference

1. Vollans S, Lim D. Elboww replacement for elective conditions. Orthopaedics and Trauma. 2016; 30: 322-328.
2. Cheung EV, O Driscoll SW. Total elbow prosthesis loosening caused by ulnar component pistoning. JBJS. 2007; 89: 1269-1274.
3. Ibrahim EF, Rashid A, Thomas M. Linked semiconstrained and unlinked total elbow replacement in juvenile idiopathic arthritis: A case comparison series with mean 11.7-year follow-up. Shoulder and Elbow Surg. 2017; 26: 305-313.
4. Hanninen P, Niinimakit T, Flinkkila T. Discovery elbow system:clinical and radiological results after 2-to 10-year follow-up. Eur J Orthop Surg Traumatol. 2017; 27: 901-907.
5. Lanzerath F, Hackl M, Pucher CJ, Leschinger T, Uschok S, et al. Interposition arthroplasty for post-traumatic osteoarthritis of the elbow: A systematic review. Int Orthop. 2022; 46: 2603-2610.



Case 2