



Stercoral Colitis: A Potentially Fatal Condition

Louis Costanzo*; Brian Soto

Department of Internal Medicine, State University of New York, Downstate - Health Science University, Brooklyn, NY, USA – 11203.

***Corresponding Author(s): Louis Costanzo**

Department of Internal Medicine, State University of New York, Downstate - Health Science University, Brooklyn, NY, USA – 11203.

Email: louis.costanzo@downstate.edu & louiscostanzo.med@gmail.com

Received: Jun 29, 2021

Accepted: Jul 21, 2021

Published Online: Jul 23, 2021

Journal: Journal of Clinical Images

Publisher: MedDocs Publishers LLC

Online edition: <http://meddocsonline.org/>

Copyright: © Costanzo L (2021). *This Article is distributed under the terms of Creative Commons Attribution 4.0 International License*

Clinical image description

A 24-year-old female with active tuberculosis presented to the ED with worsening respiratory symptoms, rapid weight loss, and chronic constipation. She had no recent solid PO intake and did not recall her last bowel movement. She appeared significantly cachectic with a BMI of 10kg/m². Patient had a scaphoid abdomen with no localized distension or tenderness. She was ultimately found to have multi-organ failure secondary to disseminated tuberculosis; as well as stercoral colitis. Axial and sagittal computed tomographic images of the abdomen and pelvis were taken (Figures 1 and 2); which showed a stool filled rectal vault (red arrow) with rectal mural thickening and an edematous colonic wall (yellow arrow).

Stercoral colitis is a rare type of inflammatory colitis which occurs when impacted fecal matter causes increased colonic intraluminal pressure; that of which can interrupt blood flow. While this condition is most often seen in elderly patients, it may present in younger patients with chronic constipation due to opioid use, neurologic conditions, muscular disorders, or shock. Patients may be asymptomatic during early stages; however, complications include ulceration and colonic perforation. Therefore, this condition must be treated urgently with manual disimpaction or laxatives if there are no signs of bowel perforation or ischemia. Decompression of the rectum and surgical intervention are indicated if there is evidence of peritonitis or pressure necrosis.



Figure 1

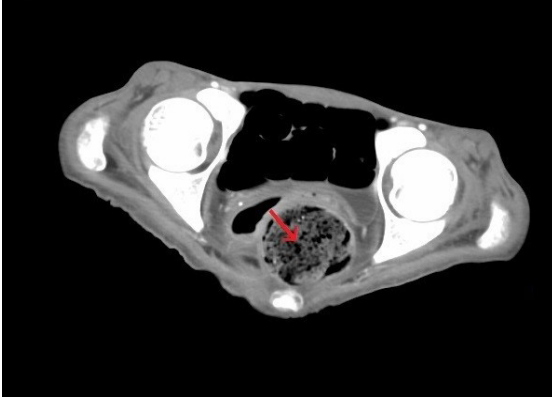


Figure 2

