



Man with Hoarseness after Falling

***Corresponding Author(s): Piyachat Sasipattarapong**

Department of Emergency Medicine, Khon Kaen
Hospital, Thailand.

Email: p.sasipattarapong@gmail.com

Received: Feb 01, 2022

Accepted: Feb 24, 2022

Published Online: Feb 28, 2022

Journal: Journal of Clinical Images

Publisher: MedDocs Publishers LLC

Online edition: <http://meddocsonline.org/>

Copyright: © Sasipattarapong P (2022). *This Article is distributed under the terms of Creative Commons Attribution 4.0 International License*

Introduction

A 44-year-old man presented to the emergency department after falling down and hitting his neck directly to the shaft of a tractor. He complained of hoarseness, odynophagia and difficulty breathing. On physical examination, he had normal vital signs. His neck was swollen without crepitus, stridor or pharyngeal erythema. Cervical ultrasonography revealed soft tissue swelling on the left aryepiglottic fold and decreased mobility of the left vocal cord (Figure 1 and video 1). Computed tomography of the neck demonstrated a high-density lesion close to the left side of larynx involving left true vocal cord (Figure 2).

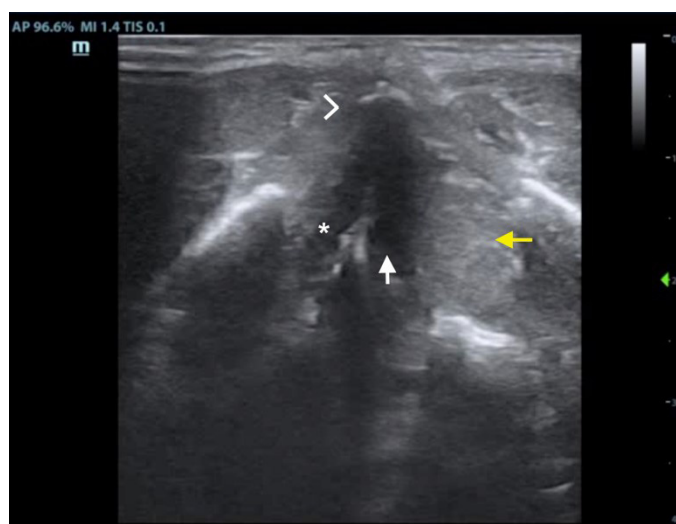


Figure 1: Transverse ultrasound image at the level of the vocal cords demonstrating a normal thyroid cartilage (arrowhead), normal right vocal cord (asterisk) and a soft tissue swelling consistent with hematoma (yellow arrow) lateral to the left vocal cord (white arrow).

Cite this article: Sasipattarapong P. Man with Hoarseness after Falling. J Clin Images. 2022; 5(1): 1114.



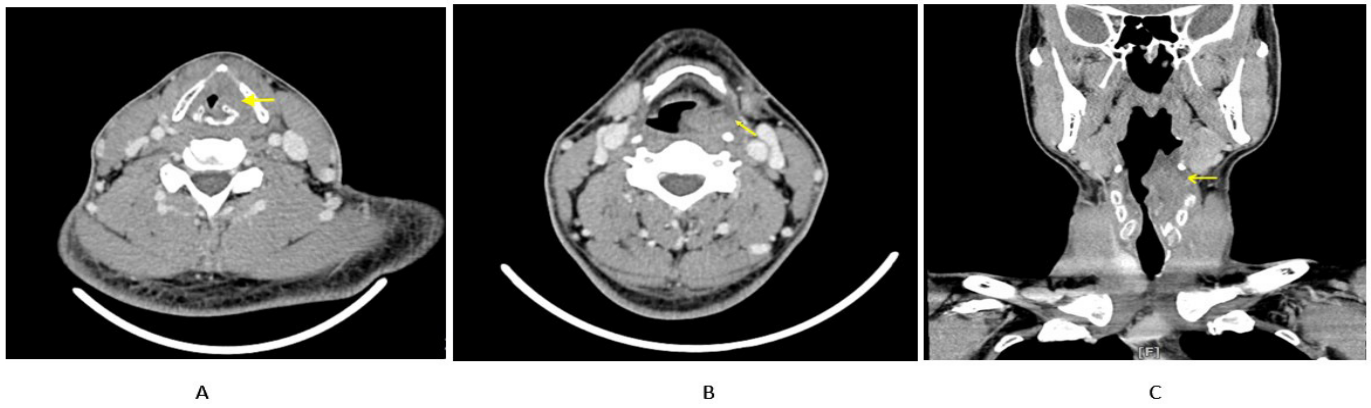


Figure 2: (a) Axial contrast-enhanced CT neck shows a 2.4 x 2 x 4.1-cm slightly high density lesion favored to represent hematoma or edema (arrow) close to the left side of larynx involving the left true vocal cord at glottic level. (b) Axial contrast-enhanced CT neck shows a 2.4 x 2 x 4.1-cm slightly high density lesion favored to represent hematoma or edema (arrow) close to the left side of larynx at supraglottic level. (c) Coronal contrast-enhanced CT neck shows a 2.4 x 2 x 4.1-cm slightly high-density lesion consistent with hematoma (arrow) close to the left side of larynx at about C4 to C5 levels involving the left supraglottic, glottic, and subglottic tissues.

Diagnosis

Acute Traumatic Injury of the Larynx. The patient was managed conservatively. He was admitted to the ICU and intubated to protect his airway for 7 days. Fiberoptic laryngoscopy revealed hematoma on left aryepiglottic fold with decreased mobility and swelling of left true vocal cord. The patient's hospital stay was uncomplicated. He was discharged home on day eight receiving 5-day dose of prednisolone.

External laryngeal trauma is uncommon but potentially deadly injury [1]. The most common causes are motor vehicle collisions and sporting accidents [1]. The standard for diagnosis is CT but ultrasonography can lead to diagnosis [2,3]. Endoscopic findings can be obtained by direct or indirect laryngoscopy, nasopharyngoscopy, bronchoscopy and esophagoscopy [4]. The initial management is the establishment of a secure airway with a choice of intubation, tracheotomy or cricothyroidotomy [5]. The conservative approach is suitable when the laryngeal framework is stable but surgical intervention is the treatment of choice in patients with massive edema or multiple fractures [6,7].

References

1. DePorre AR, Schechtman SA, Hogikyan ND, Thompson A, Westman AJ, et al. Airway Management and Clinical Outcomes in External Laryngeal Trauma: A Case Series. *Anesth Analg.* 2019; 129: 52-54.
2. Becker M, Leuchter I, Platon A, Becker CD, Dulguerov P, et al. Imaging of laryngeal trauma. *Eur J Radiol.* 2014; 83: 142-154.
3. Jakubowska A, Zawadzka-Głós L, Brzewski M. Usefulness of ultrasound examination in larynx traumas in children. *Pol J Radiol.* 2011; 76: 7-12.
4. Bell RB, Verschuereen DS, Dierks EJ. Management of laryngeal trauma. *Oral Maxillofac Surg Clin North Am.* 2008; 20: 415-430.
5. Schaefer SD. Management of acute blunt and penetrating external laryngeal trauma. *Laryngoscope.* 2014; 124: 233-244.
6. Juutilainen M, Vintturi J, Robinson S, Leif Bäck, Hannu Lehtonen, et al. Laryngeal fractures: Clinical findings and considerations on suboptimal outcome. *Acta Otolaryngol.* 2008; 128: 213-218.
7. Butler AP, Wood BP, O'Rourke AK, Porubsky ES. Acute external laryngeal trauma: Experience with 112 patients. *Ann Otol Rhinol Laryngol.* 2005; 114: 361-368.