



Língua Villosa Nigra - A Rare Case of Dark Tongue

Luisa Castello Branco Ribeiro*

Hospital Prof. Doutor Fernando Fonseca, Unidade Local de Saúde de Amadora/Sintra, Portugal.

***Corresponding Author(s): Luisa Castello Branco Ribeiro**

Hospital Prof. Doutor Fernando Fonseca, Unidade

Local de Saúde de Amadora/Sintra, Portugal.

Tel: 00351913398882; Email: luisa.cbfr@gmail.com

Received: June 01, 2024

Accepted: June 17, 2024

Published Online: June 24, 2024

Journal: Journal of Clinical Images

Publisher: MedDocs Publishers LLC

Online edition: <http://meddocsonline.org/>

Copyright: © Branco Ribeiro LC (2024). *This Article is distributed under the terms of Creative Commons Attribution 4.0 International License*

Clinical Image Description

A 3-month old female infant was brought to the Emergency Department due to nasal obstruction. The infant did not exhibit any other symptoms. She was exclusively breastfed and received a daily dose of 667 IU of cholecalciferol. No other foods, supplements, or medications were introduced, according to the mother. During the physical examination, the infant displayed excellent vitality and showed no abnormalities except for nasal obstruction, which improved after nasal irrigation with saline solution and a brownish stain with poorly defined borders on the tongue (Figure 1), which could not be removed with a spatula. The mother reported that the infant had the tongue lesion for approximately two weeks, which concerned her.

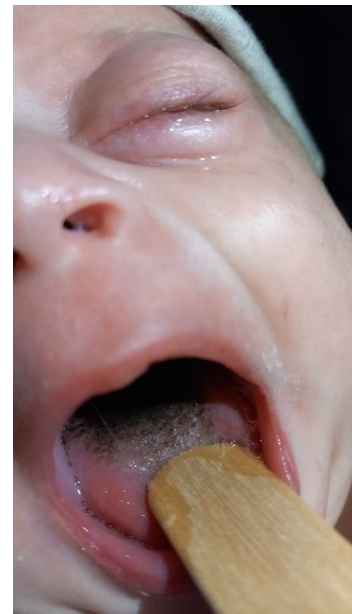


Figure 1: Infant with a dark tongue.



The black hairy tongue is a benign, painless, self-limiting, and usually asymptomatic condition, that is more common in men over 30 years of age and rare pediatric patients [1,2]. This condition is characterized by the alteration of the conformation of the tongue's dorsal filiform papillae [1], which take on a hair-like appearance due to consequent hyper keratinization [3]. Risk factors for a black hairy tongue include poor oral hygiene, oral antibiotic treatment, radiotherapy, oral infection by *Candida albicans*, and the use of drugs that induce xerostomia [1]. Other described risk factors include smoking and the consumption of coffee, black tea, or alcohol [2]. The diagnosis is established clinically, and other diagnostic complementary exams (such as biopsy and anatomopathological evaluation) are unnecessary [4].

The mother of the child was reassured in the Emergency Department and advised to gently brush the infant's tongue with an age-appropriate brush twice a day. Three weeks later the lesion had disappeared with the measures taken.

References

1. Owczarek-Drabińska JE, Radwan-Oczko M. A Case of Lingua Villosa Nigra (Black Hairy Tongue) in a 3-Month-Old Infant. *Am J Case Rep.* 2020; 21: e926362. doi: 10.12659/AJCR.926362.
2. Özen F, Etçioğlu E, Aydın A, Özer MT. Lingua Villosa Nigra Developing After Amoxicillin-Clavulanic Acid Use in a Pediatric Patient: A Case Report. *Journal of Child.* 2021; 21(2): 218-220. <https://doi.org/10.26650/jchild.2021.832942>.
3. González Gómez JM, Peláez Cantero MJ, De la Mota Ybancos JL, Vera Casaño A, et al. Lengua vellosa negra en lactante. *An Pediatr.* 2012; 77: 209-10.
4. Figueiredo LA, Pera S, Bacalhau D, Garcia R. Lingua villosa nigra (black hairy tongue) in a 2 week-old newborn. *Pediatric Oncall Journal.* Volume. 2023; 20(4): 161. DOI:<https://doi.org/10.7199/ped.oncall.2023.44>.