



# Isolated Penile Calciphylaxis Secondary to Uncontrolled Diabetes

**Mohamed Shafi bin Mahboob Ali\***

Ministry of Higher Education (MOHE) Malaysia.

**\*Corresponding Author(s): Mohamed Shafi bin Mahboob Ali**

Ministry of Higher Education (MOHE) Malaysia.

Email: mshafix\_7@yahoo.co.uk

Received: Feb 27, 2024

Accepted: Mar 13, 2024

Published Online: Mar 20, 2024

Journal: Journal of Clinical Images

Publisher: MedDocs Publishers LLC

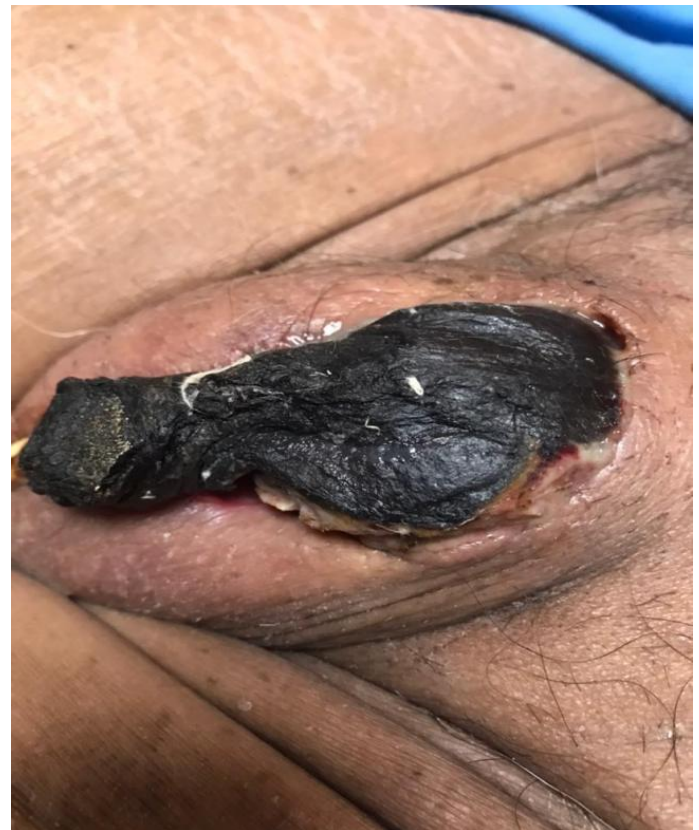Online edition: <http://meddocsonline.org/>

Copyright: © Mahboob Ali MSB (2024). *This Article is distributed under the terms of Creative Commons Attribution 4.0 International License*

**Keywords:** Penile calciphylaxis; Gangrene; Auto-amputation; Diabetes.

## Clinical Image Description

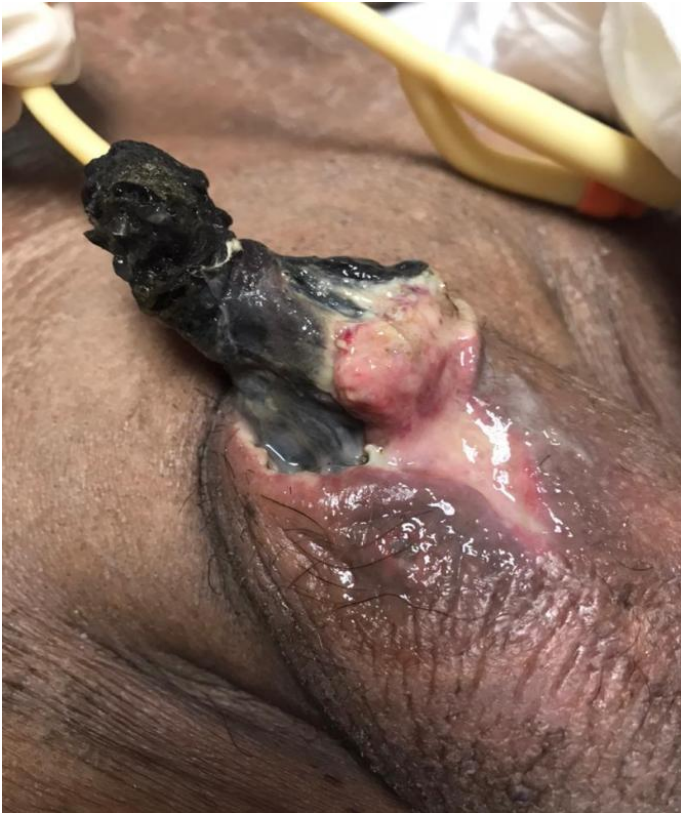Penile calciphylaxis is an extremely rare disease. It affects the penis by the build-up of intimal fibrosis and medial calcifications of the small arteries and causing gangrene of the tissue. It is frequently seen in patients with uncontrolled diabetes and end stage renal failure. Penile calciphylaxis has a poor prognosis and carries a high mortality rate about 64%. Unlike Fournier's gangrene, wound debridement is controversial in penile calciphylaxis. We would like to report a case of a 66-year-old man with a long history of uncontrolled type-2 diabetes whom presented with penile calciphylaxis at our center. He ends up with a penile auto-amputation despite received intravenous antibiotics and wound debridement. Early intervention such as aggressive wound debridement may prevent the patient from succumb into septicemia and death.



**Figure 1:** Gangrenous dorsal penis.



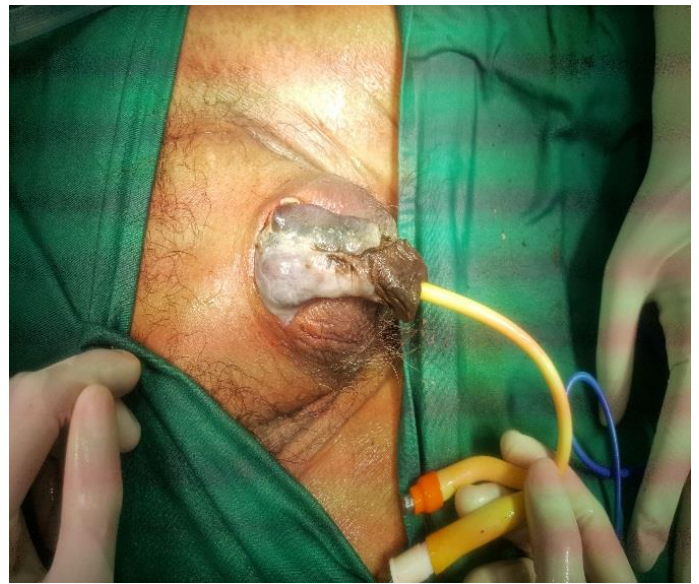**Cite this article:** Mahboob Ali MSB. Isolated Penile Calciphylaxis Secondary to Uncontrolled Diabetes. J Clin Images. 2024; 7(1): 1154.



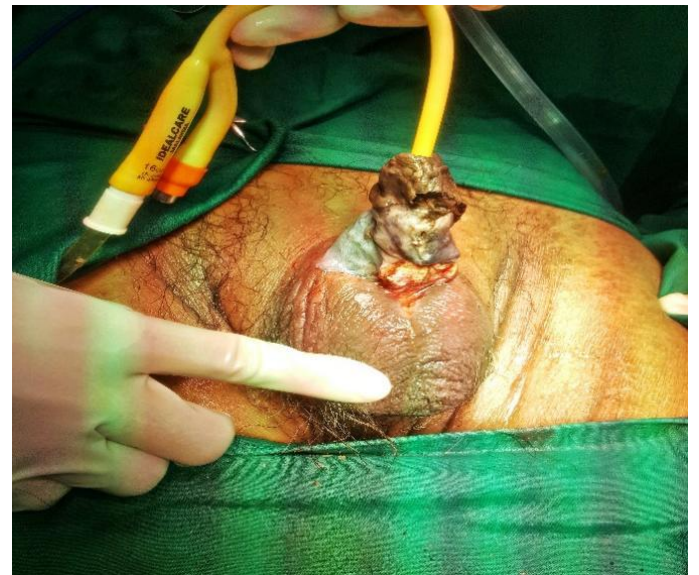
**Figure 2:** Gangrenous ventral penis.

#### References

1. Sandhu G, Gini MB, Ranade A, Djebali D, Smith S. Penile calciphylaxis: A life-threatening condition successfully treated with sodium thiosulfate. *Am J Ther.* 2012; 19(1): e66-8. doi: 10.1097/MJT.0b013e3181e3b0f2.
2. D'Assumpcao C, Sharma R, Bugas A, Heidari A, McPheeters RA, et al. A Fatal Case of Penile Calciphylaxis. *J Investig Med High Impact Case Rep.* 2022; 10: 23247096221076275. doi: 10.1177/23247096221076275.
3. Karpman E, Das S, Kurzrock EA. Penile calciphylaxis: Analysis of risk factors and mortality. *J Urol.* 2003; 169(6): 2206-9. doi: 10.1097/01.ju.0000064334.85656.a1.



**Figure 3:** Ventral penis after wound debridement.



**Figure 4:** Dorsal penis after wound debridement.