



Intrapulmonary Aneurysmal Sacs: A priori a Complex Arteriovenous Malformation

Herveat Ramanandafy^{1*}; Haritanjona Andriamiarintsoa²; Michel Harison Tiaray³; Emmylou Prisca Gabrielle Andrianah²; Ahmad Ahmad²; Hanta Marie Danielle Vololontiana¹; Joëlson Lovaniaina Rakotoson³

¹Department of Internal Medicine, University Hospital of Joseph Raseta Befelatanana, Antananarivo, Madagascar.

²Department of Medical imaging and radiodiagnosis, University Hospital of Joseph Ravoahangy Andrianaivalona, Antananarivo, Madagascar.

³Department of Pneumology, University Hospital of Joseph Raseta Befelatanana, Antananarivo, Madagascar.

***Corresponding Author(s): Ramanandafy Herveat**

Internal medicine specialist, University Hospital of Joseph Raseta Befelatanana, Antananarivo, Madagascar.

Tel: +261342154617;

Email: heriveat@gmail.com

Received: Apr 27, 2022

Accepted: May 18, 2022

Published Online: May 20, 2022

Journal: Journal of Clinical Images

Publisher: MedDocs Publishers LLC

Online edition: <http://meddocsonline.org/>

Copyright: © Herveat R (2022). *This Article is distributed under the terms of Creative Commons Attribution 4.0 International License*

Keywords: Angio-CT scan; Arteriovenous malformation; Aneurysmal; Clinical imaging.

Clinical image description

This case report is a rare situation seen on diagnostic imaging. It is about the anatomical description of a preterm sacciform dilatation (black arrow) fed by a feeder artery (green arrow), and drained by a draining vein (blue arrow) in a 36-year-old woman, who was diagnosed as an arteriovenous malformation on angio-CT scan (Figure 1). In a sagittal section (Figure 2), the aneu-

rysmal sacs are supplied by dilated arteries, drained by draining veins, creating right-left shunts. In axial comparison (Figure 3), the crosssection shows saccular dilations at the level of the pulmonary fields forming a completely disorganized network. This report highlights the importance of tight cooperation between radiologist and clinician in the accurate disease diagnosis.



Cite this article: Ramanandafy H, Andriamiarintsoa H, Tiaray MH, Andrianah EPG, Ahmad A, et al. Intrapulmonary Aneurysmal Sacs: A priori a Complex Arteriovenous Malformation. J Clin Images. 2022; 5(1): 1128.

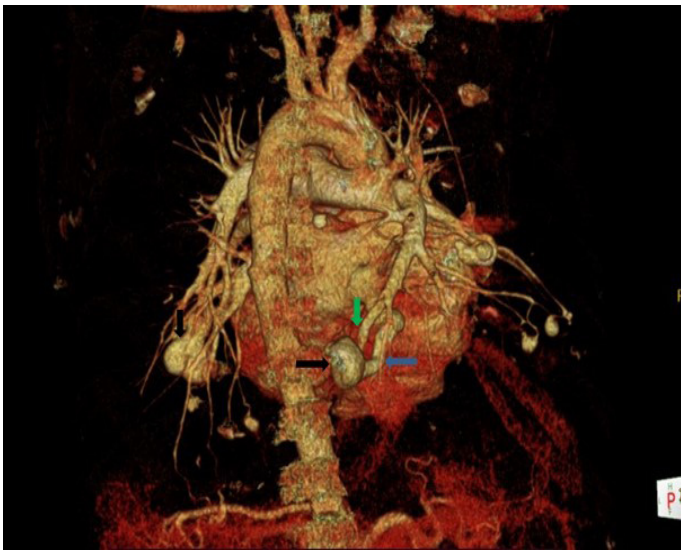

Figure 1: Anatomoscanographic section of pulmonary arteriovenous malformations.

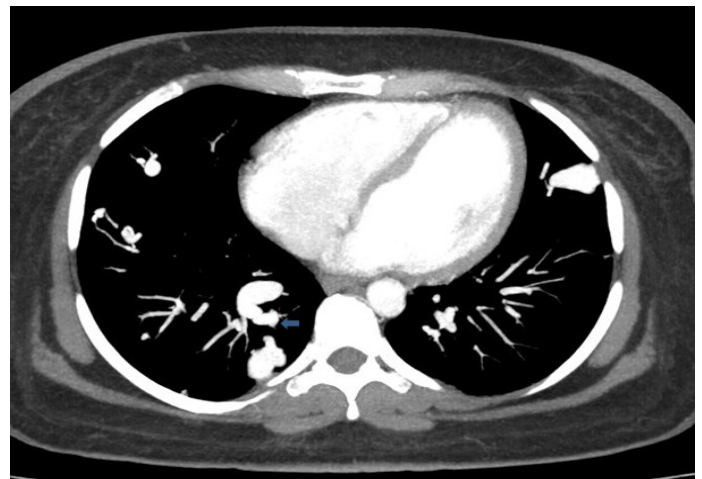

Figure 3: Axial CT scan with contrast medium showing multiple aneurysmal sacs in both lung fields.

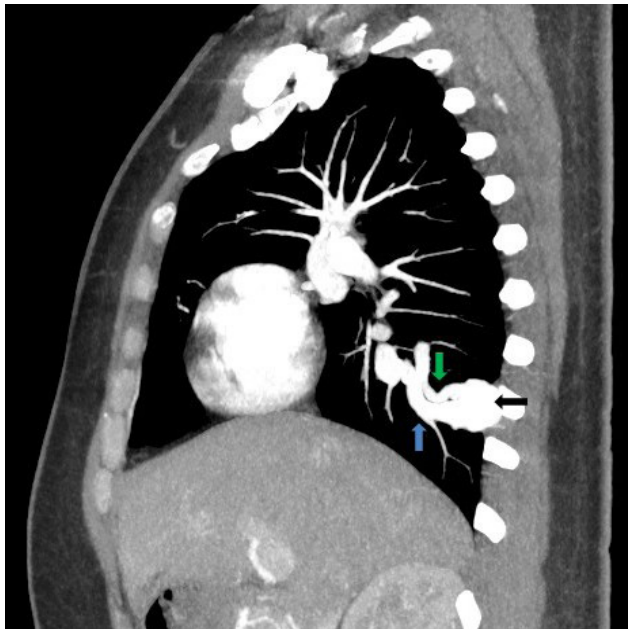


Figure 2: Sagittal CT scan with contrast medium showing an aneurysmal sac fed by an artery and drained by a dilated drainage vein.

Key clinical message

The report of this case would allow researchers to compare with the literature and could provide additional data on the diagnosis of pulmonary arteriovenous malformation.

Acknowledgements

This work was carried out with the working group of SIMAD (Madagascar Imaging Society). The authors thank the patient who gave written permission for this report.

Author's contributions

All the authors have read and approved the final draft of the manuscript. All authors contributed to this work and approved the final version.

Conflicts of interest

None declared

Ethical approval

The article does not contain any personal information that could identify the patient. The names and dates on the chest CT scan have been hidden. The authors have included only information necessary for scientific understanding.

Finding statement

This research has not received any specific grant from any public, commercial or for-profit.