



Encysted pleural effusion: A radiographic mimicker of neoplasm!

Avirup Majumdar*; Virendra Atam; Shubhanshu Shivhare; Mayank Mishra; Mudit Kotwal

Department of Medicine, King George's Medical University, Lucknow, UP, India

***Corresponding Author(s): Avirup Majumdar**

Department of Medicine, King George's Medical University, Lucknow, UP, India

Tel: 91-7318-329-401;

Email: dr.a.majumdar99@gmail.com

Received: Feb 28, 2020

Accepted: Mar 23, 2020

Published Online: Mar 24, 2020

Journal: Journal of Clinical Images

Publisher: MedDocs Publishers LLC

Online edition: <http://meddocsonline.org/>

Copyright: © Majumdar A (2020). *This Article is distributed under the terms of Creative Commons Attribution 4.0 International License*

Keywords: Pleural effusion; Encysted pleural effusion; Lung neoplasm; Lung cyst; Radiological mimicker

Clinical image description

A 37 year old Indian male, non smoker, teacher by occupation presented to the out-patient department with a 15 day history of pleuritic chest pain, fever and dry cough. He had no significant past medical illness, tuberculosis contact or a history of weight loss. Clinically, patient was febrile (oral temperature -100.6 °F), hemodynamically stable with no apparent breathlessness (oxygen saturation- 98% on room air) and lymphadenopathy. Chest examination revealed a dull percussion note and decreased vesicular breath sounds on the right side with no tracheal shifting. A chest radiograph was ordered which showed a well circumscribed homogenous opacity in right upper lung

field and a wedge shaped right middle lung field opacity (Figure 1). Suspecting a neoplasm, we ordered Contrast enhanced chest CT which revealed two discrete hypodense, fluid filled encysted collections in right pleural cavity with no parenchymal change (Figure 2 & 3). Pleural fluid analysis showed a neutrophilic exudative fluid with a sterile culture report (probably due to prior administration of antibiotics). Patient was managed with intravenous antibiotics and tube thoracostomy to which he responded and was discharged afebrile. Encysted pleural effusion can sometimes mimic neoplasm on chest radiograph, definitive diagnosis with CT is required for timely management.



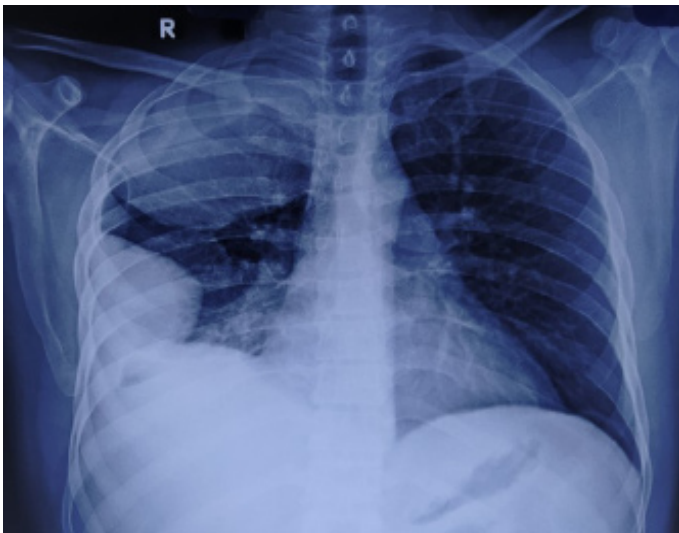


Figure 1: Chest radiograph (postero-anterior view) showing well circumscribed homogenous opacity in right upper lung field and a wedge shaped opacity in right middle lung field.

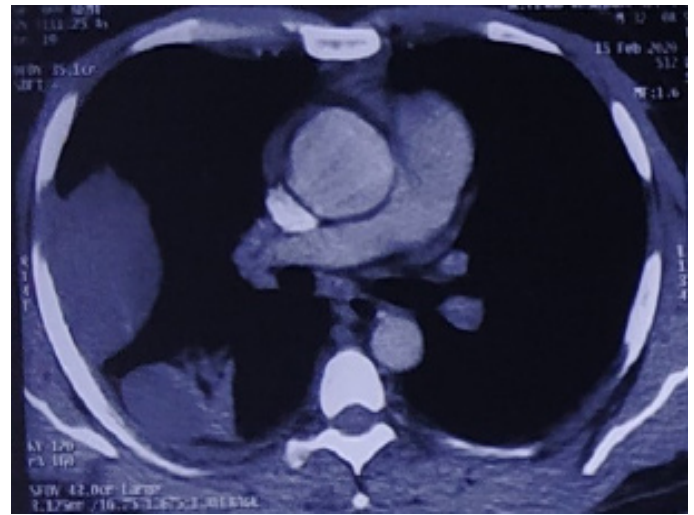


Figure 3: Axial contrast enhanced CT of chest showing two pleural based loculated lesions in right lung field with no underlying parenchymal pathology.

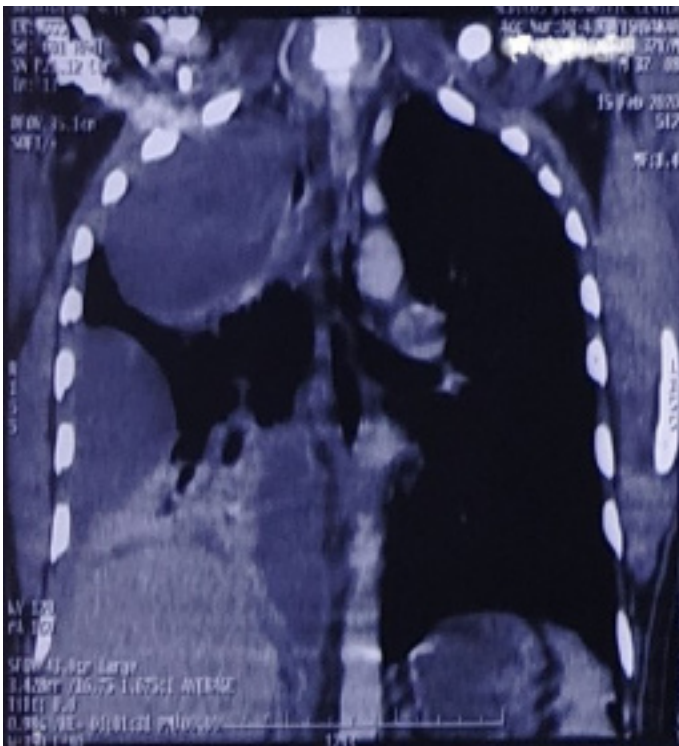


Figure 2: Coronal contrast enhanced CT of chest revealing two encysted fluid-filled lesions in right lung field.