



Double ureter

Dr. Siddharth P. Dubhashi^{1*}; Dr. Riddhima S. Dubhashi²

¹Professor and Head, Department of Surgery, All India Institute of Medical Sciences (AIIMS), Nagpur, India.

²Postgraduate student in Surgery, Dr. V.M. Govt. Medical College, Solapur, India.

***Corresponding Author(s): Siddharth P. Dubhashi**

Professor and Head, Department of Surgery, All India Institute of Medical Sciences (AIIMS), Nagpur, Pune-411008.

Tel: +91-988-162-4422,

Email: spdubhashi@gmail.com

Received: Apr 03, 2020

Accepted: May 04, 2020

Published Online: May 06, 2020

Journal: Journal of Clinical Images

Publisher: MedDocs Publishers LLC

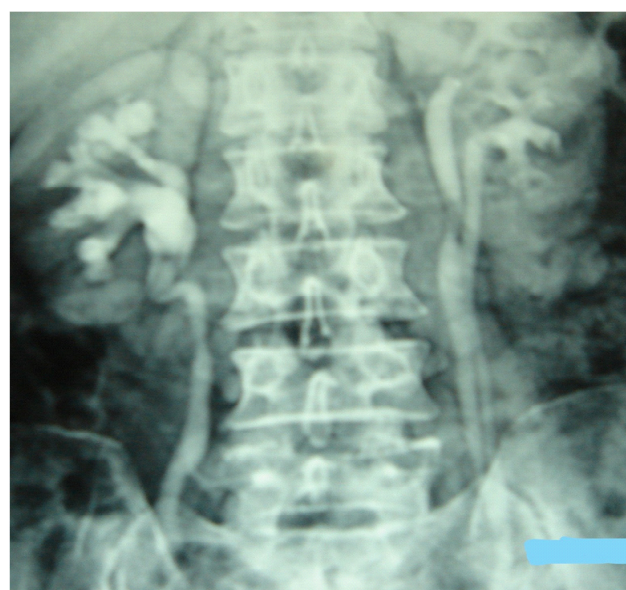
Online edition: <http://meddocsonline.org/>

Copyright: © Dubhashi SP (2020). *This Article is distributed under the terms of Creative Commons Attribution 4.0 International License*

Keywords: Double ureter; Ureteric bud

Clinical image description

Double ureter is the result of early splitting of the ureteric bud into two parts before penetrating the metanephric blastema causing partial or sub-total duplication of ureter [1]. It can be complete or incomplete duplication. A prevalence of 0.1% to 4% has been reported in literature [2]. The anomaly has a potential for complications like ureterocoele formation, obstruction, vesico-ureteral reflux and urolithiasis [3]. This is a case of a 38 year old male who presented with history of recurrent urinary tract infections. Intravenous Urography revealed a double pelvi-calyceal system in left kidney with partial duplication of left ureter, the two joining just above the vesico-ureteric junction.



References

1. Sadler TW. Langman's Medical Embryology. 9th Ed., Baltimore, Maryland, USA, Lippincott Williams & Wilkins, 2004; 329.
2. Smith EC, Orkin L A. A clinical and statistical study of 471 congenital anomalies of the kidney and ureter. J Urol. 1945; 53: 11-26.
3. Privett JT, Jeans WD, Roylance J. The incidence and importance of renal duplication. Clin Radiol. 1976; 27: 521–530.