



Disappearing lesion of spinal cord

Bindu Menon^{1*}; Gayatri Manam²

¹Department of Neurology, Apollo speciality hospitals, Nellore, India

²Department of Radiology, Apollo speciality hospitals, Nellore, India

***Corresponding Author(s): Bindu Menon**

Department of Neurology, Apollo Speciality hospitals,
 16/111/1133, Muttukur Road, Pinakini Nagar, Nellore,
 Andhra Pradesh.

Tel: 09866223905; Email: bneuro_5@rediffmail.com

Received: Feb 15, 2019

Accepted: Apr 22, 2019

Published Online: Apr 26, 2019

Journal: Journal of Clinical Images

Publisher: MedDocs Publishers LLC

Online edition: <http://meddocsonline.org/>

Copyright: © Menon B (2019). *This Article is distributed under the terms of Creative Commons Attribution 4.0 International License*

Key words: B12 deficiency; Vanishing lesion; Spinal cord

Description

A 75-year-old man presented with acroparesthesia and unsteady gait since 2 weeks.

His symptoms were insidious and gradually progressive in nature. Higher mental function and cranial nerves were normal. Motor system examination showed brisk reflexes, plantar flexor, absent proprioception in hands and feet and Rombergs test positive. Patient had no history of toxin exposure and took mixed diet. Hemoglobin was 9g/dl, MCV: 110fl, vitamin B12 level 82 pg/ml. HIV was negative, intrinsic factor and anti-parietal cell antibodies were positive suggestive of pernicious anemia. MRI cervical spine sagittal and axial showed bilateral symmetrical hyperintensity involving the dorsal column with inverted V sign suggestive of Sub-Acute Combined Degeneration of cord (SACD) (Figure 1 & 3). Patient was treated with cobalamin 1000

mcg IM daily for 5 days followed by 1000 mcg/wk for 4 weeks and advised for monthly injections. His neurological symptoms and MRI after 2 months (Figure 2 & 4) completely reversed.

SACD, a reversible neurological complication of vitamin B12 deficiency is characterized by acroparasthesia, gait disturbance and myeloneuro encephalopathy due to degeneration of the posterior and lateral columns of the spinal cord. The differential diagnosis of an MRI with spinal posterior cord lesion is vast and can include HIV vacuolar myelopathy, multiple sclerosis, infectious myelitis, spinal infarction, and malignancies which were ruled out by appropriate investigation. Classical inverted V sign on axial MRI is diagnostic [1]. A high index of suspicion is necessary for early diagnosis and treatment.



Cite this article: Menon B, Manam G. Disappearing lesion of spinal cord. J Clin Images. 2019; 1(1): 1004.

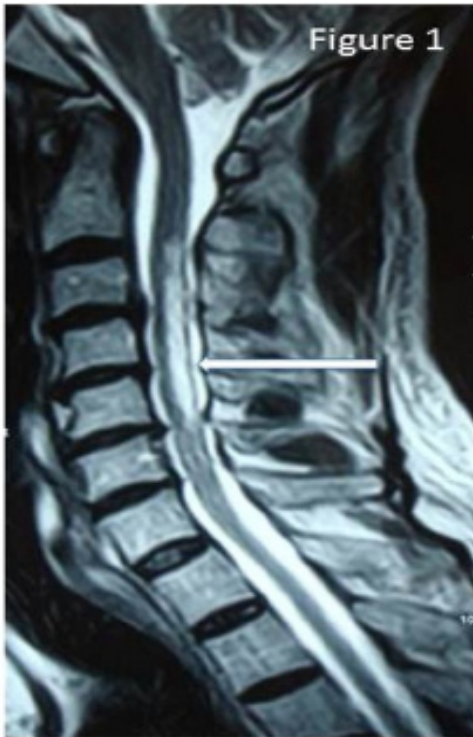


Figure 1: MRI cervical spine sagittal T2 showing hyper intensity involving posterior column at C3 - C5 levels

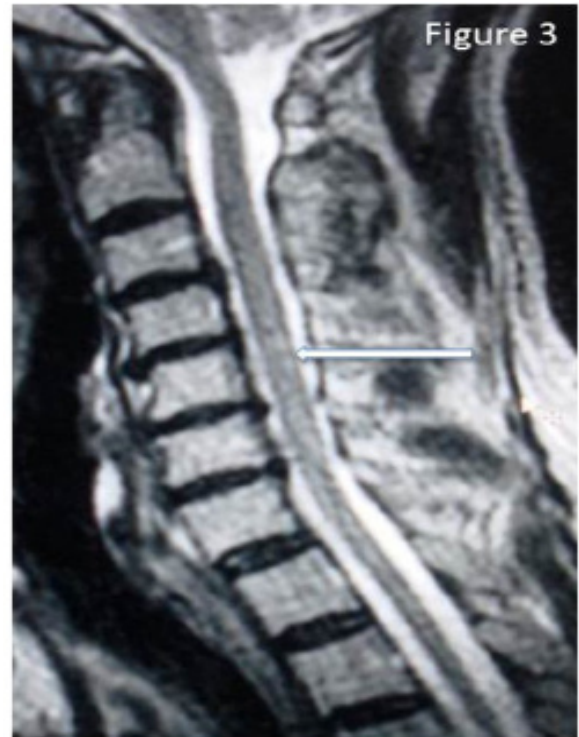

Figure 3: MRI cervical spine sagittal T2 showing hyper intensity involving posterior column at C3 - C5 levels

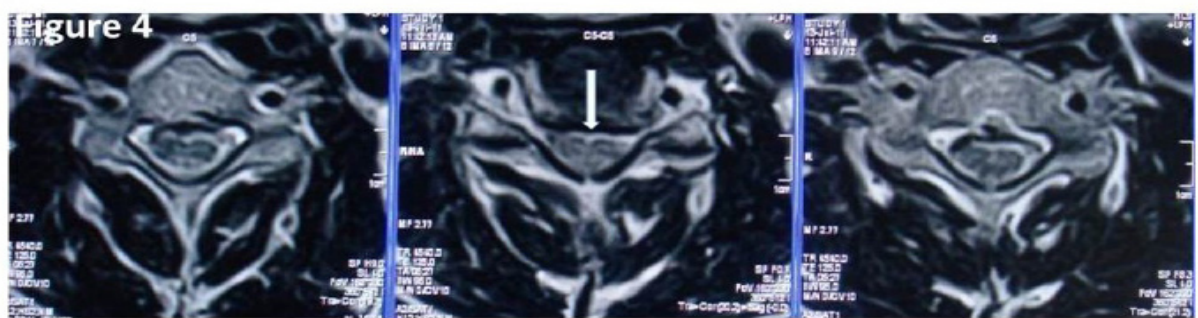
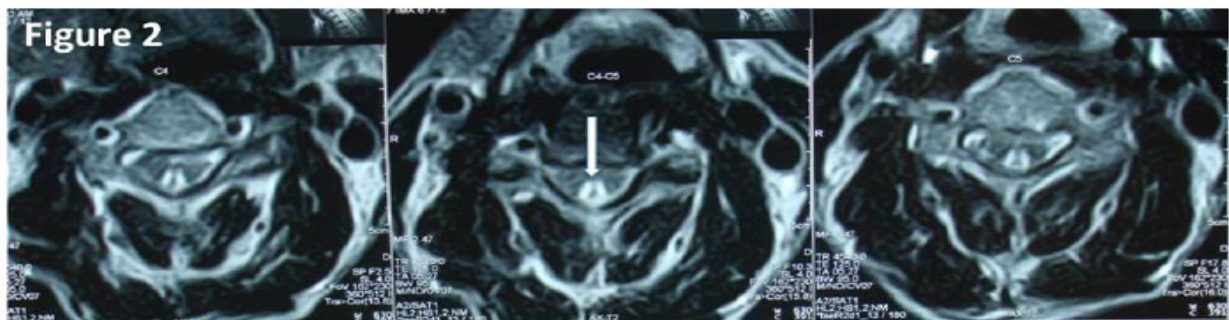


Figure 2/4: MRI cervical spine sagittal T2 showing hyper intensity involving posterior column at C3 - C5 levels

References

1. Hemmer B, Glocker FX, Schumacher M, Deuschl G, Lucking CH. Subacute combined degeneration: Clinical, electrophysiological, and magnetic resonance imaging findings. *J. Neurol. Neurosurg. Psychiatry.* 1998; 65: 822–827.