



Computer-assisted osteotomy of femoral deformity caused by osteogenesis imperfect

Xiong Ying; Wu Tong*; Gan XueWen; Ariful Haque; Ren YunFeng

¹Department of Orthopaedics, Yan'an Hospital Affiliated to Kunming Medical University, Kunming, Yunnan, China.

***Corresponding Author(s): Wu Tong**

Department of Orthopaedics, Yan'an Hospital Affiliated to Kunming Medical University, Kunming, Yunnan, China.

Tel: +86 1858 935 9032

Email: 627171503@qq.com

Received: Apr 10, 2020

Accepted: May 12, 2020

Published Online: May 14, 2020

Journal: Journal of Clinical Images

Publisher: MedDocs Publishers LLC

Online edition: <http://meddocsonline.org/>

Copyright: © Tong W (2020). *This Article is distributed under the terms of Creative Commons Attribution 4.0 International License*

Clinical image description

Li Tingxin, 26, is a Chinese female. In 11 years she got admitted in the hospital for several times because of "repeated left femoral fracture with deformity and limited activity". The patient was diagnosed as osteogenesis imperfecta and multiple skeletal malformations. In 2004, her right femur fractured caused by falling injury, which was treated by open reduction and internal fixation with steel plate. In 2014, the right femur again fractured due to falling injury. External fixation frame and Kirschner wire fixation were performed again. After One year, the external fixation frame was taken out and Kirschner wire has been retained. In 2000, she had left hip pain without any deformity, which improved after rest. In 2008 she again felt the pain, but no obvious cause detected. After X-ray examination in hospital, she was diagnosed as left femur fracture. After trac-

tion treatment, the fracture healed, and then left femur deformity gradually appeared, making it difficult to stand.

We printed her left femur in 3D, simulated osteotomy with computer, and made osteotomy guide plate. During the operation, we cut the bone according to the position of the guide plate, and then used Ortho-Bridge System (OBS) invented by ourselves to fix the fracture [1], so as to ensure the almost correct shape of the femur. After the operation, the effect was good, and the patient could stand on his own.

References

1. Wang, DX, Xiong Y, Deng H, Jia F, Gu S et al. Biomechanical analysis and clinical effects of bridge combined fixation system for femoral fractures.[J]. Proc Inst Mech Eng H. 2014; 228: 899-907.



Cite this article: Ying X, Tong W, XueWen G, Haque A, YunFeng R. Computer-assisted osteotomy of femoral deformity caused by osteogenesis imperfect. J Clin Images. 2020; 3(1): 1041.

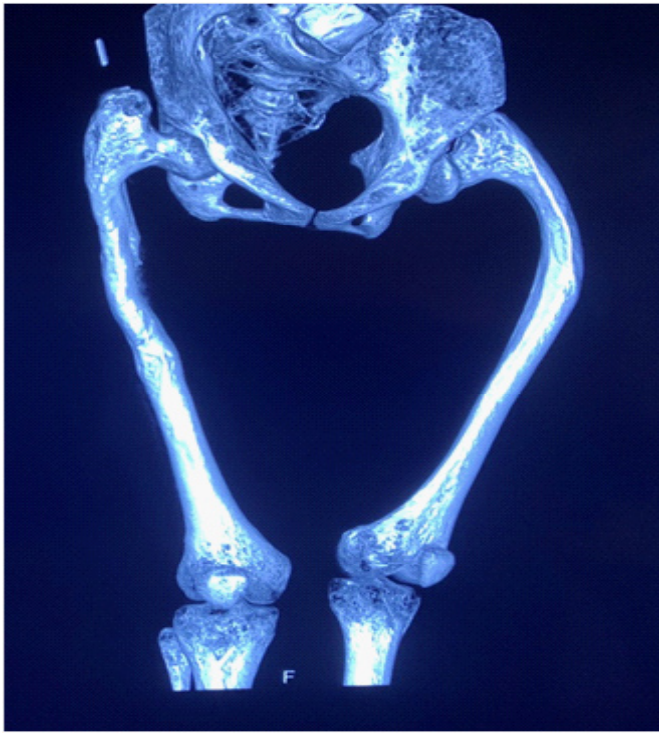

Figure 1: Bilateral femur deformity on CT, especially in the left side.

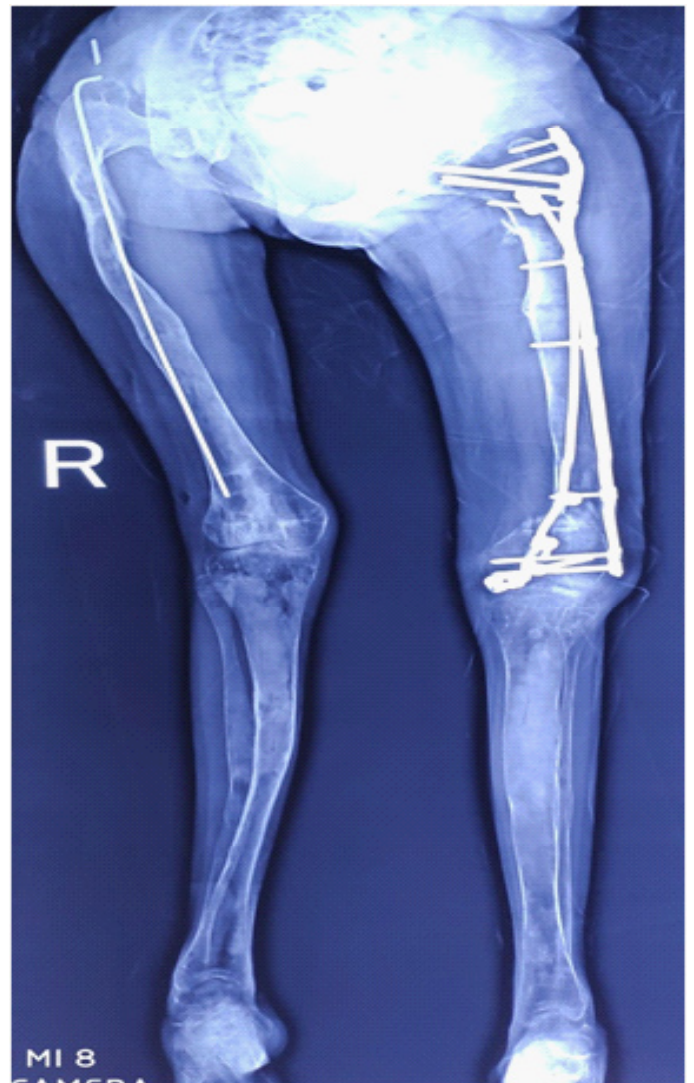


Figure 3: Full length films of both legs after operation




Figure 2: 3D printing simulation operation of femur