



# Cobalamin Deficiency Mimicking Motor Neuron Disease: An Unusual Brain MRI lesion Pattern

Oliveira ADP<sup>1\*</sup>; Oliveira ARVP<sup>2</sup>; Angelo RCO<sup>1,2</sup>

<sup>1</sup>Department of Medicine, University of Pernambuco (UPE), Serra Talhada, PE, Brazil

<sup>2</sup>Postgraduate Program in Health and Socio-environmental Development, University of Pernambuco (UPE), Garanhuns, PE, Brazil

**\*Corresponding Author(s): Oliveira ADP**

Department of Medicine, University of Pernambuco (UPE), Av. Gregório Ferraz Nogueira, S/N (Estação Experimental Lauro Bezerra), Serra Talhada, PE, Brazil, CEP 56 909 – 535  
Tel: +55-81-992492300;  
Email: americo.oliveira@upe.br

Received: May 11, 2020

Accepted: Jun 17, 2020

Published Online: Jun 19, 2020

Journal: Journal of Clinical Images

Publisher: MedDocs Publishers LLC

Online edition: <http://meddocsonline.org/>

Copyright: © De Oliveira ADP (2020). This Article is distributed under the terms of Creative Commons Attribution 4.0 International License

## Clinical Image Description

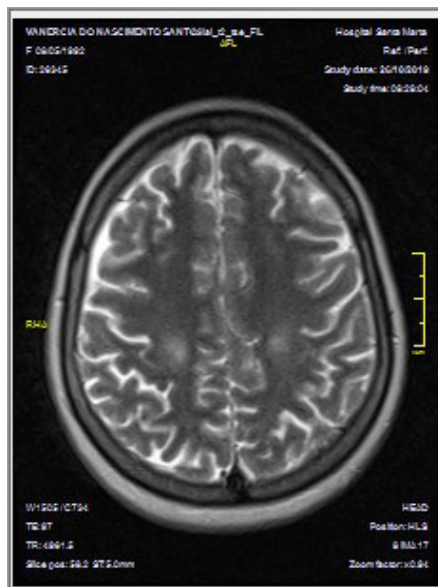
A 27-years-old female was referred to the neurological clinic for evaluation due to difficulty in walking by psychiatric service. Depressive symptoms had started 3 months before the neurological complaint associated with visual hallucinations. The patient's neurological examination showed space and time disorientation, normal muscle tonus and muscle strength in limbs, paresthesia and areflexia in both lower extremities, sensory ataxia, unsteadiness of gait. Blood test revealed serum vitamin B12 of 50pg/ml (210-980pg/ml).

Anti-parietal antibodies were detected, but no antibodies against intrinsic factor. Gastroscopy showed atrophic gastritis. Standard electroneuromyography demonstrated axonal sensory polyneuropathy. Brain Magnetic Resonance Image (MRI) disclosed hyperintense signal in corticospinal tracts, a similar pattern observed in motor neuron disease (Figure 1). The patient was treated with parenteral cyanocobalamin with improvement of neurological and psychotic symptoms.

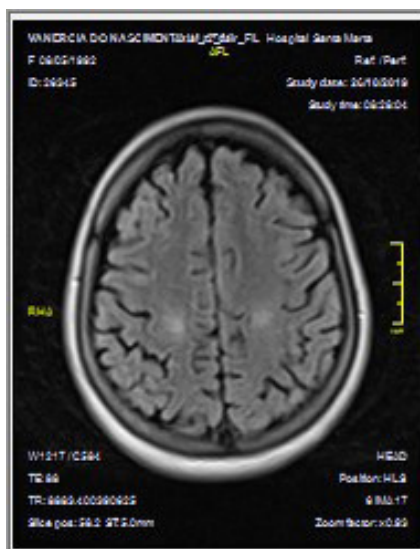


Cobalamin (Vitamin B12) deficiency is associated with various neurological manifestations, including polyneuropathy, myelopathy, cognitive decline, and rarely epilepsy [1]. The manifestations in brain MRI are diverse, periventricular focal or confluent white matter lesions are commonly found patterns [2]. Several leukoencephalopathy and hyperintense subcortical lesions T2W/DWI (diffusion weighted imaging) have also been described [3,4].

The case illustrates an unusual MRI lesion pattern in B12 deficiency with signal hyperintensity of the corticospinal tract on T2/FLAIR. The corticospinal tract hyperintense on T2/FLAIR is a simple and sensitive upper motor neuron degeneration marker in clinically verified in motor neuron disease, in particular amyotrophic lateral sclerosis [5]. This case demonstrates that in addition to the variety of clinical presentations in vitamin B12 deficiency, atypical brain imaging patterns can be found.



(A) Axial T2 weighted



(B) axial FLAIR-weighted

**Figure 1:** (A) Axial T2 weighted and (B) axial FLAIR-weighted brain MRI disclosing frontal hyperintense signal changes in corticospinal tract projections

## References

1. Briani C, Dalla Torre C, Citton V, et al. Cobalamin deficiency: clinical picture and radiological findings. *Nutrients*. 2013; 5 : 4521–39.
2. Chen H, Li H, Li Y, et al. Clinical and imaging characteristics of subacute combined degeneration complicated with white matter lesions in the brain: A report of five cases. *Somatosens Mot Res*. 2018; 35: 119-123.
3. Kremmyda O, Forbrig, R, Heirinch J, et al. Subcortical lesions due to cobalamin deficiency: Na usual MRI lesion pattern. *Nutri Neurosci*. 2019; 27: 1-5.
4. Pacheco FT, Scopetta TL, Sznier M, Paes RA, Rocha AJ. Acute demyelination with leukoencephalopathy and cerebellar involvement in vitamin B12 deficiency. *Arq Neuropsiquiatr*. 2015; 73: 257.
5. Jin J, Hu F, Zhang Q, Jia R, Dang J. Hyper intensity of the corticospinal tract on FLAIR: A simple and sensitive objective upper motor neuron degeneration marker in clinically verified amyotrophic lateral sclerosis. *J Neurol Sci*. 2016; 367: 177-183.