



Cervical Paraganglioma: Iconography of the Surgical Management

Chafai houda*; Alaoui Mahdaoui Sihame; Zaki Zouheir; El Alami Mohammed Nourredine

Department of Otorhinolaryngology (ENT) and Neck Surgery, Hassan II university Hospital, Fez, Morocco

***Corresponding Author(s): Chafai Houda**

Departement of Otorhinolaryngology (ENT) and neck surgery, Hassan II university Hospital, Fez, Morocco

Fax: 05-35-61-90-53, Tel: 06-21-14-01-72;

Email: chafaihouda@gmail.com

Received: Jun 16, 2020

Accepted: Jul 20, 2020

Published Online: Jul 23, 2020

Journal: Journal of Clinical Images

Publisher: MedDocs Publishers LLC

Online edition: <http://meddocsonline.org/>

Copyright: © Houda CH (2020). *This Article is distributed under the terms of Creative Commons Attribution 4.0 International License*

Clinical Image description

Cervical paragangliomas are rare and generally benign tumors. Their incidence is low between 1/30000 and 1/100000. Two clinical forms are individualized: carotid paragangliomas don't have an encounter with carotid dissection and vaginal paragangliomas willingly parapharyngeal and with high basal cranial extension.

Their diagnosis is relatively easy. They have benefited from advances in diagnostic imaging, particularly angiography and magnetic resonance imaging, which allow for scheduled surgery [1,2].

The aim of this work is to report a peroperative iconography of a surgical resection of a cervical paraganglioma.

We report the case of a 55-year-old patient with no notable pathological ATCD who has a lateral cervical mass

Evolving since 9 months progressively increasing in volume without other associated signs all evolving in a context of apyrexia and preservation of the general state. physical examination reveals an isolated, pulsating lateral cervical mass, of firm but elastic consistency, behind the angle of the mandible whose diameter is 6 cm.



On the paraclinical level, a scanner (Figure 1) produced shows a homogeneous tissue mass with clear contours, of medium tissue density with rapid, intense and fleeting contrast uptake upon iodine injection.

An arteriography revealed a vascular blush with a very rapid contrast wash.

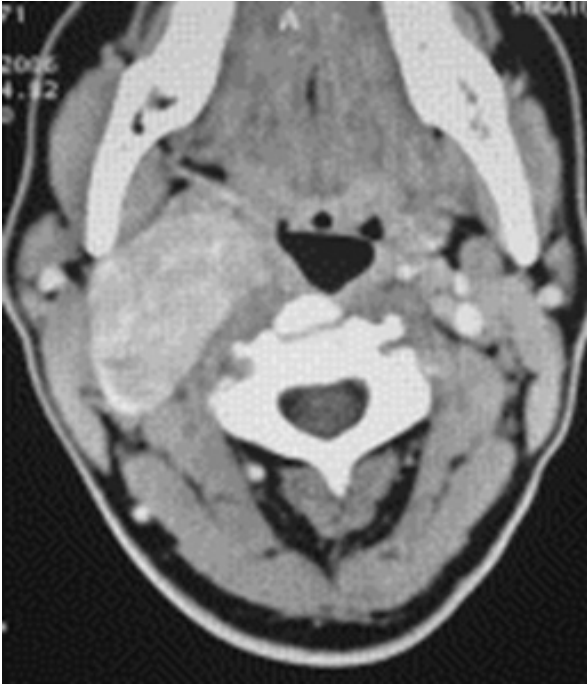

Figure 1: Cervical tomodensitometrie.

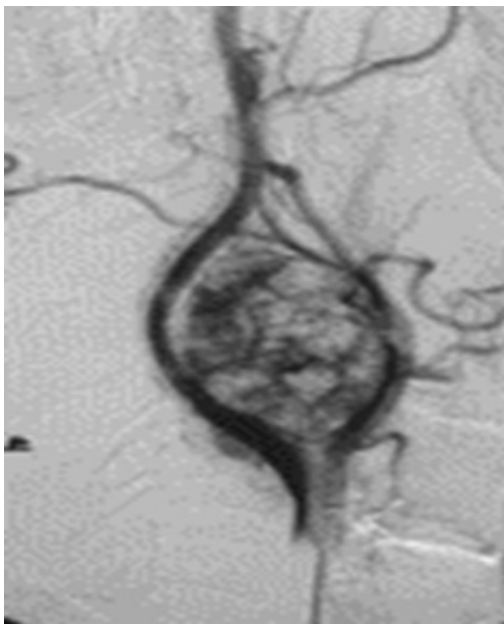


Figure 2: Arteriography.

The urinary endocrine workup does not show any secretion of catecholamine.

We performed a large cervicotomy with resection of the paraganglioma with a very delicate dissection of the jugulo-carotid axis as shown in the Peroperative images.

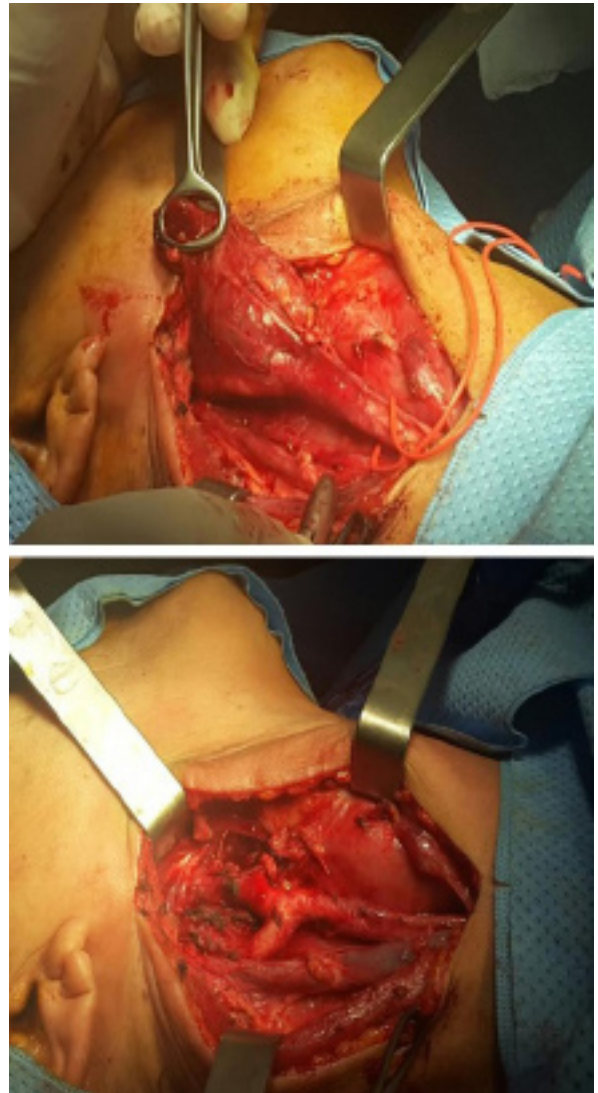

Figure 3: Peroperative images shows close relationship of the paraganglioma with the jugulo-carotid axis.

References

1. Baysal B, Farr Runstein W. Fine mapping of an imprinted gene for familial nonchromaffin paraganglioma, on chromosome 11q23 *Am J Hum Genet* 1997; 60 : 121-132.
2. Patetsio P, Gable D, Garret W, Lamont J, Kuhn J, et al. Management of carotid body paragangliomas and review of 30-year experience *Ann Vasc Surg*. 2002; 16 : 338.