



# Bee Sting Angioedema of Lip

**Abdus Subhan Sohail<sup>1\*</sup>; Pushpalatha k<sup>2</sup>; Udayakumar Rao<sup>2</sup>**

<sup>1</sup>Department of Pediatrics, ESIC Medical College and PGIMSR, Bengaluru, Karnataka, India.

<sup>2</sup>Department of pediatrics, ESIC medical college and PGIMSR, Rajajinagar, Bangalore, Karnataka, India.

**\*Corresponding Author(s): Abdus Subhan Sohail**

Department of Pediatrics, ESIC Medical College and  
PGIMSR, Bengaluru, Karnataka, India.

Email: subhan.sohail04@gmail.com

Received: Feb 14, 2022

Accepted: Mar 02, 2022

Published Online: Mar 04, 2022

Journal: Journal of Clinical Images

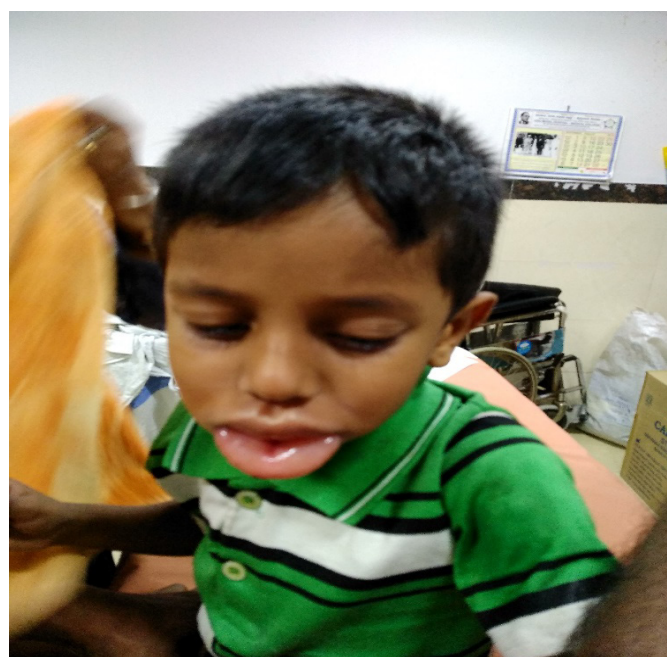
Publisher: MedDocs Publishers LLC

Online edition: <http://meddocsonline.org/>

Copyright: © Sohail AS (2022). *This Article is distributed under the terms of Creative Commons Attribution 4.0 International License*

## Clinical image description

Allergic responses to stinging vary from localized cutaneous reactions to systemic anaphylaxis. Systemic allergic responses to insects are attributed to IgE (immunoglobulin E) antibody-mediated responses, which are caused primarily by stings. Systemic reactions are identical to anaphylaxis from other triggers and may include symptoms of generalised urticaria, laryngeal edema, bronchospasm and hypotension. Diagnosis is generally evident from the history of exposure, typical symptoms and physical findings. Epinephrine is the drug of choice. Adjuvant treatment includes antihistaminics, corticosteroids, intravenous fluids and oxygen.



**Figure 1:** An 8-year-old boy with Angioedema of lower lip due to Bee sting.

