



# An Unexpected Discovery in the Evaluation of a Colitic Pain in a Young Patient

Valerio Massimo Magro<sup>1\*</sup>; Armando Minciotti<sup>2</sup>; Carla Coppola<sup>3</sup>; Walter Verrusio<sup>4</sup>

<sup>1</sup>Echocardiography unit, Department of Internal Medicine & Geriatry, University of Campania "Luigi Vanvitelli", Piazza L. Miraglia 2, 80100, Naples, Italy.

<sup>2</sup>General Practitioner of the Lazio Region, Montefiascone (VT).

<sup>3</sup>Department of Internal Medicine & Geriatry, University of Campania "Luigi Vanvitelli", Piazza L. Miraglia 2, 80100, Naples, Italy.

<sup>4</sup>Department of Cardiovascular, Respiratory, Nephrological, Anesthesiological & Geriatric Sciences, Sapienza University of Rome, Rome, Italy.

**\*Corresponding Author(s): Valerio Massimo Magro**

Department of Internal Medicine and Geriatry,  
 University of Campania "Luigi Vanvitelli", Piazza L.  
 Miraglia 2, 80100, Naples, Italy.  
 Tel: 349 222 4922  
 Email: valerio\_magro@hotmail.com

Received: Apr 25, 2020

Accepted: May 22, 2020

Published Online: May 26, 2020

Journal: Journal of Clinical Images

Publisher: MedDocs Publishers LLC

Online edition: <http://meddocsonline.org/>

Copyright: © Magro VM (2020). *This Article is distributed under the terms of Creative Commons Attribution 4.0 International License*

**Keywords:** Colitic pain; Young patient; Hydronephrosis; Duplicated ureter; Magnetic resonance; Endometriosis

## Clinical image description

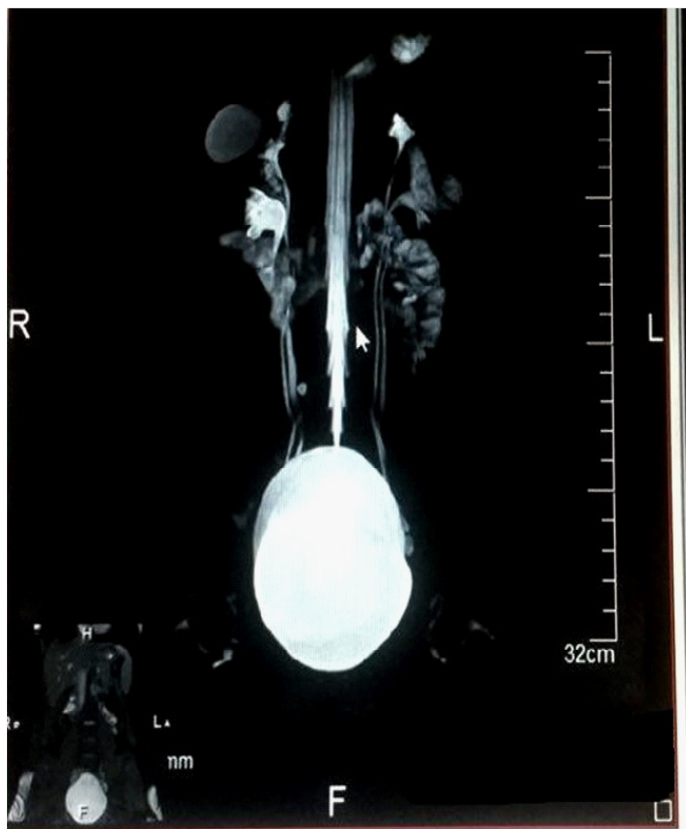
A 16-year-old girl was taken in charge, presenting a symptomatology characterized by history of oligomenorrhea, recurrent episodes of colic-type pain with the presence of hematuria. On clinical examination, the patient was awake and oriented, symptomatic for diffuse abdominal pain, even with irradiation in the back, especially from her localized in hypogastric level,

well breathing and apyretic. Tender abdomen, painful while palpating. Blood test showed WBC 9000/u, Hb 12 mg/dl, creatinine serum level 1.25 mg/dl. We also performed a urine test with sediment, which however was not significant, to exclude the presence of cystitis or laboratory abnormalities, an indirect sign of the presence of stones or renella. In order to evaluate a possible endometriosis, at this point we required a Magnetic



**Cite this article:** Magro VM, Minciotti A, Coppola C, Verrusio W. An Unexpected Discovery in the Evaluation of a Colitic Pain in a Young Patient. J Clin Images. 2020; 3(1): 1047.

resonance imaging (MRI), which showed us (Figure 1) the presence of bilateral double ureter and double outlet in the bladder and associated with a mild hydronephrosis on the right (probably due to kneeling of the ureters). We had opted for performing a resonance more convinced of looking for traces of a possible endometriosis: Some authors validated the use of MRI in the evaluation of millimetric disease systems at the peritoneum level thanks to the use of sequences with suppression of the adipose tissue signal [1]. Duplicated ureter is a congenital condition, in which the ureteric bud, the embryological origin of the ureter, splits resulting in two ureters draining a single kidney, that is often asymptomatic but also it have potential future complications (collecting system obstruction, lithiasis, ureterocele and vesicoureteral reflux) [2-5]. The prevalence of double ureter has a variable range among various authors who have described it in the literature [6] but ureteral duplication is more common in females and when bilateral and complete, all four ureters may open orthotopically on the bladder trigone. This makes early detection of this anomaly helpful to prevent these comorbidities and complications.



**Figure 1:** Magnetic resonance image that highlights the presence of a bilateral double ureter with modest right hydronephrosis.

## References

1. Noventa M, Scioscia M, Schincariol M, Cavallin F, Pontrelli G, et al. Imaging Modalities for Diagnosis of Deep Pelvic Endometriosis: Comparison between Trans-Vaginal Sonography, Rectal Endoscopy Sonography and Magnetic Resonance Imaging. A Head-to-Head Meta-Analysis. *Diagnostics (Basel)*. 2019; 9: E225.
2. Husain M, Hajini F, Bhatt A. Duplicated pyelocaliceal system with partial duplication of ureter. *BMJ Case Rep*. 2013.
3. Ghobashy A, El-Shazly M, Lari A, Allam A, Alenezy N et al. A case of complete renal duplex with h-shaped ureter. *Case Rep Urol*. 2012; 2012: 643207.
4. Karakose A, Aydogdu O, Atesci YZ. Unilateral complete ureteral duplication with distal ureteral stone: A rare entity. *Can Urol Assoc J*. 2013; 7: E511-E512.
5. Naitoh Y, Oishi M, Kobayashi K, Yamada Y, Nakamura T et al. Transvesical laparoscopic surgery for double renal pelvis and ureter with or without ureterocele. *Int J Urol*. 2016; 23: 332-336.
6. Prakash, Rajini T, Venkatiah , Ajay Kumar B, Deepak kumar Sing et al. Double ureter and duplex system: a cadaver and radiological study. *Urol J*. 2011; 8: 145-148.