



An Astounding Case of Pulmonary Sarcomatoid Carcinoma Responding to Pembrolizumab

N Hasan Choudhury^{1*}; Nayab Ahmed¹; Young Min Cho¹; Andrew T Johnson²

¹Northeast Georgia Medical Center, Georgia.

²Longstreet Clinic Cancer Center, Georgia.

*Corresponding Author(s): N Hasan Choudhury

Northeast Georgia Medical Center, 135 Foothills Parkway NE, Gainesville, GA 30501.

Tel: 626-233-2762;

Email: hasan.choudhury5@gmail.com

Received: May 16, 2022

Accepted: Jun 14, 2022

Published Online: Jun 16, 2022

Journal: Journal of Clinical Images

Publisher: MedDocs Publishers LLC

Online edition: <http://meddocsonline.org/>

Copyright: © Choudhury NH (2022). *This Article is distributed under the terms of Creative Commons Attribution 4.0 International License*

Background

Sarcomatoid carcinoma describes a heterogenous group of non-small cell lung carcinomas (NSCLCs) with malignant potential and features that suggest sarcomas. This group can be further classified as pleomorphic, carcinosarcoma, and pulmonary blastoma. Pleiomorphic carcinomas itself include variants such as spindle cell, giant cell, and carcinosarcoma [1]. Sarcomatoid carcinoma represents less than 1% of all lung cancers. The hazard ratio for death from sarcomatoid carcinoma is 1.6 (CI 95% 1.35-2.06) [2]. Given this poor prognosis, we report on a case

Abstract

Sarcomatoid carcinoma describes a heterogenous group of Non-Small Cell Lung Carcinomas (NSCLCs) with malignant potential and features that suggest sarcomas. We report on a case of sarcomatoid (giant cell) carcinoma that went into remission after only two-doses of pembrolizumab. The patient is an asymptomatic 86 year old male with a past medical history significant for adenocarcinoma of the prostate on enzalutamide who was noted to have an incidental mass at the right lung base which was noted during work-up for another incidental renal cell mass that was subsequently evaluated as benign. He initially underwent monitoring of the lung mass over 6 months which showed interval increase from 2.7 x 1.6 cm to 4.3 x 3.2 cm. He was then seen by cardiothoracic surgery for a lung biopsy which revealed poorly differentiated sarcomatoid (giant cell) carcinoma with focal necrosis. A PET scan showed metastasis with hypermetabolic activity and his cancer was staged as IVB (T2, N2, M1c). He was treated with pembrolizumab, and after two doses the patient developed acute conjunctivitis with vision changes of the left eye. Due to concern for neuritis secondary to his cancer therapy, pembrolizumab and enzalutamide were stopped. Two months later a repeat PET/CT showed interval decrease in size of the metastatic lesions and resolution of metabolic activity. At this point he was no longer treated for his lung cancer give no recurrence of lung lesions in the previous 4-month period.

of sarcomatoid (giant cell) carcinoma that went into remission after only two-doses of pembrolizumab.

Case report

The patient is an 86 year old male with a past medical history significant for adenocarcinoma of the prostate on enzalutamide who was noted to have an incidental mass at the right lung base which was noted during work-up for another incidental renal cell mass that was subsequently evaluated as benign. He did not have shortness of breath, chest pain, fevers, chills, or unex-

Cite this article: Choudhury NH, Ahmed N, Cho YM, Johnson AT. An Astounding Case of Pulmonary Sarcomatoid Carcinoma Responding to Pembrolizumab. J Clin Images. 2022; 5(1): 1130.



pected weight loss. The patient was ambulatory and able to do light work (Eastern Cooperative Oncology Group Performance Status of 1).

He initially underwent monitoring of the lung mass over 6 months which showed interval increase from 2.7 X 1.6 cm to 4.3 x 3.2 cm. He was then seen by cardiothoracic surgery for a lung biopsy which revealed poorly differentiated sarcomatoid (giant cell) carcinoma with focal necrosis. A PET scan from the skull base to the mid-thigh revealed a hypermetabolic mass in the left neck base with a maximum SUV of 18.6. There was also a focus in the left breast with an SUV of 13.3. The biopsied lung mass had an SUV of 12. There was also a focus on the left side of the pelvis with an SUV of 10.6. His cancer was staged as IVB (T2, N2, M1c), and he was referred to oncology due to his metastatic disease. Oncology proceeded with molecular testing which showed PD-L1 60% positive immunohistochemistry and a positive KDR mutation (R1032Q). He agreed to proceed with pembrolizumab. After two doses, the patient developed acute conjunctivitis with vision changes of the left eye. Due to concern for neuritis secondary to his cancer therapy, pembrolizumab and enzalutamide were stopped, and he was started on a prednisone taper. His vision did improve but did not return to baseline. Ophthalmology evaluation suggested that patient could have had a 3rd cranial nerve palsy due to a vascular event. Two months later a repeat PET/CT showed resolution of the hypermetabolic mass in the left neck base. The left breast hypermetabolic nodule decreased in size from 1 cm to 5 mm without hypermetabolic activity. The left pelvic mass showed resolution of hypermetabolic activity with a decrease in size from 2.9 cm to 1.4 cm. At this point he was no longer treated for his lung cancer. For his prostate cancer he was started on abiraterone acetate in lieu of enzalutamide. He continued to be monitored at subsequent follow-ups with no recurrence of the lung lesions in the last 4-month period.

Discussion

The above case shows a dramatic response of sarcomatoid to immunotherapy. The Keynote-024 trial demonstrates that pembrolizumab specifically was associated with longer progression-free and overall survival and with fewer adverse events than platinum-based chemotherapy [3]. PDL-1 is a protein on cancer cells that is affected by local cytokines and hence may be used as a predictive biomarker [4]. If 50% of cancer cells have PDL1 proteins then immunotherapy is indicated [3]. Although immunotherapy was appropriate in our patient, he did have an episode of vision change some time after initiating immunotherapy. However, its causality is confounded by enzalutamide or a possible vascular event. Although neuro-ophthalmologic side effects are known with immune checkpoint inhibitors, the incidence is fairly low (0.46%) according to one systematic review [5]. Nonetheless, the near complete remission of the lesions lends consideration toward the effectiveness of immunotherapy. For perspective, the 5-year overall survival rate of metastatic non-small lung cancer is 8% [6]. Since our patient is only a few months out of treatment, we will need to continue to monitor the patient's clinical status.

Conclusion

This case shows the effectiveness of pembrolizumab in treating a rare instance of sarcomatoid lung cancer. More studies are needed to determine the effectiveness of fewer doses of pembrolizumab.

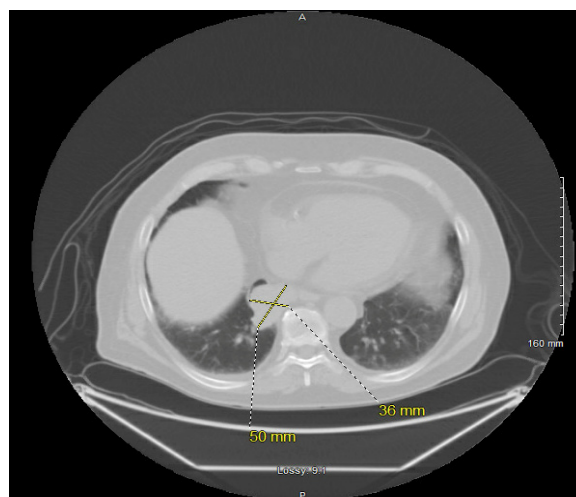


Figure 1: PET CT scan showing pleural-based mass in the right lower lobe at the lung base prior to pembrolizumab treatment.

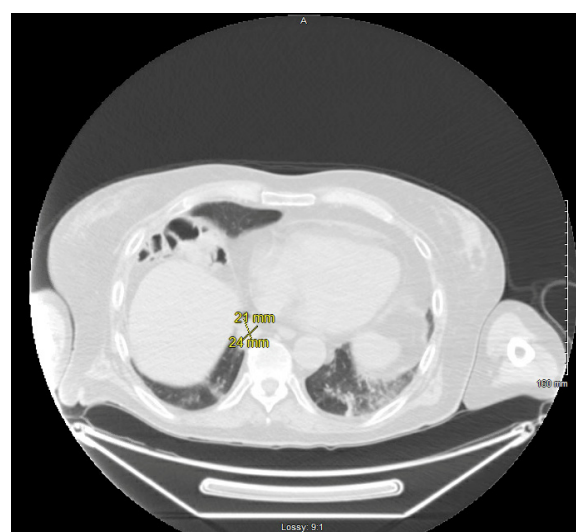

Figure 2: PET CT scan demonstrating significant interval decrease in size and hypermetabolic activity after two doses of pembrolizumab.

References

- Baldovini C, Rossi G, Ciarrocchi A. Approaches to Tumor Classification in Pulmonary Sarcomatoid Carcinoma. *Lung Cancer* (Auckl). 2019; 10: 131-149.
- Yendamuri S, Caty L, Pine M, Adem S, Bogner P, et al. Outcomes of sarcomatoid carcinoma of the lung: a Surveillance, Epidemiology, and End Results Database analysis. *Surgery*. 2012; 152 : 397-402.
- Reck M, Rodríguez-Abreu D, Robinson AG, Hui R, Csósz T, et al. Pembrolizumab versus Chemotherapy for PD-L1-Positive Non-Small-Cell Lung Cancer. *N Engl J Med*. 2016; 375: 1823.
- Patel, Sandip Pravin, and Razelle Kurzrock. "PD-L1 expression as a predictive biomarker in cancer immunotherapy." *Molecular cancer therapeutics*. 2015; 14: 847-856.
- Yu C, Yau M, Mezey N, Joarder I, Micielli J. Neuro-ophthalmic Complications of Immune Checkpoint Inhibitors: A Systematic Review. *Eye and Brain*. 2020; 12: 139-167.
- Surveillance, Epidemiology, and End Results (SEER) Program (www.seer.cancer.gov) SEER*Stat Database: Incidence - SEER Research Data, 18 Registries (2000-2018), National Cancer Institute, DCCPS, Surveillance Research Program, released April 2021, based on the November 2020 submission.