



A Rare Manifestation of Peripheral Artery Disease Requiring Urgent Attention from Emergency Physicians

Pu-An Chen¹; Szu-Wei Huang²; Wen-Cheng Huang¹; Chin-Wang Hsu¹; Ying-Kuo Liu^{1*}

¹Emergency Department, Wan Fang Hospital, Taipei Medical University, Taiwan.

²Department of Pediatrics, Wan Fang Hospital, Taipei Medical University, Taiwan.

***Corresponding Author(s): Ying-Kuo Liu**

Emergency Department, Wan Fang Hospital, Taipei

Medical University, Taiwan.

Email: endlessfly@hotmail.com

Received: Mar 08, 2024

Accepted: Mar 26, 2024

Published Online: Mar 29, 2024

Journal: Journal of Clinical Images

Publisher: MedDocs Publishers LLC

Online edition: <http://meddocsonline.org/>

Copyright: © Liu Y-K (2024). *This Article is distributed under the terms of Creative Commons Attribution 4.0 International License*

Clinical Image Description

A 51-year-old male, with a history of heavy smoking and no known comorbidities, presented to the emergency department with sudden numbness in his right toes and right ankle pain, accompanied by coldness in his right foot. Upon examination, there were no signs of claudication, pallor, or cyanosis in his right lower limb, and no limitations in bilateral leg movement, nor any swelling in either leg. The patient denied recent trauma to the back or leg, as well as impotence. Muscle power in both lower limbs was normal, but a weak pulsation of the right dorsalis pedis was noted. Subsequent CT angiography revealed a complete occlusion of the infra-renal abdominal aorta (Figure 1). The patient underwent aorto-left iliac stent grafting, bypass, and balloon angioplasty, and was discharged without complications.

Aortoiliac Occlusive Disease (AIOD), also known as Leriche syndrome, is a rare and severe form of Peripheral Artery Disease (PAD) characterized by the complete occlusion of the infra-renal abdominal aorta and iliac arteries. The triad of Leriche syndrome encompasses erectile dysfunction, pelvis and thigh claudication, and absent femoral pulses [1]. In patients with acute AIOD, symptoms typically manifest as the 6Ps: pain, paralysis, pallor, paresthesia, pulselessness, and poikilothermia. However, the chronic development of a complete occlusion can lead to the formation of significant collateral circulations (Figure 2), reducing the likelihood of the aforementioned ischemic symptoms [2,3]. CT angiography is the preferred diagnostic modality [3], and it is important to note that a comprehensive imaging assessment of the more proximal arteries and even the aorta may be necessary when the symptoms strongly suggest peripheral artery disease but the peripheral arteries appear patent. This is particularly crucial as Leriche syndrome is a rare condition that often results in misdiagnosis.



Cite this article: Chen PA, Huang SW, Huang WC, Hsu CW, Liu YK. A Rare Manifestation of Peripheral Artery Disease Requiring Urgent Attention from Emergency Physicians. *J Clin Images*. 2024; 7(1): 1156.

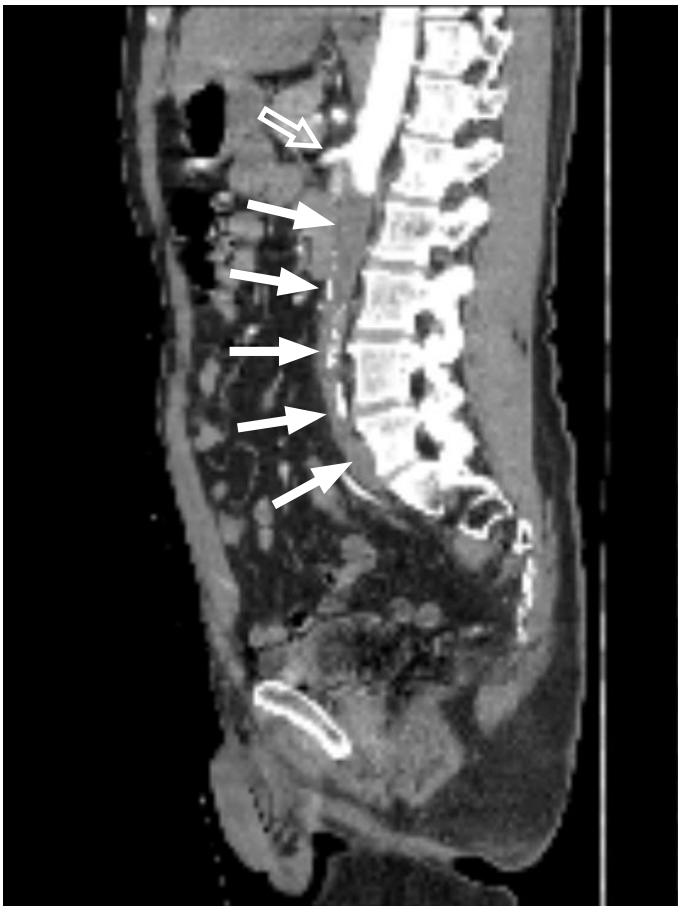

Figure 1: Sagittal view. Occlusion of the infra-renal abdominal aorta (solid arrows). Superior mesenteric artery (hollow arrow).

References

1. Brown KN, Muco E, Gonzalez L. Leriche Syndrome. Treasure Island, FL: Stat Pearls. 2023.
2. Morotti A, Busso M, Cinardo P, Bonomo K, Angelino V, et al. When collateral vessels matter: Asymptomatic Leriche syndrome. Clin Case Rep. 2015; 3(11): 960-1.
3. Ahmed S, Raman SP, Fishman EK. CT angiography and 3D imaging in aortoiliac occlusive disease: Collateral pathways in Leriche syndrome. Abdom Radiol (NY). 2017; 42(9): 2346-2357.

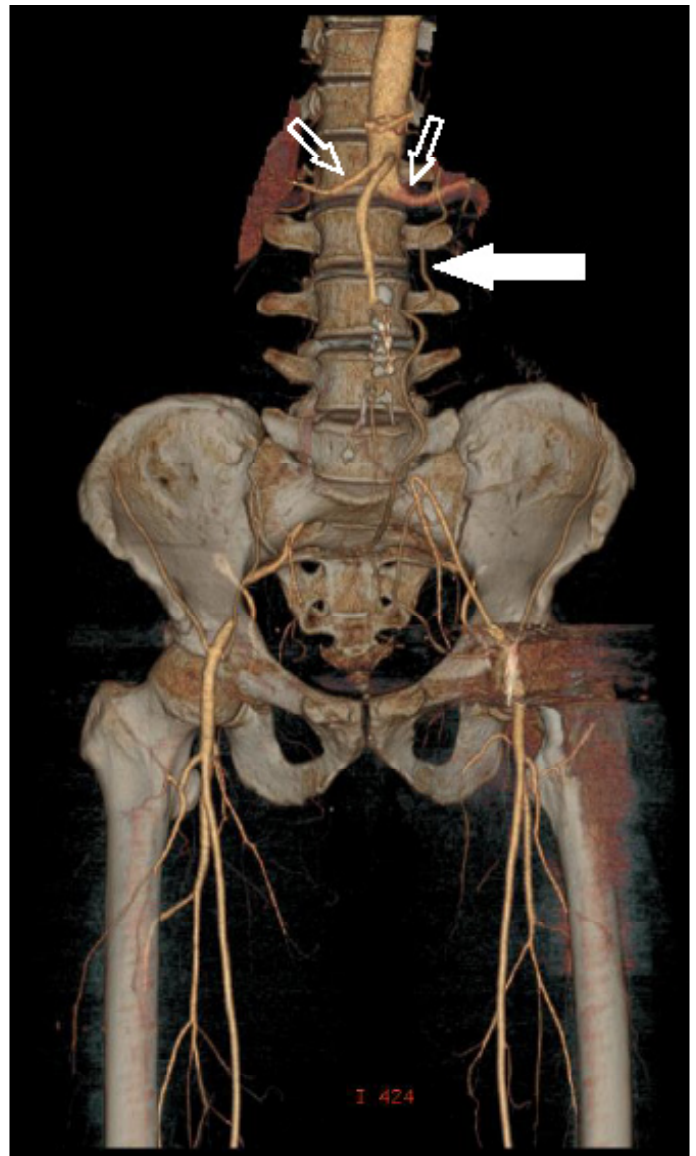


Figure 2: Occlusion of the infra-renal abdominal aorta extending to the proximal left common iliac, and right common and external iliac arteries. Compatible with Leriche syndrome. Revascularization distally at the femoral arteries via collaterals from lumbar arteries (arrow). Bilateral renal artery (two hollow arrows).