



A Rare Case of Respiratory Arrest Following Paralysis: Opioid Toxicity Secondary to Malpositioned Urinary Catheter

Yasmin Toseafa*, Bisola Ajayi; Belal Amini; Darren Lui

Trauma & Orthopaedics 5th Floor St James Wing St Georges Hospital London SW17 0QT, UK.

***Corresponding Author(s): Yasmin Toseafa**

Trauma & Orthopaedics 5th Floor St James Wing St Georges Hospital London SW17 0QT, UK.

Tel: +02086721255;

Email: yasmin.toseafa@stgeorges.nhs.uk

Received: May 14, 2023

Accepted: May 30, 2023

Published Online: Jun 06, 2023

Journal: Journal of Clinical Images

Publisher: MedDocs Publishers LLC

Online edition: <http://meddocsonline.org/>

Copyright: © Toseafa Y (2023). *This Article is distributed under the terms of Creative Commons Attribution 4.0 International License*

Abstract

Spinal cord injury (SCI) patients are susceptible to an increased risk of intra-urethral catheter balloon inflation due to diminished sensation below the level of their injury.

A 65-year-old male was admitted to the intensive care unit following polytrauma. He sustained numerous injuries including complex, multilevel lower thoracic spine fractures, with complete spinal cord injury. He was subsequently catheterised to allow controlled passage of urine and assess fluid balance.

During admission he suffered a respiratory arrest due to opioid toxicity; which was subsequently reversed with naloxone. Further workup revealed a stage 3 Acute Kidney Injury (AKI). Computed Tomography (CT) imaging revealed an inflated catheter balloon within the penile urethra, causing an extremely distended bladder, bilateral hydronephrosis, and a rupture to the collecting system.

Opiate metabolites had accumulated because of poor renal clearance secondary to renal failure from the malpositioned catheter balloon. This was found to be the precipitating factor leading to respiratory arrest.

This rare case highlights the need for appropriate education in catheterisation of SCI patients, to ensure minimal risk of urethral trauma and its associated complications. A high level of suspicion for catheter related injury or incorrect placement of catheter balloon should be considered in SCI patients presenting with reduced kidney function, bypassing, or symptoms of autonomic dysreflexia.



Introduction

Urinary catheterisation is a commonly performed procedure in the hospital setting, and inflating the balloon of a catheter in the urethra is a known complication [1]. Patients with a spinal cord injury (SCI) are at an increased risk for intra-urethral catheter balloon inflation due to diminished sensation below the level of their injury [2].

Opiates are metabolised by the renal system, and thus any renal impairment places patients at a risk of opioid toxicity. This can lead to life threatening respiratory failure.

Although retrospective case studies report several SCI patients who have suffered intra-urethral catheter balloon inflation [1], we report the first case of an SCI patient suffering from opioid toxicity secondary to an AKI directly brought on by urinary retention; as a result of a catheter balloon inflated in the urethra. Furthermore, the urinary retention and resultant large bladder caused compression of the large bowel, which presented as abdominal distension and constipation.

This case demonstrates the importance of the awareness of urinary catheter misplacement in SCI patients and the potential for life threatening complications to occur.

Case Presentation

A 65-year-old male known to psychiatric services was admitted to the Intensive Care Unit (ICU) following polytrauma from a suicide attempt. A trauma series CT scan revealed multiple injuries, including bilateral acetabular fractures, rib fractures with flail segment, lower limb fractures, and significant complex, multilevel spinal fractures. Spinal injuries at the thoracic level from T6-T10 were unstable, with T8 and T9 fractures involving all three spinal columns (AO thoracolumbar spine classification A4N4M2). The patient also sustained displaced fractures from S4-S5. Magnetic Resonance Imaging (MRI) confirmed severe spinal cord injury. Neurological assessment using the American Spinal Injury Association (ASIA) impairment scale, classified this injury as ASIA A T8 (complete spinal cord injury with no motor or sensory function below the affected level)[3].

On day 69 of admission shortly after being stepped down from ICU, the patient was found unresponsive with a Glasgow Coma Score (GCS) of 7. On examination he had pinpoint pupils and a distended, firm abdomen. Of note, the patient had not opened his bowels for several days and although his catheter had been draining, his urine output was poor and fluctuant. An arrest call was made as per Advanced Life Support (ALS)[4] guidelines, and the patient was resuscitated with Naloxone to good effect.

Urgent bloodwork revealed a raised Creatinine (157umol/L; reference range 60-106), raised Urea (20.7 mmol/L; reference range 2.5-7.8), hyperkalaemia (5.6 mmol/L; reference range 3.5-5.3) and a reduced renal function (estimated glomerular filtration rate (eGFR) of 39; reference range > 60 mL/min). These results confirmed patient was in Acute Kidney Injury (AKI) stage 3. A venous blood gas was taken which showed a lactate of 0.7 mmol/L.

Further imaging with CT identified his catheter balloon was positioned within the penile urethra (**Figure 1**), with a grossly distended bladder (**Figure 2**). Moderate fluid was seen surrounding both kidneys and the presence of retroperitoneal fluid combined with proximal ureter dilation was concerning for a bilateral collection system rupture. Extravasation of contrast

surrounded the right kidney, confirming a right collecting system rupture secondary to renal flow obstruction. Contrast was otherwise still seen to be excreted by both kidneys and pass through the ureters.

The indwelling catheter was urgently removed and replaced with a new 16 French foley catheter - 800ml of residual urine was drained, resolving the retention. The urology team advised conservative management for the right collecting system rupture with antibiotic cover as per microbiology advice.

The CT had also shown a prominent large bowel, compressed by the distended bladder at the distal sigmoid colon, likely to be causing some degree of impaired transit. Abdominal bloating and constipation improved shortly after the urinary retention was resolved.

The patient was discharged with a Suprapubic Catheter (SPC) in situ for long term bladder management due to his SCI. This is changed every three months with advice sought from urology. His AKI and partial bowel obstruction have completely resolved. There were no further complications from the catheter inflation in the urethra.

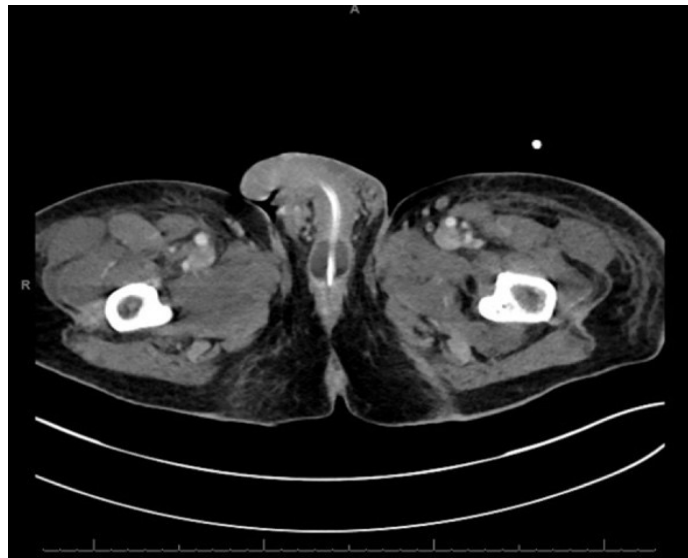


Figure 1a: CT image demonstrating an inflated Foley catheter balloon within the penile urethra.

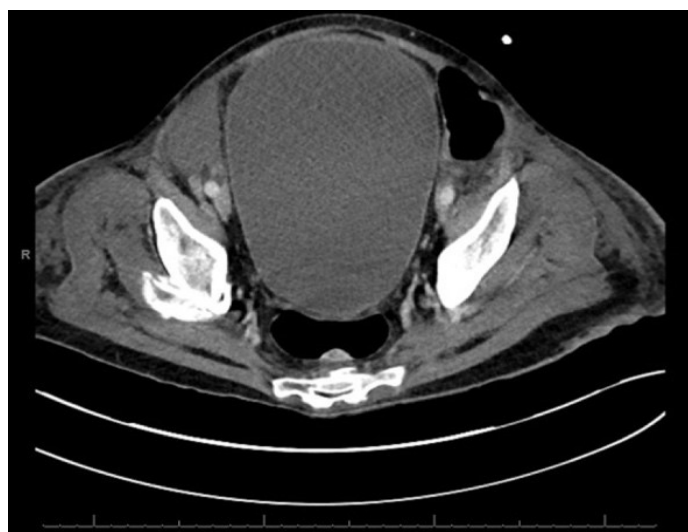

Figure 1b: CT image demonstrating a grossly distended bladder in-keeping with a poorly inserted and non-draining catheter. The large bladder compressed the distal sigmoid colon, slowing transit.

Discussion

For many years, urinary catheters have been used to drain the bladder when it fails to empty, and catheterisation is a common invasive procedure undertaken in healthcare settings. For those who require indwelling catheters, the self-retaining Foley catheter is ubiquitously employed, despite the fact that its use can cause a number of complications. Recurrent infections, bladder stones, and damage to the kidneys, bladder, or urethra; are all risks associated with catheterisation [7].

This report presents a case of both urethral and kidney trauma occurring as a consequence of improper insertion of an indwelling urinary catheter in an SCI patient. These patients are at a higher risk of intra-urethral catheter balloon inflation, due to a lack of sensation in the urethra as a result of their injury, and may not complain of pain or discomfort. Thus, responsible healthcare teams may not be aware that an issue with catheterisation has occurred.

If spinal cord injury patients develop bypassing, or symptoms of autonomic dysreflexia (including headaches, profuse sweating, kidney or lower abdominal pain, increased spasms or the more chronic symptoms of hydronephrosis) following catheterisation, there should be a high level of suspicion for incorrect placement of the catheter[1].

The aforementioned kidney trauma led to our patient into an AKI. AKI is defined as an acute decline in renal function, which encompasses both structural damage and impairment. Acute obstruction of urinary flow increases intra-tubular pressure in the kidneys and thus decreases GFR. Additionally, tract obstruction can lead to impaired renal blood flow and inflammation that can diminish GFR further [8]. As we established, the AKI occurred as a result of urological obstruction and in keeping with NICE guidelines, this patient was immediately referred to a urologist. Although our patient was found to be in AKI stage 3, a clear cause of the injury was identified, and the condition responded promptly to medical management; thus negating the need for a referral to nephrology, as per NICE guidelines on the management of AKI[9].

Opioid metabolites are known to accumulate in renal failure, increasing the potential for toxicity. For example, morphine is metabolised to compounds morphine-3-glucuronide and morphine-6-glucuronide, both of which are excreted via the kidneys. Morphine-6- glucuronide, which is in fact more potent than morphine itself, has a half-life of 50 hours in patients with end stage renal impairment, compared to 3-5 hours in patients with normal renal function. Patients with renal dysfunction are therefore more susceptible to opiate toxicity unless doses are reduced, or the dosing intervals adequately extended [10].

Naloxone, an opioid antagonist that acts as a competitive inhibitor of opioid receptors in the CNS, is licensed for the treatment of overdose with opioids, as outlined in the British National Formulary (BNF) [11].

Bowel obstruction is a common condition, however its occurrence due to bladder distension is rarely reported in literature [12], with even fewer cases presenting with bowel obstruction as the initial sign of urinary retention [13].

In this case, urinary retention occurred due to poor catheter insertion and a failure to recognise said catheter insertion as a possible cause of bowel obstruction. The male urethra is 18-22cm long, and its length is important in relation to how much

of the catheter is needed to reach the bladder. In catheterisation technique, it is advised to advance the catheter until urine begins to drain, and then advance it a further 2.5cm to ensure correct catheter placement and safe balloon inflation [14]. The injuries our patient suffered suggest that these guidelines were not followed during catheterisation.

This case serves to highlight the importance of competent and skilful catheter insertion, especially in SCI patients, and explores some of the complications that occur if this does not happen.

Learning Points

1. Spinal cord injury patients are at increased risk of intra-urethral catheter balloon inflation, due to their lack of sensation in the urethra. Therefore, appropriate education in technique should be given, and care taken; to ensure correct insertion of an indwelling catheter is carried out in a safe manner that minimises the risk of trauma.
2. A high level of suspicion for catheter related injury or incorrect placement of catheter should be applied to catheterised spinal cord injury patients who present with reduced kidney function, bypassing, or symptoms of autonomic dysreflexia.
3. Although rare with a paucity of cases reported in literature, urinary retention may present as complete bowel obstruction. Symptoms usually resolve within several hours of catheterisation.

References

1. Subramanian V, Soni BM, Hughes PL, Singh G, et al. The risk of intra-urethral Foley catheter balloon inflation in spinal cord-injured patients: Lessons learned from a retrospective case series. *Patient Safety in Surgery*. 2016; 10.
2. Harrison SCW. Managing the urinary tract in spinal cord injury. *Indian journal of urology: IJU : journal of the Urological Society of India*. 2010; 26: 245-252.
3. American Spinal Injury Association. International Standards for Neurological Classification of SCI (ISNCSCI) Worksheet. 2021.
4. Resuscitation Council UK. Adult Advanced Life Support Guidelines. 2021.
5. Royal National Orthopaedic Hospital. Autonomic Dysreflexia. 2021.
6. Bycroft J, Shergill IS, Choong EAL, Ayra N, Shah PJR. Autonomic dysreflexia: a medical emergency. *Postgraduate Medical Journal*. 2005; 81.
7. Feneley RCL, Hopley IB, Wells PNT. Urinary catheters: history, current status, adverse events and research agenda. *Journal of Medical Engineering & Technology*. 2015; 39.
8. Makris K, Spanou L. Acute Kidney Injury: Definition, Pathophysiology and Clinical Phenotypes. *The Clinical biochemist Reviews*. 2016; 37: 85-98.
9. National Institute for Health and Care Excellence (NICE). Acute kidney injury: prevention, detection and management. 2019.
10. Conway BR, Fogarty DG, Nelson WE, Doherty CC. Opiate toxicity in patients with renal failure. *BMJ*. 2006; 33.
11. British National Formulary (BNF). Naloxone Hydrochloride. 2021.
12. Fujisaki T, Fujita Y, Mizuta H, Niina N, Miyazaki N, Tashiro A, et al. Large bowel obstruction caused by urinary retention from

benign prostate hyperplasia. Radiology case reports. 2018; 14: 213-216.

13. Papeš D, Altarac S, Arslani N, Rajković Z. Urinary retention presenting as complete bowel obstruction. Canadian Urological Association journal = Journal de l'Association des urologues du Canada. 2013; 7: E637-639.
14. Pullen RLJR. Inserting an indwelling urinary catheter in a male patientA. Nursing. 2004; 34.