



A 11 week's Gestation Ruptured Tubal Ectopic Pregnancy: A Case Report

Derqaoui Sabrina*; **EL Majoudi Salma**; **Rouas Lamia**; **Lamalmi Najat**

Department of Pathology, maternity and Children's Hospital Ibn Sina University Hospital, Rabat, Morocco.

***Corresponding Author(s): Sabrina Derqaoui**

Ibn Sina Teaching Hospital, Abderrahim bouabid avenue, Rabat, Morocco.

Tel: 212653033356, Fax: 212537646564;

Email: s.derqaoui@gmail.com

Received: Jan 04, 2021

Accepted: Feb 22, 2021

Published Online: Feb 25, 2021

Journal: Journal of Clinical Images

Publisher: MedDocs Publishers LLC

Online edition: <http://meddocsonline.org/>

Copyright: © Derqaoui S (2021). *This Article is distributed under the terms of Creative Commons Attribution 4.0 International License*

Key words: Tubal pregnancy; Clinical image; Case report.

Clinical Image description

Background: Ectopic pregnancy is a common condition, with a reported incidence of approximately 2% among all pregnancies [1], Fallopian tubes represent the most involved implantation's site (>98%). However, advanced ectopic tubal pregnancy is uncommon, and might be life-threatening [2].

Case presentation: A 40 years women presented to the emergency department with abdominal pain and a history of irregular menstrual cycles. Upon physical examination, she had stable vital signs with abdominal tenderness. BHCG levels in the blood were very high. Ultrasonography imaging revealed an 11 weeks tubal pregnancy (fetal heart positive activity) and moderate peritoneal effusion suggestive of rupture. Laparotomy confirmed these findings; The patient underwent salpingectomy. On

gross, the specimen consisted of a right fallopian tube measuring 6,5 cm (length) x5 cm (diameter) with a distended ruptured segment containing fetus, membranes and placenta. The fetus measured 4, 5 cm (crown to rump) and weighed 22.5 g. The head circumference was 3,6cm. The vertebral column was intact. There was no patency of eyes, nose, mouth or anus. No craniofacial defects were grossly identified. The skin had normal appearance. The placenta measured 4,6 x4,2 cm weighed 50 g, with an eccentrically attached umbilical cord, measuring 3.6 x 0.4 cm, showing 3 vessels at sectioning. Histological examination revealed normal fetal tissue and placenta. Fallopian tube showed extensive hemorrhage with chorionic villi in the wall and decidual change in lamina propria [1,2].



Cite this article: Derqaoui S, Salma ELM, Lamia R, Najat L. A 11 week's Gestation Ruptured Tubal Ectopic Pregnancy: A Case Report. J Clin Images. 2021; 4(1); 1089.

Conclusion: Advanced ectopic pregnancy is a life-threatening condition. Early diagnosis is necessary to avoid salpingectomy; which compromises fertility in patients wishing future pregnancy.

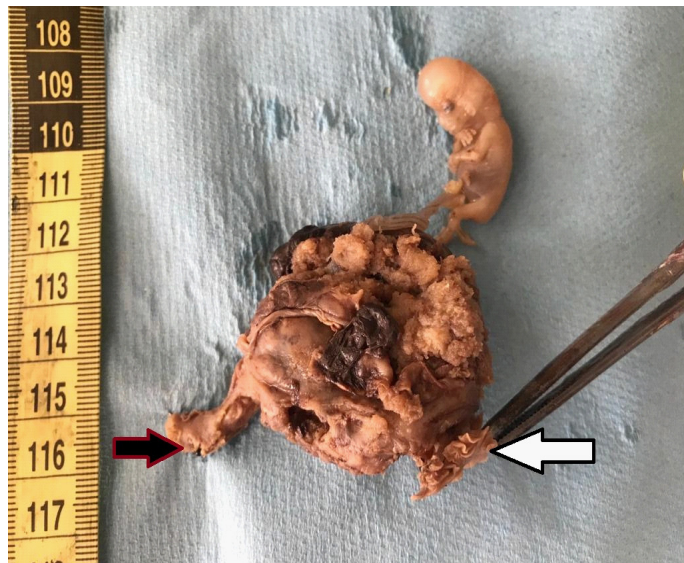


Figure 1: Ectopic tubal pregnancy: fimbriae (with arrow) ampulla (black arrow).

References

1. Caitlin Gauvin, Melissa Amberger, Kevin Louie, Olga Argeros ; Previously asymptomatic ruptured tubal ectopic pregnancy at over 10 weeks' gestation: Two case reports, *Case Reports in Women's Health*. 2019; 21: e00089.
2. Xu, Hong Bachelor' Degree of Medicine. A spontaneous bilateral tubal pregnancy, *Medicine*. 2018; 97: p e12365.