



Will Mosquito Bite Causes Infertility? – A Case Report

Taranya R^{1*}; Shanmugapriya N²; Kalpana S¹; Srinivas G¹; Jasmine S Sundar¹; Valarmathi S¹; Ramkumar G²

¹Department of Epidemiology, The Tamilnadu Dr. MGR Medical University, Chennai, India.

²Department of Obstetrics and Gynecology, Eswari Nursing Home, Chennai, India.

*Corresponding Author(s): Taranya R

Department of Epidemiology, University the Tamilnadu
Dr. MGR Medical University, India.

Tel: +91-9171-8888-26; Email: drtaranya@gmail.com &
taranya.bhms@gmail.com

Received: Mar 23, 2023

Accepted: Apr 10, 2023

Published Online: Apr 17, 2023

Journal: Journal of Case Reports and Medical Images

Publisher: MedDocs Publishers LLC

Online edition: <http://meddocsonline.org/>

Copyright: © Taranya R (2023). *This Article is distributed under the terms of Creative Commons Attribution 4.0 International License*

Keywords: Filariasis; Infertility; Wuchereria Bancrofti.

Abstract

Filariasis is a rare disease which is a parasitic infection caused by *Wuchereria Bancrofti*. In 2006 there were 50 million people infected with or without symptoms. In 2005 95% of the cases in India were in Andhra Pradesh, Bihar, Gujarat, Kerala, Maharashtra, Orissa, Tamil Nadu, Uttar Pradesh and West Bengal [1].

India has almost 40% of the world's lymphatic filariasis cases. 2000 survey reported that about half the people in India were at risk of getting Lymphatic filariasis. Men and women are equally susceptible. An estimate from the year 2000 reported that filariasis in India caused an annual economic loss for about ₹5000 crores [1].

A 21 years old female with Primary Infertility accidentally diagnosed with Case of Ovarian Filariasis during Ultrasound examination. Ultrasound pelvis done which revealed Left adnexal mass which showed random movements inside that is Filarial Dancing Sign. Patient was treated with a course of Anti Filarial tablet Diethylcarbamazine with Deworming medicine Albendazole and Anti-viral drug T. Ivoral forte and follow up done after which the patient got pregnant.

Introduction

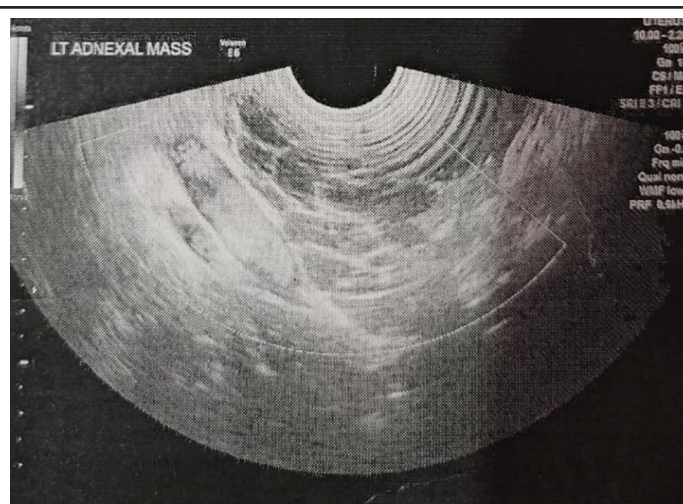
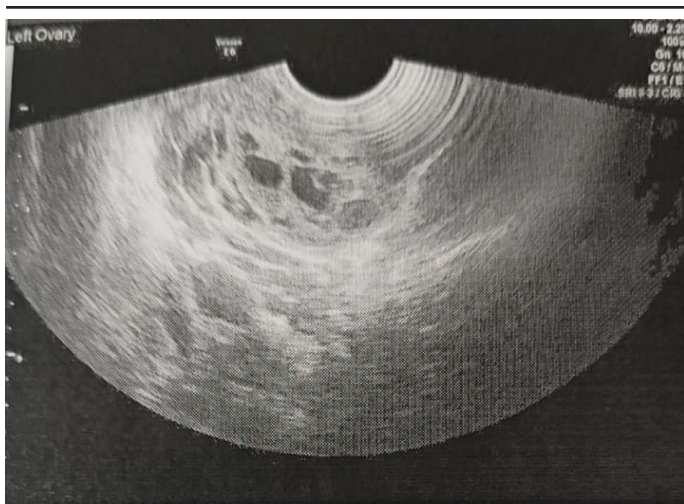
Filariasis also known as Elephantiasis which is an second leading cause of disability next to the Malaria [2]. Filariasis impairs the Lymphatic system which causes enlargement of the body parts which may be usually unilateral and causes pain, disability and social stigma. Lymphatic filariasis is caused by nematodes such as *Wuchereria bancrofti*, *Brugia malayi* and *Brugia timori* [3]. It is a vector-borne disease caused by *Culex* group of mosquitoes. The common symptoms of filariasis are Fever especially at night with Unilateral and non-pitting swelling of limbs. It usually diagnosed with Peripheral blood smear. Ovarian filariasis is an extremely rare case of Filariasis. According to the literature review, the ovarian filariasis is found accidentally in Histopathological report following Surgery [4].

Case report

A 21 years od female, Married, Nulliparous women with Regular menstrual cycle has come for Infertility Out Patient Department with case of No issues since 9 months. Patient doesn't have any history of fever, swelling or pedal oedema. No associated symptoms related to the diagnosis were obtained. While doing Ultrasound examination of Abdomen, A cystic mass lesion noted in the left adnexa with Echogenic particles showing random movements within one of the follicles in the left ovary- "Dancing Filarial Sign" noticed and diagnosed with Left Ovarian filariasis. Then she was treated with single dose of Tab. Ivoral forte (Albendazole and Ivermectin) and Tab. Hetrazon 100mg (Diethylcarbamazine) Thrice a day for 2 weeks.

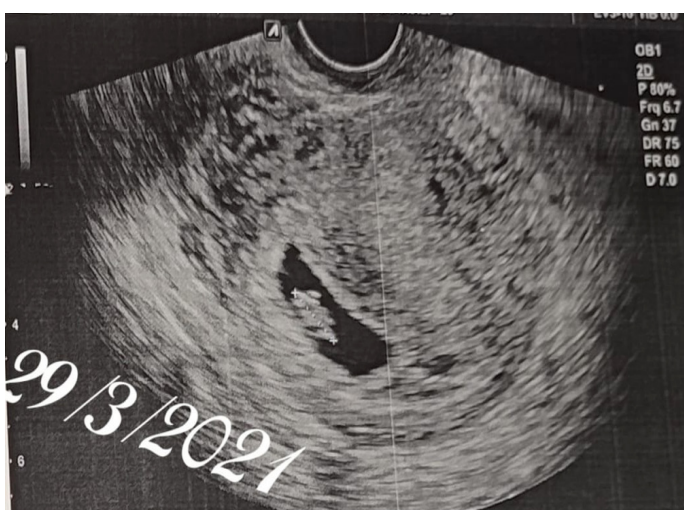


Cite this article: Taranya R, Shanmugapriya N, Kalpana S, Srinivas G, Sundar JS, et al. Will Mosquito Bite Causes Infertility? – A Case Report. J Case Rep Clin Images. 2023; 6(1): 1138.



Results

The follow up Ultra sound scan was performed which showed reduction in size of the cystic lesion without any movements inside. A few months later the patient got positive for pregnancy.



Acknowledgement

We acknowledge the efforts from Department of Obstetrics and Gynecology and Department of General Medicine from Es-wari Nursing Home, Chennai, Tamilnadu, India for the support and I acknowledge the support from the staffs, Department of Epidemiology, The Tamilnadu Dr. MGR Medical University, Chennai, India in completing this case report.

Declaration of competing interest: None declared.

Sources of funding: No funding has been received.

Ethical approval: Exempted as ethical approval not required.

Consent informed: Written consent was taken from the patient for the publication of this manuscript and any images associated with it.

References

1. Lymphatic filariasis in India. In: Wikipedia. 2023.
2. Brahim D, Alain Didier A, Gonat Serge Pacôme D, Nguissan Alphonse A, Abdoul K, et al. A Rare Case of Ovarian Filariasis in Abidjan. *Case Rep Pathol.* 2016; 2016: 4075162.
3. Vasantham V, Yadav SK, Sarin N, Singh S, Pruthi SK. Incidental detection of microfilaria in cyst fluid of Mucinous cystadenocarcinoma of ovary: A rare case report. *Int J Surg Case Rep.* 2020; 70: 56-59.
4. Datta MR, Ghosh MD, Kumari V, Narayan R. Mosquito Bite and Adnexal Mass: The Unusual Diagnosis of Ovarian Filariasis. *Cureus.* 2021; 13.