



# Vascular Complications in a Patient Presenting With Headache

*Leticia Santos\**; *Vilma Grilo*; *Maria Inês Marques*; *Filipa Monteiro*; *Sara Ramalho*; *Conceição Escarigo*; *Rita Nortadas*  
*Medicina Interna, Hospital Garcia de Orta, Portugal.*

**\*Corresponding Author(s): Leticia Santos**

Medicina Interna, Hospital Garcia de Orta, Portugal.

Email: leticia93santos@gmail.com

Received: Nov 18, 2021

Accepted: Dec 23, 2021

Published Online: Dec 27, 2021

Journal: Journal of Case Reports and Medical Images

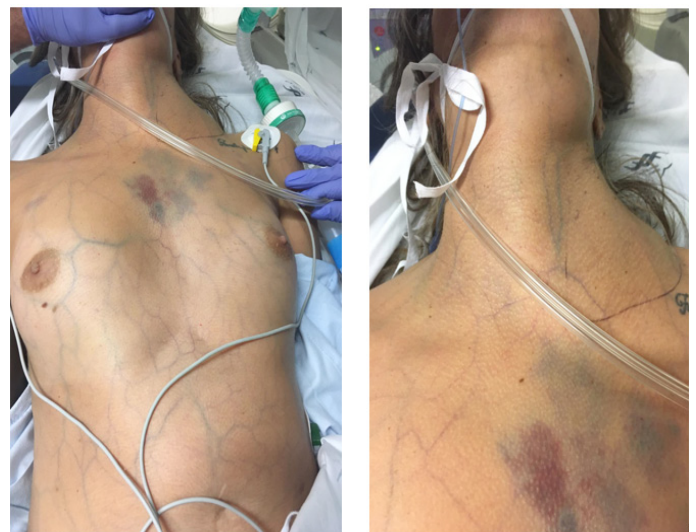
Publisher: MedDocs Publishers LLC

Online edition: <http://meddocsonline.org/>

Copyright: © Santos L (2021). *This Article is distributed under the terms of Creative Commons Attribution 4.0 International License*

## Clinical image description

A 35-year-old female with a history of migraine was admitted to the emergency department with severe headache with normal neurological exam. The patient evolved to convulsive crisis with identification of a non-pulsatile left cervical hematoma, chest wall hematoma and exuberant collateral venous circulation (observed in the images). Subarachnoid hemorrhage with tetraventricular flooding and anterior communicating aneurysm were diagnosed and the attempt at endovascular embolization was complicated by dissection of the abdominal aorta. A systemic disease of collagen was suspected.



**Cite this article:** Santos L, Grilo V, Marques MI, Monteiro F, Ramalho S, et al. Vascular Complications in a Patient Presenting With Headache. *J Case Rep Clin Images*. 2021; 4(2): 1094.