



# Treatment of CMC dislocation associated with hamate fracture; Case report of three cases

Ragna C Jonker\*; Hugo D Ammerlaan; Eric E J Raven

Department of Orthopaedic Surgery, Gelre Hospital Apeldoorn, PO Box 9014, 7300 DS Apeldoorn, The Netherlands

**\*Corresponding Author(s): Ragna C Jonker**

Department of Orthopaedic Surgery, Gelre Hospital Apeldoorn, PO Box 9014, 7300 DS Apeldoorn, The Netherlands

Email: ragna.jonker@gelre.nl & e.raven@gelre.nl

**Abstract**

Dislocation of the fourth and fifth carpometacarpal (CMC) joint associated with a fracture of the hamate is a rare injury. Literature shows no consensus regarding optimal treatment of this injury. We present three cases that will discuss this specific injury and all have been treated according to the same philosophy; reconstruction of the hamate to get a stable joint. No residual symptoms were reported at follow-up. We suggest that adjuvant stabilization of the CMC joints is not required.

Received: Dec 31, 2019

Accepted: Feb 26, 2020

Published Online: Feb 28, 2020

Journal: Journal of Case Reports and Medical Images

Publisher: MedDocs Publishers LLC

Online edition: <http://meddocsonline.org/>

Copyright: © Jonker RC (2020). *This Article is distributed under the terms of Creative Commons Attribution 4.0 International License*

## Introduction

Dislocation of the fourth and fifth Carpometacarpal (CMC) joint is a rare injury and may easily be missed [1,2]. These injuries are complex and regularly associated with carpal fractures, such as a hamate fracture. The mechanism of injury is often an axially directed force along the fourth and fifth metacarpal with a clenched fist. This results in a proximal and dorsal subluxation of the metacarpal bases, which produces a dorsal traction force along the dorsal fourth and fifth CMC ligaments and may cause avulsion of the dorsal rim of the hamate [3]. The displacement is accentuated by the pull of the extensor carpi ulnaris which is attached to the base of the metacarpal.

A delayed or missed diagnosis that leads to inadequate treatment, may result in poor outcome and long-term functional disability [4]. However, since hamatometacarpal fracture dislocations are rare, there is no consensus regarding optimal treatment. Options run from closed reduction with cast immobilization to percutaneous pinning or open reduction and internal fixation [1,4–8].

We present three cases of young males with hamatometacarpal fracture dislocations after a direct trauma with a clenched fist, seen in our hospital between 2015 and 2017. All three cases were treated by open reduction and internal fixation of the hamate.

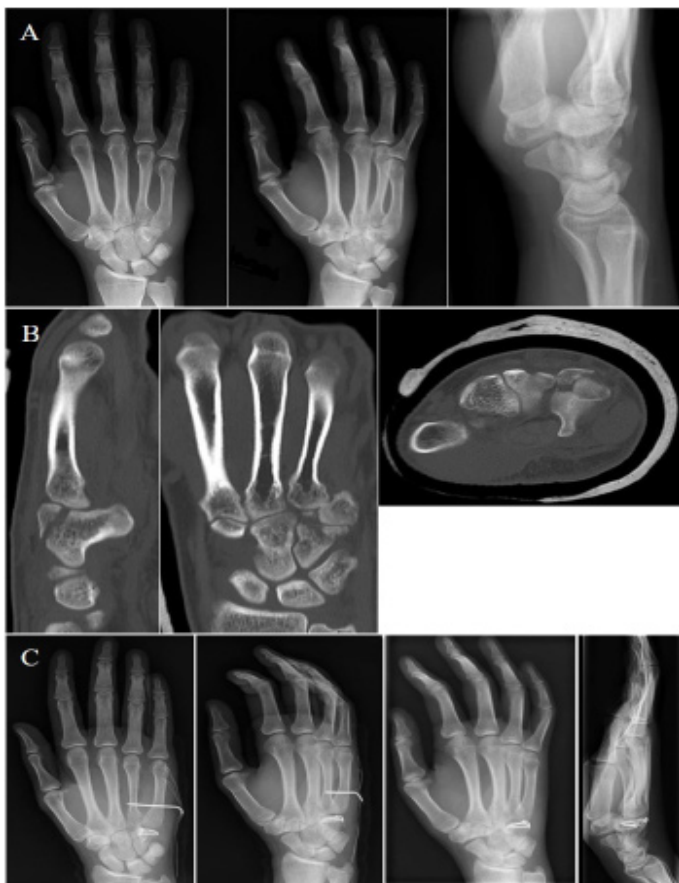

**Cite this article:** Jonker RC, Ammerlaan HD, Raven EEJ. Treatment of CMC dislocation associated with hamate fracture; Case report of three cases. *J Case Rep Clin Images*. 2020; 3(1): 1036.

## Case presentations, diagnosis and treatment

## Case 1

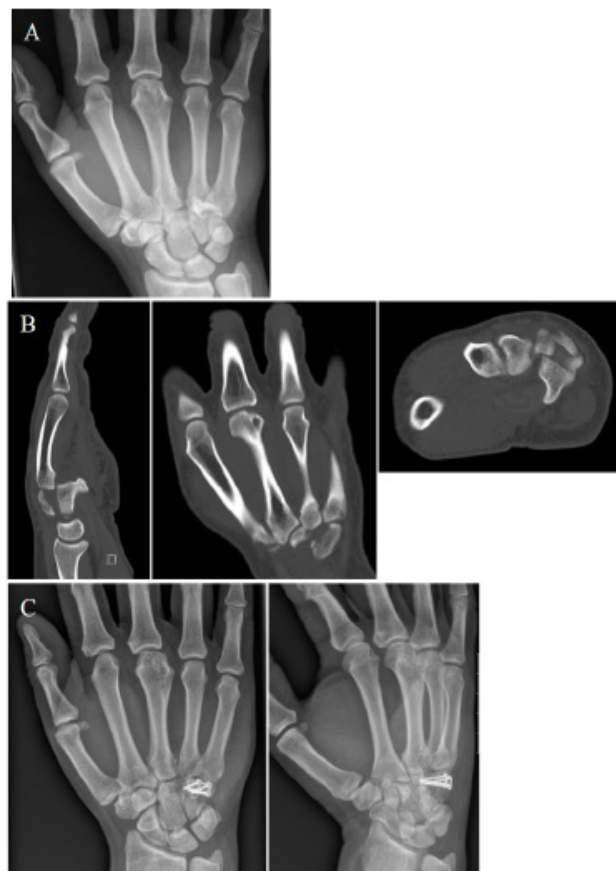A 23-year-old male presents himself at the emergency department with pain and swelling of the right fourth and fifth CMC joint after hitting a closet during a rage of anger. Conventional radiographic images showed a dislocation of CMC four and five (Figure 1A), additional computed tomography showed a comminutive fracture of the hamate with dislocation of CMC five into the core of the hamate (Figure 1B). After one week of cast immobilization to reduce the swelling, we performed open reduction and internal fixation. A dorsal approach at CMC 4-5 was used. After transfixating CMC five to CMC four, the comminutive fracture of the hamate was reconstructed and stabilized with a plate (Stryker Profyle Small Bone Plating System) and two screws. The CMC joint was reconstructed and felt stable. Post-operative radiographic images showed an anatomical reconstruction (Figure 1C). The transfixation of CMC four and five was removed after two weeks. After four weeks of cast immobilization, the patient started with hand therapy. Six weeks after surgery, the range of motion of the digits was similar to the contralateral side and radiographic images showed no post-traumatic abnormalities (Figure 1C). After 12 weeks normal life was resumed without residual symptoms.



**Figure 1:** Radiographic images of case 1 – **A.** Radiographs after trauma showing dislocation of CMC four and five. **B.** Computed Tomography showing a comminutive fracture of the hamate with dislocation of CMC five into the core of the hamate. **C.** Radiographs after open reduction and internal fixation, CMC five was to transfixated CMC four and the comminutive fracture of the hamate was reconstructed and stabilized with a plate and screws.

## Case 2

The second case concerns a 40-year-old male with pain and swelling at the base of his right fourth and fifth CMC joint after he fell down the stairs and hit the wall with his right fist. Conventional radiographic images showed a dislocation of CMC four and five (Figure 2A), additional computed tomography showed a longitudinal fracture of the hamate with dislocation of CMC four and five (Figure 2B). We performed open reduction and internal fixation that same day, using a dorsal approach at CMC 4-5. After reduction of CMC four and five, the hamate was reconstructed with a plate (Stryker Profyle Small Bone Plating System) and two screws, which resulted in a stable CMC joint. After four weeks of cast immobilization, hand therapy was started. Radiographic images six weeks after surgery, showed a normal osteo-articular ratio (Figure 2C). Physical examination showed a similar range of motion of the hand compared to the contralateral side. The patient was lost in follow-up after 6 weeks.



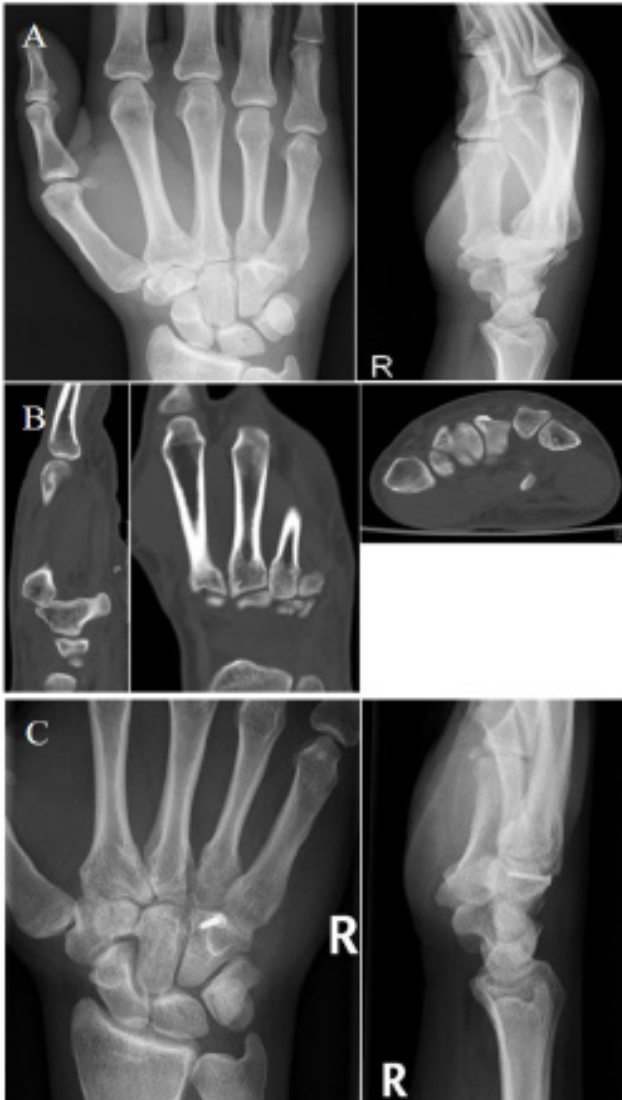**Figure 2:** Radiographic images of case 2 – **A.** Radiographs after trauma showing dislocation of CMC four and five. **B.** Computed Tomography showing a longitudinal fracture of the hamate with dislocation of CMC four and five. **C.** Radiographs after open reduction and internal fixation, the hamate was reconstructed with a plate screws.

## Case 3

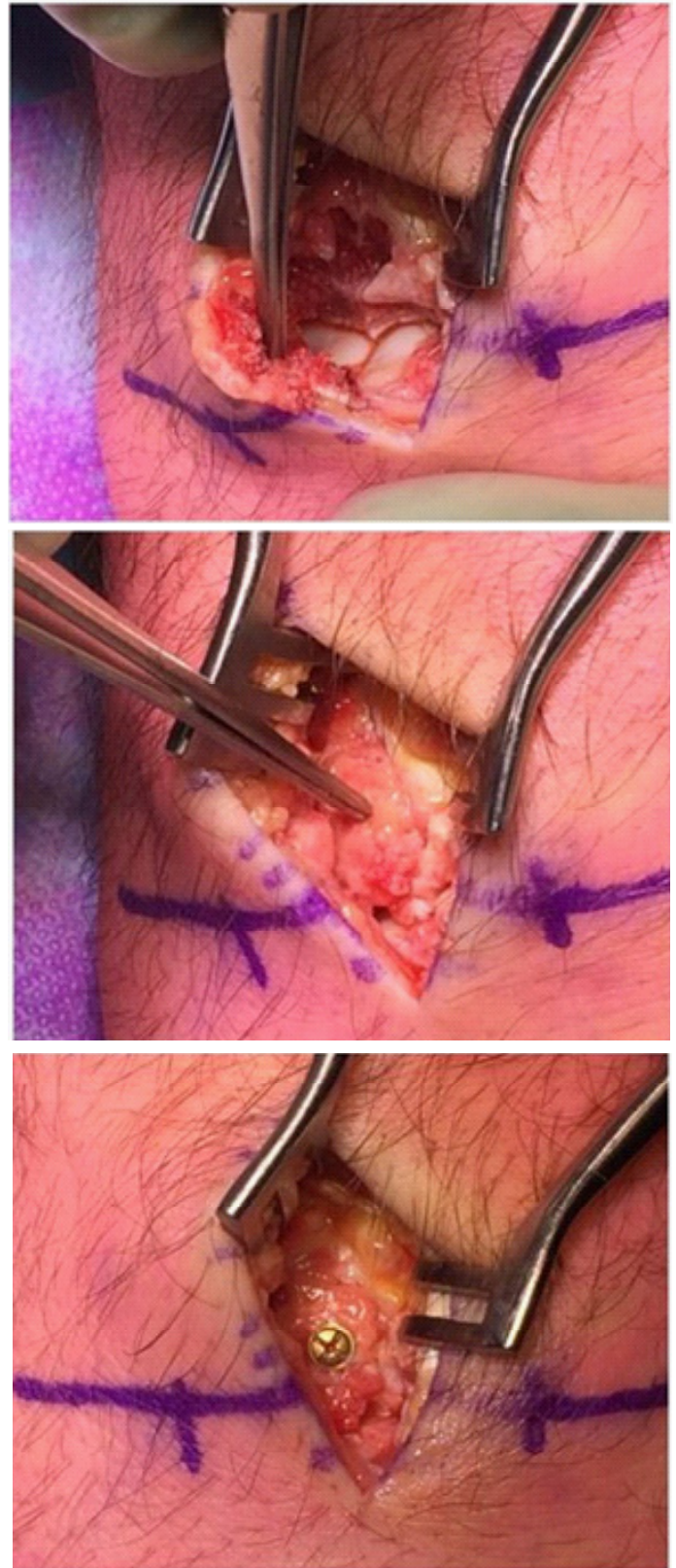
The third case concerns a 29-year-old male who hit a wall with his right fist after a moment of frustration. He presented himself at the emergency department with pain and swelling at the dorso-ulnar side of his right hand. Conventional radiographic images showed a dislocation of CMC four and five with a bone fragment on the dorsal side of the carpalia (Figure 3A). Additional computed tomography showed an isolated fracture of the hamate with dislocation of CMC four and five (Figure 3B). Open reduction and internal fixation surgery was performed



after a couple of days, using the same dorsal approach as in the previous cases. After the hamate was reconstructed and fixated with one screw, a stable CMC joint was obtained (Figure 4). Hand therapy was started after three weeks of cast immobilization. Six weeks after surgery, the range of motion of the digits was similar to the contralateral side and radiographic images showed an anatomical osteo-articular ratio (figure 3C). After 12 weeks normal life routine was resumed.



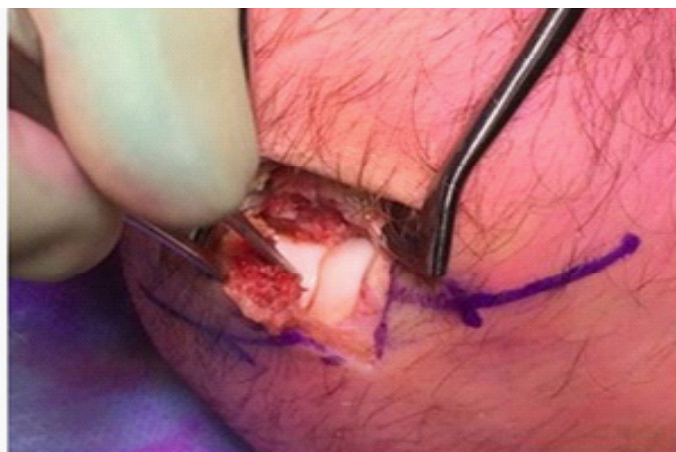**Figure 3:** Radiographic images of case 2 – A. Radiographs after trauma showing dislocation of CMC four and five with a bone fragment on the dorsal side of the carpalia. B. Computed Tomography showing a dorsal fracture of the hamate with dislocation of CMC four and five. C. Radiographs after open reduction and internal fixation, the hamate was reconstructed and fixated with one screw.



**Figure 4:** Open reduction and internal fixation of case 3. - A dorsal longitudinal approach was used and care was taken to protect the dorsal sensory branch of the ulnar nerve. The hamate fracture was identified and CMC four and five were reduced. After reconstruction of the hamate and fixation with one screw stable CMC joints were obtained.

**Discussion**

Hamatometacarpal fracture dislocations are extremely rare injuries, the mechanism of injury is often an axially directed force along the fourth and fifth metacarpal with a clenched fist. The most important finding of this present report is that after



fixation of the hamate fracture, stable CMC joints were obtained in all three cases without joint stabilization.

The fourth and fifth CMC joints articulate by two concave facets separated by a ridge. The concave-convex facet at the base of the fifth metacarpal articulates with the hamate, whereas the fourth metacarpal articulates by a flat radial facet. These intermetacarpal joints are stabilized by dorsal, volar and interosseous ligaments [1,9]. Although dorsal ligaments may be stronger than volar ligaments, the most common direction of dislocation is dorsally due to the force direction and position of the CMC joints with a clenched fist blow [3,8]. Yoshida et al. [3] showed in a fresh-frozen cadaver study that a dorsal hamate fracture is the third most common CMC fracture injury and the most common combination of fractures is a dorsal hamate fracture combined with a dorsal capitate fracture. Despite their expanding knowledge on pathomechanics and pathoanatomy of fracture dislocations of the fourth and fifth CMC joint, still little is known about the optimal treatment of these injuries.

Cain et al. [5] classified 17 patients with a fourth metacarpal fracture, dislocation of the fifth CMC joint and associated fracture of the hamate, into three types of injury. They particularly described three cases in which the hamatometacarpal fracture dislocation was unstable and open reduction and fixation with Kirschner wires was needed. Steinmetz et al. [8] retrospectively evaluated treatment outcomes of eighty patients with CMC injuries of the second to fifth digits. The most common injury was a fist blow, whether or not associated with high-energy trauma. Injuries of the fourth and fifth CMC joints were most common and frequently associated with isolated or combined hamate fractures (n=10 and n=18). Ninety percent of all patients with CMC injuries were treated by closed reduction and percutaneous fixation. Ten percent was treated by open reduction and internal fixation. However, no details were given on the treatment in specific patient groups, so no treatment details of associated hamate fractures. Zhang et al. [4] reported on 20 patients with acute hamatometacarpal fracture dislocation with good results after closed reduction. However, conservative treatment after a delayed diagnosis resulted in pain, limited range of motion and decreased grip strength. Two case reports of Brinkman et al. [6] and Gil et al. [7], reporting on dislocation of CMC two to five combined with a hamate fracture, were successfully treated by percutaneous transfixation. Gil et al. [7] also reported a stable CMC five joint after only open reduction and internal fixation of the hamate by a single screw, no additional fixation of the CMC joint was required.

In our three cases all patients were treated by open re-

duction and internal fixation of the hamate fracture followed by cast immobilization for three to four weeks. Hand therapy was started and a radiographic images were made after six weeks of follow-up. At six and 12 weeks of follow-up all patients had a normal range of motion of the fourth and fifth digit similar to the contralateral side. Strength was normal and there were no residual symptoms. In conclusion, this suggests that hamatometacarpal fracture dislocations can be treated with open reduction and internal fixation of the hamate and adjuvant fixation of the CMC joints is not required.

## References

1. Day CS. Fractures of the Metacarpals and Phalanges. In: Wolfe SW, Hotchkiss RN, Pederson WC, Kozin SH CM, ed. *Green's Operative Hand Surgery*. Seventh. Philadelphia: Elsevier Inc.; 2016: 244-246.
2. Fisher MR, Rogers LF, Hendrix RW. Systematic approach to identifying fourth and fifth carpometacarpal joint dislocations. *Am J Roentgenol*. 1983; 140: 319-324.
3. Yoshida R, Shah MA, Patterson RM, Buford WL, Knighten J, Viegas SF. Anatomy and Pathomechanics of Ring and Small Finger Carpometacarpal Joint Injuries. *J Hand Surg Am*. 2003; 28: 1035-1043.
4. Zhang C, Wang H, Liang C, Yu W, Li Y, et al. The effect of timing on the treatment and outcome of combined fourth and fifth carpometacarpal fracture dislocations. *J Hand Surg Am*. 2015; 40: 2169-2175.
5. Cain JE, Shepler TR, Wilson MR. Hamatometacarpal fracture-dislocation: Classification and treatment. *J Hand Surg Am*. 1987; 12: 762-767.
6. Brinkman JN, Hartholt KA, De Vries MR. Multiple carpometacarpal dislocations and an associated fracture of the hamate: An uncommon injury. *BMJ Case Rep*. 2016: 1-4.
7. Gil JA, Goodman AD, Starr A. Coronal Hamate Fracture Associated With Carpometacarpal Dislocations of All of the Fingers: Review of the Literature and Case Report. *Hand (N Y)*. 2017; 12: NP51-NP54.
8. Steinmetz G, Corning E, Hulse T, Fitzgerald C, Holy F, et al. Carpometacarpal Fracture-Dislocations: A Retrospective Review of Injury Characteristics and Radiographic Outcomes. *Hand (N Y)*. 2019: 1-6.
9. Nakamura K, Patterson RM, Viegas SF. The ligament and skeletal anatomy of the second through fifth carpometacarpal joints and adjacent structures. *J Hand Surg Am*. 2001; 26: 1016-1029.