



The Administration of Naloxone to Reverse a Case of Cocaine-Induced Complete Heart Block

Ayesha Iqbal¹; Oluwafemi Augustine Ajibola^{1*}; Susan Collins¹; Matthew Apedo¹; Taiwo Opeyemi Aremu^{2,3}; Oluwatosin Esther Oluwole⁴; Pang Lam¹

¹Department of Medicine, Vassar Brothers Medical Center, Nuvance Health, 45 Reade Place, Poughkeepsie, NY 12601, USA.

²Department of Pharmaceutical Care and Health Systems (PCHS), College of Pharmacy, University of Minnesota, 308 Harvard Street SE, Minneapolis, MN 55455, USA.

³Division of Environmental Health Sciences, School of Public Health, University of Minnesota, 420 Delaware Street SE, Minneapolis, MN 55455, USA.

⁴Division of Epidemiology & Community Health, School of Public Health, University of Minnesota, 300 West Bank Office Building, 1300 S. 2nd Street, Minneapolis, MN 55454, USA.

***Corresponding Author(s): Oluwafemi Augustine Ajibola**

Department of Medicine, Nuvance Health, Vassar Brothers Medical Center, 45 Reade Place, Poughkeepsie, NY 12601, USA.

Tel: 570-520-8321;

Email: oluwafemiaajibola@gmail.com

Abstract

Cocaine is a stimulant drug derived from coca plants and known for its addictive potential and toxicity, including cardiovascular complications. Complete heart block is a cardiovascular manifestation of cocaine toxicity, which can be life threatening. We present a case of a 49-year-old woman that presented with abdominal pain, diarrhea, and vomiting. With abnormal EKG readings, the patient was found to have a complete heart block from cocaine ingestion. Interestingly, the administration of naloxone resulted in a complete conversion of the abnormal heart rhythm to normal sinus rhythm, requiring no pacemaker.

Received: Nov 08, 2021

Accepted: Dec 13, 2021

Published Online: Dec 16, 2021

Journal: Journal of Case Reports and Medical Images

Publisher: MedDocs Publishers LLC

Online edition: <http://meddocsonline.org/>

Copyright: © Ajibola OA (2021). *This Article is distributed under the terms of Creative Commons Attribution 4.0 International License*

Keywords: Cocaine toxicity; Cardiovascular; Heart block; Naloxone; Pacemaker.

Abbreviations: CPAP: Continuous Positive Airway Pressure; IV: Intravenous; WBC: White Blood Cell; BUN: Blood Urea Nitrogen; ALT: Alanine Transaminase; AST: Aspartate Transaminase; INR: International Normalized Ratio; EKG: Electrocardiogram; CT: Computerized Tomography; CRRT: Continuous Renal Replacement Therapy; MAP: Mean Arterial Pressure; CNS: Central Nervous System; BIPAP: Bilevel Positive Airway Pressure.

Cite this article: Iqbal A, Ajibola OA, Collins S, Apedo M, Aremu TO, et al. The Administration of Naloxone to Reverse a Case of Cocaine-Induced Complete Heart Block. *J Case Rep Clin Images*. 2021; 4(2): 1091.



Background

Cocaine is an alkaloid, which was derived from the following species of plants: *Erythroxylum coca* and *Erythroxylum novogranatense* [1]. Cocaine is primarily known for its abuse potential and toxicity, which presents a wide array of clinical presentations. One of the very detrimental effects of cocaine toxicity is cardiovascular sequelae. Cardiovascular manifestations include hypertension, myocardial infarction, heart failure, cardiomyopathies, arrhythmias, aortic dissection, and endocarditis [2]. Cocaine stimulates the sympathetic nervous system by inhibiting catecholamine reuptake at the synapse and results in tachyarrhythmias. Cocaine can also block voltage gated sodium channels resulting in bradyarrhythmia and conduction abnormalities [2]. Hence, the arrhythmia associated with cocaine ranges from tachyarrhythmia to bradyarrhythmia. We present a case where the administration of naloxone reversed a case of cocaine-induced complete heart block that required a pacemaker.

Case presentation

A 49-year-old woman with history of asthma, coronary artery disease, hyperlipidemia, mechanical mitral valve, chronic diastolic heart failure, peptic ulcer disease, morbid obesity, sleep apnea on Continuous Positive Airway Pressure (CPAP) machine, anxiety, and depression. Home medications include albuterol inhaler, fluticasone-salmeterol, tiotropium, aspirin, warfarin, atorvastatin, furosemide, gabapentin, citalopram, quetiapine, clonazepam, and pantoprazole. The patient presented to the emergency department with a three-day history of abdominal pain, diarrhea, and vomiting. The initial vital signs showed a temperature of 98.1°F, a heart rate of 32bpm, respiratory rate of 13bpm, blood pressure 133/69mmHg, oxygen saturation of 99% on room air, and body mass index of 44.22. Abdominal examination was remarkable for tenderness to the epigastric region. Initial hematologic findings significant for WBC of $13.6 \times 10^3/\text{mCL}$, hemoglobin of 8.3 gm/dL, and platelet of $563 \times 10^3/\text{mCL}$. The blood chemistry also showed an elevated creatinine of 1.24mg/dL, lactic acid 3.7mmol/L, BUN of 40.6mg/dL, ALT of 280 IU/L and AST of 206IU/L. The troponin was negative, and INR was 2.8. EKG showed a third-degree heart block (Figure 1). Chest x-ray showed no acute pulmonary process. Urine toxicology showed presence of cocaine and benzodiazepines. CT scan of the abdomen and pelvis was suggestive of mild colitis but no evidence of ischemia. The patient was started on IV fluids, antibiotics including vancomycin and ceftriaxone for acute colitis, and morphine for pain. Because of worsening renal functions, hyperkalemia, and lactic acidosis with a lactic acid value of 20, CRRT was commenced. Patient was closely monitored on cardiac monitor, Cardiologist review was sought, and transvenous pacing was deferred as the patient was maintaining adequate blood pressure and MAP. However, she deteriorated and developed hypotension on day 3 of hospital stay, for which transvenous pacing and dopamine infusion were initiated with improvement in hemodynamic stability and end-organ perfusion. She underwent permanent pacemaker placement due to a persistent complete heart block. The patient received fentanyl for sedation, which complicated the postoperative period with CNS depression and respiratory failure requiring BIPAP. For opioid reversal, IV naloxone 0.4mg was administered with an observed conversion of heart rhythm to normal sinus rhythm. The rhythm strip shows the telemetry record at the time of naloxone administration (Figure 2). A repeat EKG showed normal sinus rhythm (Figure 3). Narcotics were discontinued. The patient improved and was discharged home in stable condition after

13 days of hospitalization. The patient showed up for follow-up during which a normal sinus rhythm requiring no pacemaker was seen on her EKG recordings.

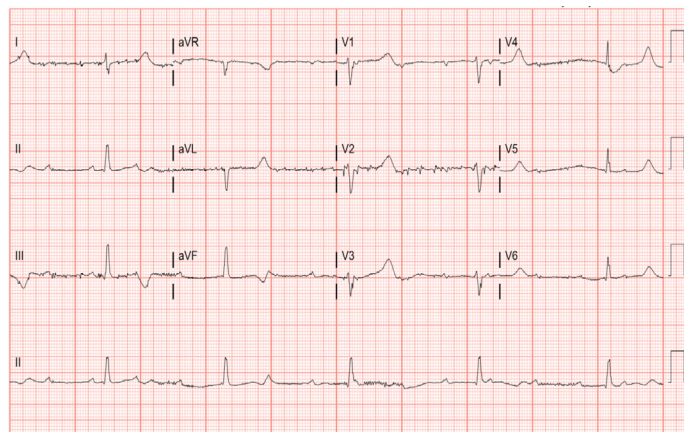


Figure 1: Third-degree heart block on EKG.

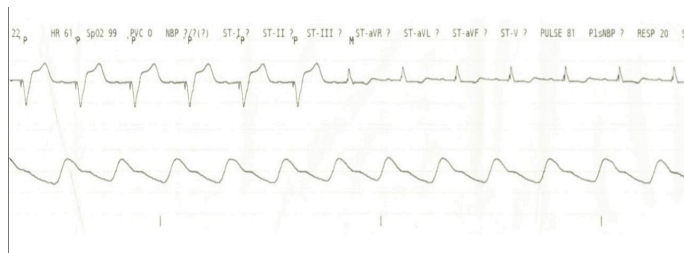


Figure 2: Telemetry record at time of naloxone administration.

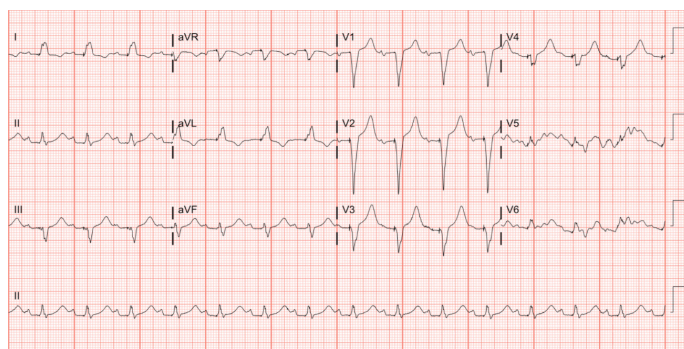


Figure 3: Normal sinus rhythm on EKG.

Discussion & conclusions

Cocaine is known mainly for its abuse potential, and its toxicity presents a wide array of clinical presentations. Cardiovascular sequelae are one of the several complications of cocaine toxicity. Cocaine stimulates the sympathetic nervous system by inhibiting catecholamine reuptake at the synapse, resulting in increased sympathetic output and catecholamines. This leads to increased heart rate, blood pressure, ventricular contraction, coronary vasoconstriction, and platelet adherence. Myocardial ischemia and infarction can result from decreased myocardial oxygen supply, and increased myocardial oxygen demand. Cocaine acts as class IA and 1C antiarrhythmic agent and local anesthetic by blocking the sodium channels leading to decreased left ventricular contraction, QRS prolongation, QT prolongation and arrhythmias [2]. Cocaine also blocks the potassium channel. The arrhythmia associated with cocaine ranges from tachyarrhythmia to bradyarrhythmia. Multiple cases of Atrio-

ventricular (AV) conduction blocks, including first-degree AV block, Mobitz type I, Mobitz type II, and third-degree AV blocks, have been reported with cocaine intoxication from inhibition of voltage-gated sodium channels [3]. Bradycardia has been associated with chronic cocaine use that may be related to cocaine-induced desensitization of beta-adrenergic receptors [4]. The blockage of the fast sodium current can also reduce sinus node automaticity and lead to bradycardia [4,5]. The blunting effect of Benzodiazepine on hyper sympathetic state makes it applicable to treat cocaine-induced tachyarrhythmia. The literature presents no clear guidelines for the management of cocaine-induced bradyarrhythmia. The treatment of symptomatic bradycardia includes atropine, chronotropic agents like dopamine, and pacemaker.

Naloxone is used for opioid intoxication with an unclear mechanism of action. However, it is thought to be a competitive antagonist at μ (mu)-opioid, δ (sigma)-opioid, and κ (kappa)-opioid receptors, hence its use for opioid intoxication. The administration of IV naloxone to the patients resulted in an immediate resolution of the complete heart block. This is the first reported case of cocaine-induced bradycardia that was treated with IV naloxone. Although the mechanism of action is unclear, an increase in heart rate, cardiac output, and arterial blood pressure in humans and animal studies due to increased epinephrine and norepinephrine plasma concentrations causing catecholamine surge, have been associated with naloxone administration [6]. The use of naloxone to treat cocaine-induced heart block may be a tenable option; however, further validity studies may be necessary.

Declaration

Ethics approval and consent to participate: Not applicable.

Consent for Publication: No written consent has been obtained from the patient, as there are no patient identifiable data included in this case.

Availability of data and materials: Not applicable.

Competing interests: The authors declare that they have no competing interests.

Authors Contributions: AI, OAA, SC, MA, TOA, OOE and PL met the ICMJE criteria for authorship. AI and OAA wrote the first draft of the article. SC, MYA, TOA, OOE and PWL critically reviewed and edited drafts. All authors read and approved the final manuscript.

References

1. Dykr CV, Byck R. Cocaine. *Scientific American*. 1982; 246: 128-141.
2. Schwartz BG, Rezkalla S, Kloner RA. Cardiovascular Effects of Cocaine. *Circulation*. 2010; 122: 2558-2569.
3. Kariyanna PT, Jayarangaiah A, Al-Sadawi M, Ahmed R, Green J, et al. A Rare Case of Second Degree Mobitz Type II AV Block Associated with Cocaine Use. *Am J Med Case Rep*. 2018; 6: 146-148.
4. Franklin SM, Thihalolipavan S, Fontaine JM. Sinus Bradycardia in Habitual Cocaine Users. *Am J Cardiol*. 2017; 119: 1611-1615.
5. Ouali S, Guerhazi O, Guerhazi F, Halima BM, Boudiche S, et al. Drug Abuse-Induced Cardiac Arrhythmias: Mechanisms and Management. *IntechOpen*, 2018.
6. Rzaso Lynn R, Galinkin JL. Naloxone dosage for opioid reversal: Current evidence and clinical implications. *Ther Adv Drug Saf*. 2018; 9: 63-88.