



Septal Angioplasty in Acute Coronary Syndrome (ACS) Patient: A Case Report of Revascularization of a Rarely Targeted Coronary Branch

Siddhartha Mani^{1*}; Arnab Banerjee²; Purushottam Kumar³; Ranabrata Sen¹

¹Cardiologist, NH-R.N. Tagore Hospital, Kolkata, India.

²Cardiologist, Blackpool Teaching Hospital, NHS Foundation Trust, UK.

³Cardiologist, Prashant Memorial Charitable Hospital, Bihar, India.

***Corresponding Author(s): Siddhartha Mani**

Cardiologist, NH-R.N. Tagore Hospital, Kolkata, India.

Email: siddhartha.mani83@gmail.com

Received: Aug 12, 2023

Accepted: Aug 29, 2023

Published Online: Aug 31, 2023

Journal: Journal of Case Reports and Medical Images

Publisher: MedDocs Publishers LLC

Online edition: <http://meddocsonline.org/>

Copyright: © Mani S (2023). *This Article is distributed under the terms of Creative Commons Attribution 4.0 International License*

Keywords: Septal angioplasty; Acute coronary syndrome, Drug-Eluting stent; Myocardial perfusion imaging; Left anterior descending artery.

Abstract

Background: Revascularization of the septal branch of the Left Anterior Descending artery is challenging due to its intramyocardial course. Percutaneous interventions, such as balloon angioplasty or stenting, are preferred in cases where traditional coronary artery bypass grafting is not feasible. However, limited literature exists on this rare intervention, especially in acute coronary syndrome patients.

Case Summary: We present a case report of a 65-year-old male with ischemic heart disease who underwent successful septal angioplasty using a drug-eluting stent. The patient had recurrent angina and a significant stenosis in the 1st septal perforator (S1) vessel. Myocardial perfusion imaging confirmed viable myocardium in territories supplied by the septal branch.

Results: Septal angioplasty led to a significant improvement in the patient's quality of life and a marginal increase in Left Ventricular Ejection Fraction from 32% to 38% during the 6-month follow-up. The patient showed reduced frequency and severity of angina episodes and improved exercise tolerance, as indicated by the increase in Metabolic Equivalent of Tasks achieved during a treadmill stress test.

Conclusion: Septal angioplasty in ACS patients with a significant septal branch supplying viable myocardium and conduction system can be a viable treatment option to improve LV function and quality of life. The positive outcomes observed in this case warrant consideration for septal angioplasty in similar patients with significant septal branch involvement.



Background

Revascularization of the septal branch of the Left Anterior Descending (LAD) artery is a rare and technically challenging procedure due to its intramyocardial course [1]. Traditional Coronary Artery Bypass Grafting (CABG) is often not feasible for this artery, and percutaneous revascularization using balloon angioplasty or stenting may present uncertainties in certain cases. However, in specific scenarios where the septal branch supplies a large portion of viable myocardium and the conduction system, septal revascularization can be considered as a fruitful intervention [2]. In this case report, we describe a patient who underwent successful septal angioplasty with a Drug-Eluting Stent (DES) after careful consideration and assessment of the myocardial territories at risk.

Case Presentation

A 65-year-old male with a history of Ischemic Heart Disease (IHD) presented with left-sided chest pain, worsening in intensity and duration over the last two days. The patient had undergone CABG in 2009, with grafts to the Left Internal Mammary Artery (LIMA) to Left Anterior Descending (LAD), Right Saphenous Vein Graft (R-SVG) to Posterior Descending Artery (PDA), and Posterior Left Ventricular (PLV). In 2014, a PTCA was performed for recurrent angina in the RCA [1]. Upon admission, the patient's Electrocardiogram (ECG) showed leftward axis and T-wave inversion in leads I and aVL. Echocardiogram revealed LV systolic dysfunction with an ejection fraction (EF) of 32% and Grade III diastolic dysfunction. The patient's Troponin I level was elevated at 4.022 ng/ml. A coronary angiogram revealed triple vessel disease with occluded grafts and a dilated 1st Septal perforator (S1) vessel with >90% ostial stenosis (Figure 1) [2].

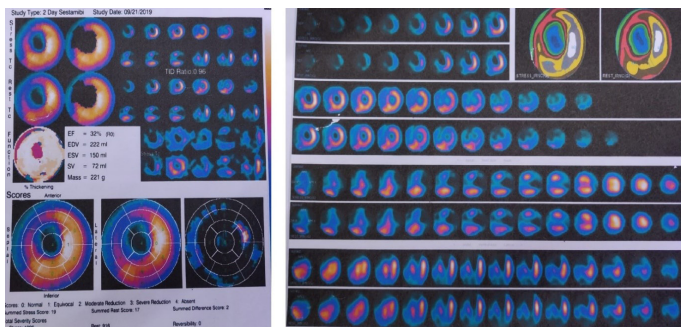


Figure 1: Myocardial Perfusion Imaging (SPECT) depicting an infarct involving the mid-distal anteroseptal and apical myocardial segments (Mid-Distal LAD territory) with no evidence of viable myocardium in the infarct zone. Viable myocardium is observed in the basal anteroseptal and anterolateral myocardial segments (Proximal LAD-Diagonal territories) as well as in the major part of the lateral and inferior myocardial segments (Left circumflex - RCA territories), plotted against the bull's eye plot (left panel). The right panel displays actual SPECT images during rest and pharmacological stress conditions.

Diagnosis

Based on the patient's clinical presentation, medical history, and angiographic findings, the diagnosis includes:

1. Recurrent angina in the context of Ischemic Heart Disease (IHD).
2. Triple vessel disease with occluded grafts from previous CABG.
3. A significant stenosis of the 1st septal perforator (S1) vessel.

Myocardial perfusion imaging was performed to assess the viability of the myocardium and revealed infarction in certain territories, as well as areas of viable myocardium in the basal anteroseptal and anterolateral myocardial segments. The large-caliber and potential for supplying a considerable portion of viable myocardium in the septum made the S1 vessel an essential target for revascularization.

Treatment

After careful consideration of the patient's clinical status, the need to preserve perfusion and viability of the basal septal wall to prevent further compromise in LV function was identified. Consequently, the decision was made to perform angioplasty on the S1 vessel with a drug-eluting stent (DES) to enhance the patient's cardiac function and quality of life.

The procedure involved pre-dilatation using a Maverick 1.5 X 15 mm Non-Compliant (NC) balloon, followed by stenting with a Promus Premier 2.25 X 16 mm DES (Figures 2 & 3). Post-dilatation was carried out using a 2.25 x 12 mm NC traveller balloon. The patient was discharged the following day with dual antiplatelet therapy with aspirin and ticagrelor, in addition to high dose rosuvastatin, ramipril, carvedilol, spironolactone and other supportive medications [3].

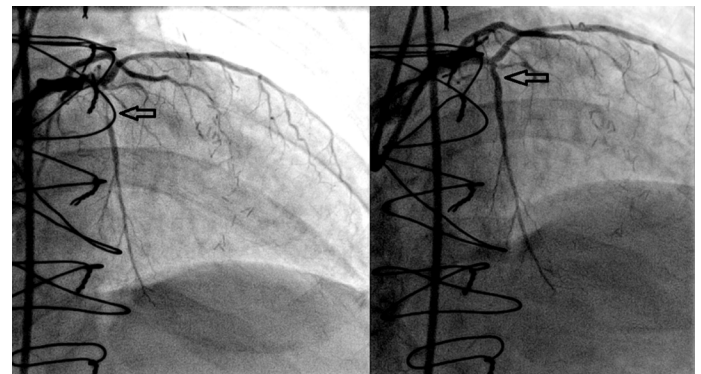


Figure 2: Right Anterior Oblique (RAO) view showing pre-angioplasty (left panel) and post angioplasty (right panel) angiographic images of the moderate calibre septal perforator vessel (S1). A tight >90% stenosis is seen at the ostium of the S1 in the pre-angioplasty image (Left Arrows).

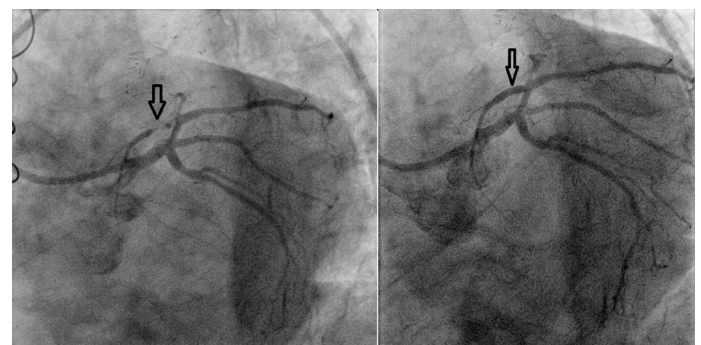


Figure 3: Left Anterior Oblique (LAO) caudal view showing pre-angioplasty (left panel) and post angioplasty (right panel) angiographic images of the moderate calibre septal perforator vessel (S1). A tight >90% stenosis is seen at the ostium of the S1 in the pre-angioplasty image (left arrows).

Follow-up and Outcome

During follow-up visits at one week and one month, the patient reported improvement in anginal symptoms. Six-month follow-up revealed a marginal increase in LVEF from 32% to 38% in the echocardiogram, and the patient's overall quality of life

had significantly improved.

Discussion

Septal angioplasty in Acute Coronary Syndrome (ACS) patients is a rare and challenging procedure due to the unique anatomy and functional significance of the septal branch of the Left Anterior Descending (LAD) artery. In this case report, we presented a successful septal angioplasty in a post-CABG, post-PTCA patient with recurrent angina and a significant occlusion in the 1st septal perforator (S1) vessel.

The septal branch of the LAD artery plays a crucial role in supplying blood to the conduction system, including the atrioventricular node (AVN) and the Bundle of His, in more than 50% of patients [1]. Additionally, the septal branch frequently acts as a significant source of collateral blood supply to the LAD, Right Coronary Artery (RCA), and Left Circumflex (LCX) artery territories in cases of total or sub-total occlusion of major epicardial arteries [2]. In the present case, the large-caliber S1 vessel with a potential to supply a considerable portion of viable myocardium, including the septum, posterior wall, AVN, and Bundle of His, made it a clinically important branch deserving intervention.

Conventional surgical revascularization such as Coronary Artery Bypass Grafting (CABG) is often not feasible for the septal branch due to its intramyocardial course [1]. Therefore, percutaneous revascularization using Plain Old Balloon Angioplasty (POBA), Percutaneous Transluminal Coronary Angioplasty (PTCA), or stenting becomes the preferred approach in eligible cases. However, revascularization by balloon angioplasty alone can lead to elastic recoil, resulting in frequent re-occlusion of the septal artery, and may not provide optimal long-term outcomes [4,5].

The choice of drug-eluting stent (DES) in our case was justified by its proven efficacy in reducing restenosis rates compared to bare-metal stents, especially in small vessels [4,5]. Stenting with a DES provides better support, less recoil, and improved radial strength, which is particularly important for the small-caliber septal artery [2]. Moreover, DES implantation minimizes the risk of re-stenosis, reducing the likelihood of repeat interventions and improving long-term results [1].

The successful septal angioplasty in our case led to a significant improvement in the patient's quality of life and a marginal increase in Left Ventricular Ejection Fraction (LVEF) from 32% to 38%. The decision to target the S1 vessel for revascularization was supported by the presence of viable myocardium in territories supplied by the septal branch and the potential to prevent further deterioration in LV function or even improve EF in certain cases. This concept is based on the phenomenon of hibernating myocardium, where regions of the myocardium with reduced contractility can recover function after adequate revascularization [2].

It is essential to emphasize that septal angioplasty is not recommended as a routine intervention in the septal branch of the LAD artery. Instead, it should be considered in carefully selected patients with viable myocardium at risk and limited options for revascularization [1]. Careful evaluation of the region at risk and presence of viable myocardium using techniques like myocardial perfusion imaging is crucial to identify appropriate candidates for this intervention.

This case report covers an uncommon clinical scenario of septal angioplasty in an Acute Coronary Syndrome (ACS) patient, which limits the number of references in the discussion. The lack of research on this topic is due to the rarity of such situations and the difficulties of performing large-scale investigations on this intervention. Future research on septal angioplasty, could bring insight, its potential benefits and drawbacks in treating ACS patients with extensive septal branch involvement.

Limitations: The case report's primary limitation is the relatively short follow-up duration of six months.

Conclusion

Septal angioplasty in ACS patients with a large-caliber septal branch supplying viable myocardium and conduction system can be a viable treatment option to improve LV function and quality of life. The use of a drug-eluting stent (DES) offers technical advantages and may improve long-term outcomes in carefully selected patients. However, septal angioplasty should be performed judiciously and only in patients with a specific set of criteria to achieve optimal results. Further research and larger studies are warranted to validate the efficacy and safety of this intervention in specific subsets of ACS patients.

References

1. Vemuri R, Kantipudi S, Thachathodiyl R, et al. Percutaneous coronary intervention for isolated first septal artery stenosis presenting as myocardial infarction: A case report. *J Clin Diagn Res.* 2016; 10: OD14-5.
2. Topaz O, DeMarchena EJ, Vora K, et al. Anomalous septal artery: an unusual cause of myocardial infarction treated with intracoronary stent implantation. *Cathet Cardiovasc Diagn.* 1997;40(4):398-401.
3. Saidi AS, Duran C, Himbert D, et al. Primary stent implantation for acute myocardial infarction in a coronary artery originating from the right. *Eur Heart J.* 2004; 25: 1213-8.
4. Windecker S, Kolh P, Alfonso F, et al. 2014 ESC/EACTS Guidelines on myocardial revascularization: The Task Force on Myocardial Revascularization of the European Society of Cardiology (ESC) and the European Association for Cardio-Thoracic Surgery (EACTS). Developed with the special contribution of the European Association of Percutaneous Cardiovascular Interventions (EAPCI). *Eur Heart J.* 2014; 35: 2541-619.
5. Alfonso F, Byrne RA, Rivero F, Kastrati A. Current treatment of in-stent restenosis. *J Am Coll Cardiol.* 2014; 63: 2659-2673.