



# Radiographic Signs of Trauma from Occlusion at the Level of the Periodontal Ligament and Articulation Structures

**Ilma Robo<sup>1\*</sup>; Saimir Heta<sup>2</sup>**

<sup>1</sup>Albanian University, Department of Dentistry, Pedagogue of Clinic Periodontology, Tirana, Albania

<sup>2</sup>Pediatric Surgeon, Pediatric Surgery Service, QSUT, Tirana, Albania

**\*Corresponding Author(s): Ilma Robo**

Albanian University, Department of Dentistry,  
Pedagogue of Clinic Periodontology, Tirana,  
Albania  
Email: [ilmarobo@yahoo.com](mailto:ilmarobo@yahoo.com)

**Abstract**

The periodontal ligament faces even greater occlusal forces within a limit, presenting with trauma changes from occlusion locally to the tooth where it operates. Subsequently, the whole pathology is followed at the level of articulation, to present there the distinct radiographic signs of occlusion trauma. The study relied on radiographic evaluation of occlusion trauma on 100 randomly selected panoramax graphs, 2010-2019 time period. The graphs were grouped according to the number of teeth in the oral cavity and the presence or absence of occlusion. 24% are the group of patients with less than 20 teeth in the oral cavity with or without occlusion. 76% are patients with a minimum of 20 teeth in the oral cavity, but with occlusion due to prosthetic or implant replacements. The criterion of bone trabeculae parallelization is the one most commonly encountered in the value of 25%, followed by the local thickening of the periodontal ligament in the value of 21%. Equivalent positioning criterion of articular head in relation to articular fossa is found in value of 4%, equally in value with articular head positioning criterion related to articular eminence, followed by unequal intercuspidal distance to the same patient, side left, compared to the right side, at 5%. Pathology in articulation appears at 25%, patients without articulation problems estimated by panoramic radiography is at 75% ( $p$  value  $\leq 0.0237$ ).

**Conclusions:** Occlusion trauma from the level of dental structures extends its action to the level of temporomandibular articulation structures. The dentist is one of the causes of this pathology, failing to restore occlusion to the patient with missing teeth in the oral cavity.

Received: Apr 30, 2020

Accepted: Jun 26, 2020

Published Online: Jun 30, 2020

Journal: Journal of Case Reports and Medical Images

Publisher: MedDocs Publishers LLC

Online edition: <http://meddocsonline.org/>

Copyright: © Robo I (2020). *This Article is distributed under the terms of Creative Commons Attribution 4.0 International License*

**Keywords:** Trauma; Pathology; oral cavity; prosthetic



## Introduction

Occlusion trauma is described as damage to the constituent structures of the periodontal, preceded by the application of an occlusal force that exceeds the damaging capacity of the periodontal ligament [1]. Occlusion trauma may not have the same clinical signs as gingival inflammation, as the bacteria are not responsible for its cause. Consequently, there is no attempt to find clinical signs of pocket presence or loss of attachment, similarly for both clinical cases [2]. From 1901 to 1960, there has been a stabilization of theoretical-practical ideas regarding the exact definition and expression of what we call occlusion trauma, clinically and radiographically, as distinguished [2].

The forces exerted on the teeth have the direction, size, frequency, regularity applied to the occlusal surface of the tooth, and consequently the reflection of these forces on the root surfaces [3]. Divergence, convergence of tooth roots also pre-determines the size of the bony area where these forces from occlusal trauma exert a significant oppressive effect according to or in opposition to the longitudinal axis of the tooth.

The suppression of periodontal structures is associated with the compression of the arteries, resulting in the lack of oxygen and glucose that these vessels mechanically transport through the blood to the relevant periodontal tissues [4]. This is where the first stage of occlusion trauma begins, which is the injury. Bone resorption is the primary sign of injury that is subsequently followed by the tooth remodeling or adaptation phase to new conditions, under the effect of forces applied to the tooth. Often this stage is observed in teeth with healthy periodontal structure [4,5]. Remodeling is typical of the hinged pattern of periodontal ligament structures, where discrepancies in the thickness of the periodontal ligament space and uneven magnification of this space around the same tooth [5].

Radiographic signs of occlusion trauma are evident at the level of the lamina, the density of the alveolar bone, the width of the alveolar ridge, and the morphology of the alveolar ridge. The increased clinical mobility of the tooth as a result of occlusion trauma expresses the most noticeable radiographic effect on the intra-proximal surfaces.

The physiological sensitivity of the teeth is higher in the mesio-distal direction than the vestibulo-labial. If this phenomenon passes into pathological aggravation due to occlusion trauma, radiographic signs of the latter appear on the interproximal surfaces as vertical bone loss. The phase of trauma from occlusion causes loss of the dorsal lamina at both apex and bifurcation [6,7].

## Materials and Methods

The study was conducted on radiographic evaluation of occlusion trauma on 100 randomly selected panoramas, time period from 2010-2019.

The 100 radiographs were divided into 6 groups according to the following criteria:

**Group 1:** The presence of all teeth in the oral cavity

No presence of fixed-implant prosthetic replacements (full number of teeth in mouth).

**Group 2:** Presence of all teeth in oral cavity - extractions of upto 5 teeth Presence of implants with fixed prosthetics - implant (complete number of teeth in mouth).

**Group 3:** Extracted teeth within the range of 6-12 teeth.

Presence of occlusion in at least 2 sets of teeth, triple contact of the teeth.

**Group 4:** Maximum 20 teeth in oral cavity.

Presence of occlusion in at least 2 sets of teeth, triple contact of the teeth.

**Group 5:** Maximum 20 teeth in oral cavity.

Absence of occlusion.

**Group 6:** Less than 20 teeth in oral cavity.

Absence or not of occlusion.

Radiographic signs of occlusion trauma evaluated in this study (criterion 1) were:

- Parallelization of the bony trabeculae at the level of the alveolar ridges,
- Periodontal ligament of different widths along the surface of the tooth roots,
- Thickening of the periodontal ligament.

The other categorization of radiographs was performed on basis of analyzing the positioning of the constituent structures of the temporomandibular articulation. At this point radiographs were categorized (criterion 2):

- The same positioning of the articular heads versus the articular fossa
- The same positioning of the articular heads versus the articular eminence
- The same intercuspidal distance on radiographs.

Data were processed to find the mean and p-value for possible association between radiographic signs of occlusion trauma at the level of dental structures and at the level of articulation.

## Results

The data collected from this study are summarized in the tables below.

**Table 1:** This table presents clinical cases with radiographs classified in 6 groups according to the relevant criteria.

	Group 1	%	Group 2	%	Group 3	%	Total
No. graph	10	10%	38	38%	28	28%	76%
	Group 4		Group 5		Group 6		
No. graph	12	12%	8	8%	4	4%	24%
Total	22	22%	46	46%	32	32%	100%

**Table 2:** Data on the first 3 groups of radiographs divided by clinical signs of occlusion trauma.

Criteria	Group 1	%	Group 2	%	Group 3	%	Total
Parallelization of the trabeculae	5	5%	13	13%	7	7%	25%
Width of # of ligament	0	0%	3	3%	4	4%	7%
Thickness of the ligament	2	2%	10	10%	9	9%	21%
No change	3	3%	12	12%	8	8%	23%
Total	10	10%	38	38%	28	28%	76%

**Table 3:** Data on the second 2 groups of radiographs divided by clinical signs of occlusion trauma.

Criteria	Group 4	%	Group 5	%	Group 6	%	Total
Parallelization of the trabeculae	2	2%	0	0%	0	0%	2%
Width of # of ligament	3	3%	1	1%	0	0%	4%
Thickness of the ligament	3	3%	4	4%	1	1%	8%
No change	4	4%	3	3%	3	4%	11%
Total	12	12%	8	8%	4	4%	24%

**Table 4:** Data on the first 3 groups of radiographs divided by articular head position versus fossa and eminence.

Criteria	Group 1		%	Group 2		%	Group 3		%
	po	jo		po	jo		po	jo	
Position with the fossa	7	3	3%	35	3	3%	24	4	4%
Position with eminence	7	3	3%	34	4	4%	24	4	4%
Intercuspidal distance	8	2	2%	33	5	5%	22	6	6%
Total	10		8%	38		12%	28		14%

**Table 5:** Data on the second 3 groups of radiographs divided by articular head position versus fossa and eminence.

Criteria	Group 4		%	Group 5		%	Group 6		%
	po	jo		po	jo		po	jo	
Position with the fossa	10	2	12%	6	2	8%	3	1	4%
Position with eminence	9	3	12%	7	1	8%	3	1	4%
Intercuspidal distance	12	0	12%	6	3	8%	3	1	4%
Total	12		12%	8		8%	4		4%

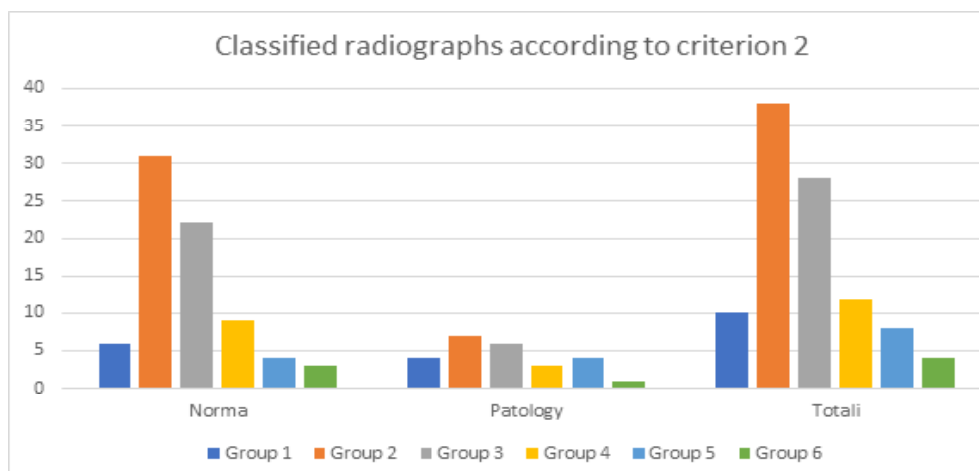
**Table 6:** Data on the positioning of the articular head versus other articulation structures, respectively, by subgroup with groups.

No. Graph	Group 1	Group 2	Group 3	Group 4	Group 5	Group 6	Total	%
Normal	6	31	22	9	4	3	75	75%
Patology	4	7	6	3	4	1	25	25%
Total	10	38	28	12	8	4	100	100%

The data in Table 6 are presented in Chart 1.

**Table 7:** Relationship to occlusion trauma pathology, classified by criterion 1 and criterion 2.

Criteria 1/2	Normë	%	Traumë	%	Totali	p
Norma	36	36%	27	27%	63	Vlera p ≤ 0.0237
Trauma from occlusion	39	39%	25	25%	64	
Total	51	65%	52	52%		

**Figure 1:** Number of radiographs classified according to criterion 2, presented in table 6.

P value ≤ 0.0237 is considered statistically significant. Confidence interval: the mean of the first group minus the second group is 11.50. 95% confidence interval of this difference: from 3.74 to 19.26. Values used for calculations:  $t = 6.3791$ ,  $df = 2$ ; Difference standard error = 1.803.

Summary of processed data:

**Group 1:** mean 37.50, SD 2.12, SEM 1.50

**Group 2:** mean 26.00, SD 1.41; SEM 1.00.

### Discussion

The three stages of trauma from occlusion have visible and recordable clinical and radiographic signs. Tissue injury is a consequence of exceeding the adaptive capacity of the periodontal ligament to the applied occlusal forces. The repair of damage caused by trauma from occlusion is in nature of periodontal structures. If the forces are chronic, the apparent damage to the occlusal trauma-affected tooth is significantly shifted to the articulation structures. If at periodontal tissues, occlusal trauma injuries are expressed at the level of scaling of the bone trabeculae, at the level of expansion of the periodontal ligament, at articular structures it is seen that these radiographic signs in the context of positioning the articular head versus articular eminence, the articulation fossa and the balance between the maxillary and mandibular occlusal plane.

In the ad-hoc panoramexgraph group, 24% is the group of patients with less than 20 teeth in the oral cavity with or without occlusion. 76% are patients with a minimum of 20 teeth in the oral cavity, but with occlusion due to prosthetic or implant replacements. Group 2 included majority of patients with 38% presence of all teeth in the oral cavity - extractions of up to 5 teeth and presence of fixed-implant prosthetic replacements (complete number of teeth in mouth), followed by group 3 where patients have at least 20 teeth but with triple contact of between the teeth.

Speaking of data on occlusion trauma on radiographs, the first 3 groups, the criterion of bone trabecularisation is the most commonly encountered in 25%, followed by local thickening of the periodontal ligament in 21%.

Speaking of data on occlusal trauma screening on radiographs, the second 2 groups, the criterion of bone trabeculae parallelization is at the lowest value of 2% and the highest value at the thickness of the periodontal ligament at the value of 8%.

If the data on occlusion trauma radiographs are processed, at the level of articulation, the first 3 groups, the criterion of equal positioning of the articular heads in relation to the articular fossa, is found to be 4%, equal to the criterion of articulation. Articular head positioning related to articular eminence, followed by unequal intercuspidal distance to the same patient on the left side compared to the right side at 5%. Expressed in values for all groups, pathology in articulation appears at 25%, patients with no articulation problems estimated by panoramic radiography at 75%. The  $p \leq 0.0237$  value for the evaluation of occlusal trauma pathology on the basis of criterion 1 at the level of periodontal structures and criterion 2 at the level of articulation structures indicates a significant correlation between these 2 areas in the manifestation of this pathology.

### Conclusions

Fix prosthetic and implant replacements, based on data on the number of patients of the study, show an increase application of the respective protocols. This fact is supported by the large number of patients with significant numbers of teeth in the oral cavity.

These replacements or even therapeutic dental treatments increase the chance of occlusion trauma, based on the data of this study is not in significant numbers, but as a phenomenon stands. Occlusion trauma from the level of the dental structures extends its action to the level of temporomandibular articulation structures.

---

**References**

1. Jin LJ, Cao CF. "Clinical diagnosis of trauma from occlusion and its relation with severity of periodontitis"; J Clin Periodontol. 1992; 19: 92-97.
2. Jingyuan FanJack G. Caton. " Occlusal trauma and excessive occlusal forces: Narrative review, case definitions, and diagnostic considerations";Journal of Periodontology and Journal of Clinical Periodontology.
3. Singh DK, Jalaluddin M, Rajeev R. Trauma from occlusion: The overstrain of the supporting structures of the teeth. Indian J Dent Sci. 2017; 9: 126-132.
4. Michael GN, DDS, Henry HT, DDS, Fermin AC, et al,. "Clinical Periodontology; Ninth edition". 2004 Mosby.
5. Diagnoza Orale, pjesa e parë, Steveen LB, Robert PL, Craig SM, et al,. "Çrregullimetgingivaledheperiodontale".
6. Kundapur PP, Bhat KM, Bhat GS; "Association of trauma from occlusion with localized gingival recession in mandibular anterior teeth"; Dental Research Journal, 01 Jan. 2009; 6: 71-74.
7. Pihlstrom BL, Anderson KA, Aeppli D, Schaffer EM; "Association between signs of trauma from occlusion and periodontitis";J Periodontol. 1986; 57: 1-6.