



Porcelain Gallbladder or A Special Type Stone? A Case Report and Literature Review

Linlin Qu^{1*}; Jinyu Pei^{1,2}; Peng Liu^{1,2}; Guanghua Cao^{1,2}; Dongxia Yang¹; Cong Wang¹; Dongdong Dai¹; Jingyu Cao¹

¹Department of Hepatopancreatobiliary Surgery, The Affiliated Hospital of Qingdao University, Huangdao District, Qingdao, 266555, Shandong Province, China.

²Medical College of Qingdao University, No.308 Ningxia Road, Qingdao, 266071, Shandong Province, China.

*Corresponding Author: Linlin Qu

Department of Hepatopancreatobiliary Surgery, The Affiliated Hospital of Qingdao University, Huangdao District, Qingdao, 266555, Shandong Province, China.
Tel: +86-532-82919551, Fax: +86-532-82919551
Email: taxue9455@sina.com & pjy19950113@163.com

Abstract

We reported a 60-year-old patient with porcelain gallbladder was performed abdominal CT scan which showed the calcification of gallbladder wall disappeared. The specimens showed the gallbladder mucosa was attached to white jelly-like substances which were not calcified. In our opinion, the white jelly-like substance may be a special manifestation of stones.

Received: Aug 16, 2020

Accepted: Sep 21, 2020

Published Online: Sep 23, 2020

Journal: Journal of Case Reports and Medical Images

Publisher: MedDocs Publishers LLC

Online edition: <http://meddocsonline.org/>

Copyright: © Qu L (2020). *This Article is distributed under the terms of Creative Commons Attribution 4.0 International License*

Keywords: Porcelain gallbladder; Gallbladder stone; Calcified gallbladder wall; Cholecystitis.

Introduction

Porcelain gallbladder refers to a condition where the gallbladder wall becomes hard and fragile due to calcification and appears pale blue. The concept of "ceramic gallbladder" was first proposed by Cornell in 1959 [1]. As the global incidence of the disease is very low (0.06% to 0.8%) [2,3], more cases should be reported for improved understanding of the clinical features of the disease. Here, we describe a unique case of suspected porcelain gallbladder in our hospital.

Case presentation

A 60-year-old patient was hospitalized with a 2-month history of abdominal pain in the right upper quadrant. The pain was triggered by high fat diets. The patient had no signs of jaundice, nausea, vomiting, or fever and was physically healthy. The patient had no medical history of malignancy. A physical examination revealed tenderness in the right upper quadrant and swollen gallbladder under the right ribs margin. Tenderness in the lower back was not observed. One month prior to the operation (Oct 16, 2018), abdominal CT scan images showed that the vol-

Cite this article: Qu L, Pei J, Liu P, Cao G, Yang D, et al. Porcelain Gallbladder or A Special Type Stone? A Case Report and Literature Review. *J Case Rep Med Images*. 2020; 3(1): 1055.



ume of the gallbladder was reduced, and the wall of the gallbladder had thickened and calcified (Figure 1). The images also showed the presence of a circular calcareous region and a gallbladder stone of 1.46 cm diameter in the neck of the gallbladder (Figure 1). However, 2 days before the operation (Nov 23, 2018), another abdominal CT scan showed that the gallbladder wall was no longer calcified (Figure 1), and there was a bigger gallstone in the neck of the gallbladder (diameter 1.63 cm) (Figure 1). The conditions were diagnosed as porcelain gallbladder with gallstone. As the patient experienced frequent episodes of abdominal pain, laparoscopic cholecystectomy was performed. During the operation, the surgeon found that the gallbladder wall was hard and severely adhered to the surrounding tissues. In view of this situation, the patient's gallbladder was completely removed after gradual separation of the gallbladder wall from the surrounding adhesions. Examination of the resected gallbladder revealed that the gallbladder wall had thickened; the texture of the wall was soft, and the wall was attached to a sticky milky jelly-like substance, similar to plaster (Figure 2). The jelly-like substance was located in the gallbladder cavity, separated from the gallbladder wall by a clear boundary. A spherical stone was observed in the neck of the gallbladder (Figure 5). Pathological examination after the operation showed that the gallbladder mucosa was rough and attached to white jelly-like substances. No cancerous growth was observed.

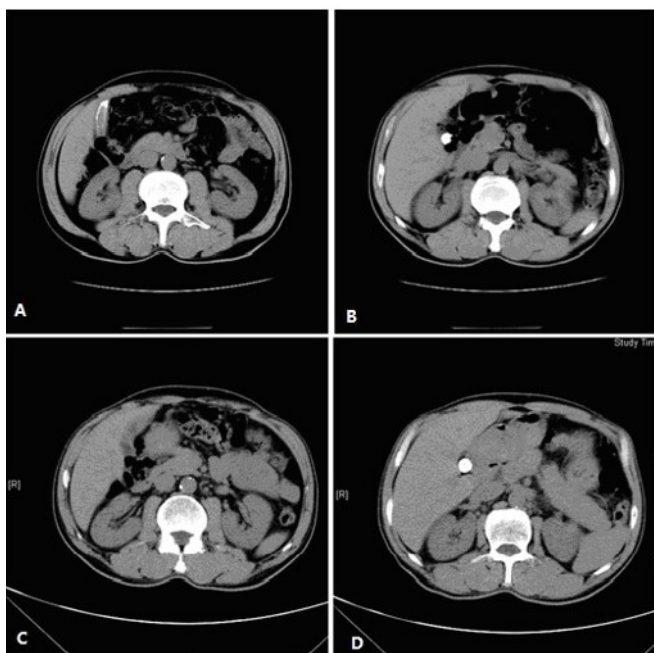


Figure 1: The CT scan of upper abdomen. A. the wall of gallbladder was thickened and calcified. B. the diameter of gallbladder stone was 1.46 cm. C. the calcified wall of gallbladder was disappeared. D. the diameter of gallbladder stone was 1.63 cm.

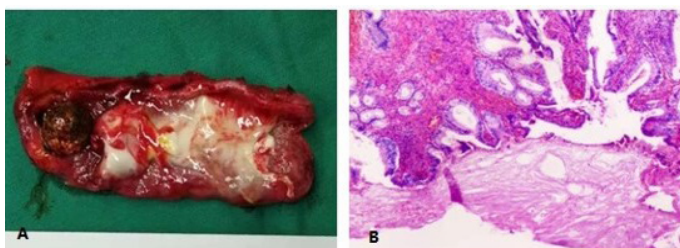


Figure 2: The gross specimen of gallbladder after operation. It was attached with sticky milky jelly-like substance. B. the gallbladder mucosa was rough and attaches to white jelly-like substances.

Discussion

Porcelain gallbladder is characterized by the presence of a hard and fragile gallbladder wall that appears pale blue. The condition develops due to pathological changes of the cyst wall caused by recurring inflammation and calcium deposition. In 90% of the cases, porcelain gallbladders are associated with gallstones. The pathogenesis of the gallbladder calcification is still unclear, and it is thought to develop as a result of obstruction of the cystic duct, leading to precipitation of calcium salts in the mucosa, or due to chronic inflammation resulting in hemorrhage, scarring, and hyalinization of the gallbladder wall causing deposition of calcium salts. In the current case, the transformation of the gallbladder wall observed from the two abdominal CT scans indicates that this phenomenon is distinguished from the porcelain gallbladder and needs further study. The gallstones can be divided into two major categories: cholesterol stones and bile pigment stones. From the global perspective, 70 to 80% of gallstones are generally cholesterol stones [4]. The main components of gallstones are cholesterol, bile pigment, a small proportion of calcium salts, as well as mucin glycoproteins. Alterations in bile composition, impaired gallbladder relaxation, and accelerated nucleation are the principal mechanisms leading to gallstones formation. Traditionally, the formation of gallstones is believed to happen due to excessive secretion of cholesterol in the bile or due to the presence of too little micelles caused by insufficient secretion of bile salts. As the amount of lecithin is not enough to dissolve the excessive cholesterol, the supersaturated bile forms and cholesterol crystals precipitate to form cholesterol stones [5]. In the current study, we postulate that the porcelain white jelly-like substance that remained attached to the gallbladder mucosa may be the pre-existing forms of solid stones (semi-solid stones). The semi-solid stones could have formed due to the absorption and secretion of the gallbladder mucosa. Absorption of the gallbladder mucosa can significantly increase the concentration of lipids, calcium, and glycoproteins in the gallbladder. Gallbladder mucosa can also secrete mucus, which is made up of mucin and glycoproteins, which promote the formation of gallstones. Cystic duct obstruction promotes calcium carbonate formation in the bile and increases gallbladder mucin production [6]. Cholestasis and increased absorption of gallbladder may promote formation of gallstones. Gallbladder absorption increases the concentration of pro-lithogenic factors in the bile and facilitates nucleation and stone growth [7]. In the current case, an abdominal CT scan performed a month before the surgery showed increased density of gallbladder wall, but a second CT scan performed 2 days prior to the surgery revealed no calcification in the gallbladder wall. However, in the second CT scan, the gallstone in the neck of the gallbladder was found to be larger than before (diameter of the gallstone changed from 1.46 to 1.63 cm). The components attached to the gallbladder mucosa may have converted into stones, making the stone larger than before. Review of the medical literature showed no related case reports and theoretical support that can explain the current clinical observations. The cause and mechanism of the formation of semi-solid stones are still unknown. To improve our understanding of the clinical characteristics of porcelain gallbladder and achieve better treatment outcomes, further studies are required that can help in deciphering the mechanism of formation of the porcelain gallbladder and semi-solid stones in the gallbladder.

Acknowledgement

This work was supported by the National Basic Research Program (973 Program) in China (No. 2007CB513005 and 2009CB522405), Shangdong Province Young and Middle-Aged Scientists Research Awards Fund (BS2011YY004) and the Gut Barrier Foundation of Li Jieshou Academician.

References

1. Cornell CM, Clarke R. Vicarious calcification involving the gallbladder. *Annals of surgery* 1959; 149: 267-272.
2. Opatrny L. Porcelain gallbladder. *Canadian Medical Association journal* 2002; 166: 933.
3. Shivanna Puttasubbappa P, Pallavi P. Porcelain Gallbladder Mimicking Carcinoma Gallbladder-a Case Report and Review of Literature. *The Indian journal of surgery* 2013; 75: 208-209.
4. Volzke H, Baumeister SE, Alte D, Hoffmann W, Schwahn C, et al. Independent risk factors for gallstone formation in a region with high cholelithiasis prevalence. *Digestion* 2005; 71: 97-105.
5. Grebe A and Latz E. Cholesterol crystals and inflammation. *Current rheumatology reports* 2013; 15: 313.
6. Sayers C, Wyatt J, Soloway RD, Taylor DR, Stringer MD. Gallbladder mucin production and calcium carbonate gallstones in children. *Pediatric surgery international* 2007; 23: 219-223.
7. Moser AJ, Abedin MZ, Giurgiu DI, Roslyn JJ. Octreotide promotes gallbladder absorption in prairie dogs: a potential cause of gallstones. *Gastroenterology* 1995; 108: 1547-1555.