



Paracetamol-induced hyperbilirubinemia in a Gilbert's patient

Fani Ribeiro*; Marcelo Aveiro; Mariana Leal; Tiago Valente; Gorete Jesus

Internal Medicine Resident, Internal Medicine Department-Centro Hospitalar do Baixo Vouga, Aveiro, Portugal

*Corresponding Author(s): Fani Ribeiro

Internal Medicine Resident, Internal Medicine
Department-Centro Hospitalar do Baixo Vouga,
Aveiro, Portugal
Tel: +351-234-3783-00
Email: fanisusana87@gmail.com

Abstract

The genetic mutation identified in Gilbert syndrome has pharmacological implications and may increase the susceptibility toward some drugs, such as paracetamol. The authors present a case of Gilbert syndrome with an atypical analytical response-high isolated unconjugated hyperbilirubinemia-due to intentional overdosing.

Received: Aug 26, 2019

Accepted: Oct 25, 2019

Published Online: Nov 01, 2019

Journal: Journal of Case Reports and Medical Images

Publisher: MedDocs Publishers LLC

Online edition: <http://meddocsonline.org/>

Copyright: © Ribeiro F (2019). *This Article is distributed under the terms of Creative Commons Attribution 4.0 International License*

Keywords: Gilbert's syndrome; Paracetamol hepatotoxicity; Unconjugated hyperbilirubinemia

Introduction

Paracetamol (Acetaminophen) is widely used as an antipyretic and analgesic. Despite being safe in therapeutic doses, in high-risk populations or in excessive amounts it may cause hepatotoxicity. Patients with Gilbert's syndrome may be more susceptible to the toxic effect of paracetamol, a substance that requires bilirubin-UGT-mediated hepatic glucuronidation prior to excretion. It is known that in patients hyperbilirubinemia may raise under certain or physiologic conditions but usually remains under 6mg/dL [1]. The objective of this article is to report a case of atypical high-unconjugated hyperbilirubinemia following paracetamol intake that was diagnosed with Gilbert's syndrome.

Case report

A 20-year old African-Brazilian male, without relevant past medical history, was admitted in the emergency department 1.5 hours after voluntary ingestion of 8 to 12 grams of paracetamol. He was asymptomatic, hemodynamically stable and physical examination was unremarkable. Gastric lavage, decontamination with activated charcoal and 21-hour protocol of N-acetylcysteine (NAC) were performed. His initial liver function tests revealed total bilirubin to be 2.8mg/dL with the unconjugated fraction as 1.9mg/dL; International Normalized Ratio was 1.2; No other alterations. On the second day he developed scleral icterus and total bilirubin levels due to unconjugated fraction significantly increased, with maximal rise 72 hours af-



Cite this article: Ribeiro F, Aveiro M, Leal M, Valente T, Jesus G. Paracetamol-induced hyperbilirubinemia in a gilbert's patient. J Case Rep Clin Images. 2019; 2(1): 1024.

ter (14.5 mg/dL and 14.1 mg/dL, respectively); There were no other changes in the liver enzyme levels nor coagulopathy or hypoalbuminemia (Graphic 1). Haemolysis was excluded, acute and chronic hepatitis virus tests were negative and antibodies for autoimmune disease and abdominal ultrasonography were normal. On day 4 bilirubins were in descending profile and the patient was discharged. His follow-up was uneventful. Given the finding of isolated unconjugated hyperbilirubinemia it was hypothesized that the patient had a Gilbert Syndrome aggravated by the ingestion of paracetamol. The genetic study confirmed a homozygous mutation (insertion) in the promoter region of the UDP-glucuronosyltransferase gene (UGT1A1), represented as A(TA)₇TAA

Discussion

Gilbert's syndrome is a benign inherited disorder of bilirubin glucuronidation that affects between 5 and 10% of Western Europeans. Other than jaundice, patients are typically asymptomatic due to mild chronic unconjugated hyperbilirubinemia and the diagnosis is often made after its incidental on routine liver biochemistry testing. [2] This hyperbilirubinemia is caused by the deficiency of the Bilirubin-uridine diphosphate-glucuronosyltransferase (Bilirubin-UGT) enzyme due to a genetic defect in the promoter region UGT1A1. Bilirubin-UGT conjugates bilirubin to glucuronic acid, converting bilirubin into a water-soluble form excretable in bile. [3] Its insufficiency results in a 60-70% reduction of bilirubin conjugation in the liver, increasing serum concentrations of unconjugated bilirubin [2].

Paracetamol requires bilirubin-UGT mediated hepatic glucuronidation and about 55% is excreted as the glucuronide. When this glucuronidation pathway becomes saturated, as in overdosing, more paracetamol is metabolized by cytochrome P-450, producing oxidative products (N-acetyl-p-benzoquinone imine-NAPQI) that mediate the hepatotoxic effect of the drug, causing centrilobular necrosis [4]. Despite there is no clear evidence suggesting increased risk of paracetamol toxicity in Gilbert's, patients may potentially be more susceptible to its toxicity because of their deficiency in glucuronidation [5, 6].

The hallmark of paracetamol-induced hepatitis is markedly elevation of plasma aminotransferases that can exceed 10 000 IU/L, evident from 24 to 72 hours after ingestion and that peak from 72 to 96 hours [7]. However, except for the temporal evolution, this biochemical feature was not consistent with this patient's laboratory results that presented high levels of isolate unconjugated hyperbilirubinemia. In this patient clinical history there was no other trigger of icterus than paracetamol identified. It is well established that factors such as dehydration, fasting, exercise, acute alcohol intake and acute illness may be causes of exacerbation, which were excluded [1] There were no other abnormal physical findings. Laboratory and imaging studies ruled out other causes of isolated hyperbilirubinemia, such as hemolysis or coexisting liver or biliary disease, as shown previously. The patient received treatment with NAC, which is associated with increase survival among patients with acute liver failure due to paracetamol poisoning. Despite preventing liver injury, the analytical response seems unrelated to this treatment and even an adverse reaction to NAC, which more commonly include anaphylaxis and vomiting, is unlikely [8].

Serum bilirubin levels in Gilbert's syndrome are usually less than 3mg/dL. Under certain stress conditions or physiologic events there can be an increase to higher levels, which rarely surpass 6mg/dL. Although the presented case reflects an atypi-

cal presentation, with bilirubin level exceeding 14mg/dL, no other alteration or gene mutation were confirmed, neither in the UGT1A1 gene nor a heterozygous Crigler-Najjar-type structural mutation, as described in patients with Gilbert who developed severe unconjugated hyperbilirubinemia [1, 9].

Although the data on the pharmacological implications of Gilbert syndrome in the susceptibility towards paracetamol are limited, it indeed may have clinic importance. Despite not being the expected toxic effect of this drug, there might be another step regulating bilirubin metabolism that could be impaired. There are also several polymorphisms in UGT genes not identified and any toxicity related to genetic variations still need further study. [10] Due to inter-individual variability, paracetamol may also play a different pharmacokinetic profile in different patients and even potential individual exacerbating factors must be taken into account when evaluating the risk and mechanism of toxicity.

Conclusion

Gilbert's syndrome patients form a heterogeneous group with respect to paracetamol metabolism. Despite the lack of evidence, the combination of UGT1A1 mutation with this drug may imply a greater likelihood of liver damage following an overdose. Further studying is also needed in order to define if therapeutic doses should be lower than in general population.

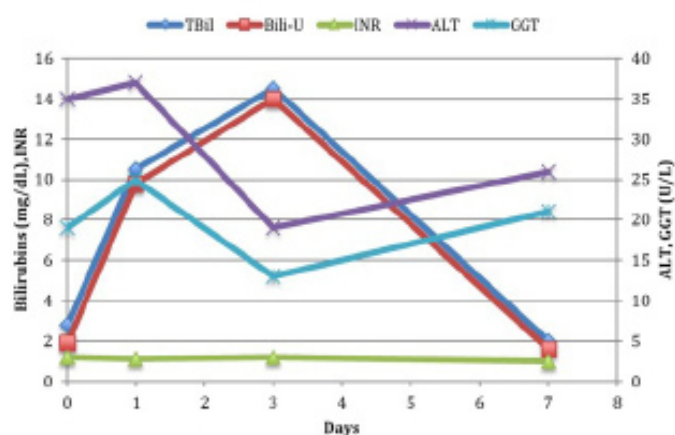


Figure 1: Dermoscopy aspect: Polymorphous vascular pattern, White-yellowish areas, and Ulceration

References

- Blueger AF, Krupnikova EZ, Sondore VY, Semushina EP. Study of the etiology and pathogenesis of low-grade non-hemolytic unconjugated hyperbilirubinemia (Gilbert's disease). *Acta Hepatogastroenterol (Stuttg)*. 1977; 24: 140.
- Claridge CL, Armstrong JM, Booth C, Paramjit SG. Gilbert's Syndrome. *BMJ*. 2011; 342: d2293
- Memon N, Weinberger IB, Hegyi T, Aleksunes ML. Inherited Disorders of Bilirubin Clearance. *Pediatr Res*. 2016; 79: 378-386.
- Mazaleuskaya LL, Sangkuhl K, Thorn FC, FritzGerald AG, Altman BR, et al. Pathways of acetaminophen metabolism at the therapeutic versus toxic doses. *Pharmacogenet Genomics*. 2015; 25: 416-426.
- Caparrotta MT, Antoine JD, Dear WJ. Are some people at increased risk of paracetamol-induced liver injury? A critical review of the literature. *Eur J Clin Pharmacol*. 2018;

-
- 74: 147-160
6. Esteban A, Perez-Mateo M. Heterogeneity of paracetamol metabolism in Gilbert's syndrome. *European Journal of Drug Metabolism and Pharmacokinetics*. 1999; 24: 9-13.
 7. Yoon E, Babar A, Choudhary M, Kutner M, Pyrsopoulos N. Acetaminophen-induced hepatotoxicity: A comprehensive update. *Journal of clinical and translational hepatology*. 2016; 4: 131.
 8. Sandilans EA, Bateman DN. Adverse reactions associated with acetylcysteine. *Clin Toxicol (Phila)*. 2009; 47: 81-88.
 9. Seppen J, Bosma PJ, Goldhoorn BG, Bakker CT, Chowdhury JR, et al. Discrimination between Crigler-Najjar type I and II by expression of mutant bilirubin uridine diphosphate-glucuronosyltransferase. *J Clin Invest*. 1994; 94: 2385-2391.
 10. Burchell B, Soars M, Monaghan G, Cassidy A, Smith D, et al. Drug-mediated toxicity caused by genetic deficiency of UDP-glucuronosyltransferases. *Toxicol Lett*. 2000; 112: 333-340.