



Neurosyphilis and COVID-19: Symptom Overlap, Impact on Management and Further Implications for Management of Sexually Transmitted Infections During a Pandemic

Jonathan McGrath^{1*}; Tara McGinty¹; Maureen Lynch¹; Edel O'Regan¹; Peter O'Gorman¹; John S Lambert^{1,2}

¹Mater Misericordiae University Hospital, Dublin, Ireland.

²University College Dublin, Ireland.

*Corresponding Author(s): Jonathan McGrath

Infectious Diseases Specialist Registrar, Mater Misericordiae University Hospital, Eccles Street, Dublin, Ireland.

Tel: +353-1-803-2000;

Email: Jonathan.mcgrath@umail.ucc.ie

Abstract

Background: The Coronavirus Disease 2019 (COVID-19) pandemic, caused by the Severe Acute Respiratory Syndrome Coronavirus-2 (SARS-CoV-2) has had a significant impact on healthcare provision, both in acute inpatient management of critically-ill COVID-19 patients and also in regard to health services which have been curtailed in an effort to maximise resources in tackling the virus. The clinical manifestations of COVID-19 are highly varied and those of syphilis are notoriously protean. Notification rates for syphilis during the pandemic have fallen by approximately 30% in Ireland, the cause of which is likely multifactorial. We present a case of neurosyphilis diagnosed concurrently with COVID-19 highlighting both an overlap in symptomatology and also the challenges of managing non-COVID-19 infectious diseases during a global pandemic.

Case: A 29 year old male was diagnosed with COVID-19, confirmed on rtPCR for SARS-CoV-2, following presentation with 7 days of fever, dry cough, dyspnoea, sore throat and arthralgia. Symptoms resolved by Day 15 of illness. At Day 24, the patient experienced blurring of vision in his left eye, pain on eye movements and was diagnosed with anterior uveitis. Respiratory symptoms recurred at Day 31 and repeat SARS-CoV-2 PCR was positive at Day 37. The patient was admitted to hospital on Day 45 with an erythematous rash, worsening eye symptoms, headache and persistent respiratory symptoms. A diagnosis of neurosyphilis was made following a positive RPR of 1:128, with likely intermittent COVID-19. The patient was commenced on IV Penicillin G and remained in respiratory isolation for the duration of his inpatient stay.

Received: Nov 24, 2020

Accepted: Jan 04, 2021

Published Online: Jan 08, 2021

Journal: Journal of Case Reports and Medical Images

Publisher: MedDocs Publishers LLC

Online edition: <http://meddocsonline.org/>

Copyright: © McGrath J (2021). *This Article is distributed under the terms of Creative Commons Attribution 4.0 International License*

Cite this article: McGrath J, McGinty T, Lynch M, O'Regan E, O'Gorman P, et al. Neurosyphilis and COVID-19: Symptom Overlap, Impact on Management and Further Implications for Management of Sexually Transmitted Infections During a Pandemic. J Case Rep Med Images. 2021; 4(1): 1066.



Discussion & conclusion: This case illustrates an overlap in symptomatology between the two conditions with the skin rash potentially being attributable to either neurosyphilis or ongoing symptoms of COVID-19. Healthcare services must ensure access to STI services is maintained to prevent a potential increase in infections once social restrictions are lifted.

Background

Up to November 8th 2020, 49,242,837 cases of Coronavirus Disease 2019 (COVID-19) have been confirmed worldwide [1]. The pandemic, caused by the Severe Acute Respiratory Syndrome Coronavirus-2 (SARS-CoV-2) has had a significant impact on healthcare provision, both in context of acute inpatient management of critically-ill COVID-19 patients and also in regard to health services necessarily deemed non-essential, which have been curtailed in many areas in an effort to maximise resources in tackling the virus.

In Ireland, prior to the pandemic, notifications of Early Infectious Syphilis (EIS) have been increasing yearly since 2013, with a 61% increase in notified cases in 2019 compared to 2018 [2]. This trend is reflected internationally with the United States reporting a 71% increase in the rate of early syphilis between 2014 and 2018 [3]. Notification rates for syphilis during the pandemic however have fallen by approximately 30%, the cause of which is likely multifactorial [4].

While our understanding of COVID-19 continues to evolve, it is well established that the clinical manifestations are varied, including respiratory, gastrointestinal, dermatological and neurological manifestations amongst many others [5]. The clinical manifestations of syphilis are notoriously protean and notably more established, given clinical experience over time.

We present a case of neurosyphilis diagnosed concurrently with COVID-19 demonstrating prolonged respiratory symptoms and persistently positive real-time polymerase chain reaction (rtPCR) for SARS-CoV-2. The case highlights both an overlap in symptomatology but also the challenges of managing non-COVID-19 infectious diseases during a global pandemic.

Case

In mid-March 2020, a 29 year old male was diagnosed with COVID-19 following presentation with 7 days of fever, dry cough, dyspnoea, sore throat and arthralgia. SARS-CoV-2 RNA was detected on oro/nasopharyngeal swab via reverse transcription polymerase chain reaction (rtPCR) (Altona RealStar[®] SARS-CoV-2 RT-PCR Kit), with a Cycle threshold (Ct) value of 21.72 (Day 7 of illness, D7). The severity of symptoms and presence of normal vital signs meant that hospital admission was not indicated and the patient was placed in self-isolation for 14 days. During isolation, the patient made a good clinical recovery with complete resolution of symptoms at least five days prior to completion (D15).

This patient's past medical history included epilepsy, for which he took Sodium Valproate 500 mg BD and asthma, for which he took Budesonide/Formoterol 160 mcg/4.5 mcg BD and Salbutamol 100 mcg PRN. He reported a history of Men who have sex with men (MSM), and denied any prior history of Sexually Transmitted Infection (STI).

Twenty four days following initial symptom onset (D24), the patient experienced blurring of vision in his left eye, pain on eye movements and pre-orbital headache. Seven days following this (D31), he noticed a recurrence of dry cough and exertional dyspnoea. Ophthalmological assessment revealed bilateral anterior uveitis for which Prednisolone acetate 1% eye drops were prescribed. A repeat oro/nasopharyngeal swab taken due to recurrent respiratory symptoms detected SARS-CoV-2 RNA with a Ct value of 31.36 (VIASURE SARS-CoV-2 Real Time PCR Detection Kit on Roche FLOW Flex system), 30 days after the initial result and 37 days after initial onset of symptoms. On the advice Infectious Diseases services, he entered a second 14-day self-isolation period.

The patient developed an erythematous, maculopapular rash on Day 39, affecting his chest/back that spared the palms and soles of the feet. After eight days of the second isolation period (D45), the patient was admitted to hospital with this rash in addition to tinnitus, bilateral pre-orbital headache, vertigo, ongoing dry cough and exertional dyspnoea. He was not in significant respiratory distress with RR 28/min, O₂ 97% on Room Air (RA), BP 117/65 mmHg, HR 87 bpm and a temperature of 36.1°C. Lung auscultation was clear. Cranial nerve exam revealed mild pain on lateral eye movements but otherwise no abnormality. Routine bloodwork was unremarkable and Chest X-Ray was clear.

Serology demonstrated a positive Rapid Plasma Reagin (RPR) 1:128, positive Syphilis IgM EIA and T. pallidum particle agglutination at 1:20480. HIV 1+2 antigen/antibody was negative. Due to ocular involvement with documented uveitis, a diagnosis of neurosyphilis was made. Lumbar puncture revealed a Clear Cerebrospinal Fluid (CSF) with 0 WCC/RCC, protein 348mg/L, glucose 3.2 mmol/L (serum glucose 6.2 mmol/L). CSF VDRL and SARS-CoV-2 PCR were negative. The patient commenced treatment with intravenous Penicillin G with good improvement in symptoms over the course of his inpatient stay.

Given the recurrent respiratory symptoms it was felt that this individual may also be experiencing persistent or recurrent COVID-19 infection and as such was kept in respiratory precautions throughout his admission. Over the course of a 16-day inpatient stay he remained positive for SARS-CoV-2 on repeated oro/nasopharyngeal swabs despite subsequent resolution of respiratory symptoms including one rtPCR test performed 53 days following his initial positive result and 60 days following his initial symptoms in March (Ct value of 33.29). A final SARS-CoV-2 PCR carried out at Day 66 yielded a negative result. A point of care rapid antibody test proved positive for anti-SARS-CoV-2 IgG, 59 days following onset of symptoms.

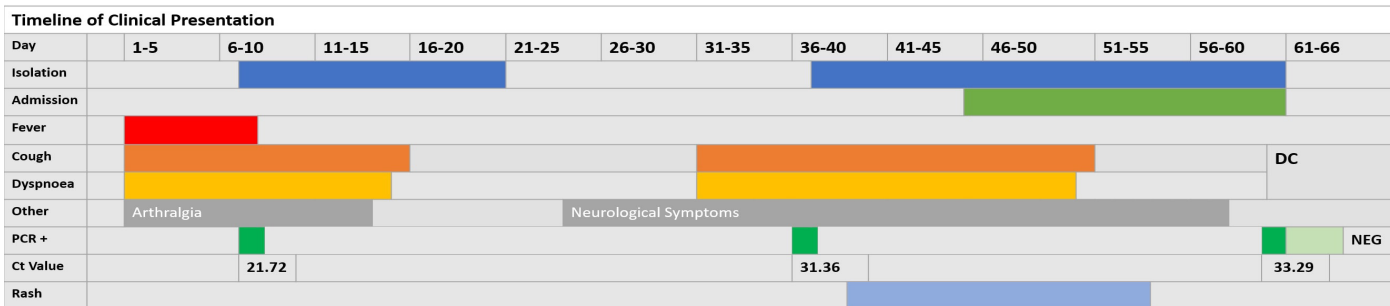


Figure 1: Timeline of Clinical Presentation.

Discussion

We present a case of laboratory confirmed COVID-19 infection concurrent with confirmed neurosyphilis. This case illustrates not only an overlap in symptomatology between the two conditions but also highlights ongoing consequences of the global pandemic on the provision of care for other infectious diseases, in particular STIs.

This patient’s COVID-19 infection was characterised by prolonged PCR-positivity (up to 60 days after onset of symptoms) and distinct episodes of recurrent respiratory symptoms. The symptom-free period between subjective resolution at the end of the initial isolation period and subsequent recurrence was 16 days. It is not clear whether the respiratory presentations represent a relapse of symptoms (intermittent presentation) of COVID-19 infection with prolonged viral shedding, or re-infection with new virus. We analysed Ct values for the positive SARS-CoV-2 PCR results to explore this concept, with values of 21.72 and 33.29 in the first and last positive rtPCR results respectively (Figure 1). The VIASURE SARS-CoV-2 Real time PCR Detection kit states that a sample is positive if the Ct value obtained is less than 38 [6]. The Altona RealStar® SARS-CoV-2 Detection kit does not provide specific Ct value thresholds for positivity but findings are consistent with those obtained with comparable kits. It is likely that these findings represent a reducing viral load from the original infection with relapsing symptoms, however increasing Ct values alone do not out rule re-infection or ongoing infectivity with the secondary episode. One review noted that the median duration of virus detection from symptom onset using upper respiratory tract samples was 14.5 days (median range 1-53.5 days) [7] but positive results up to 83 days have been reported [8]. While severe disease, ICU admission [9] and old age [10] have all been associated with prolonged viral shedding, a cohort study of 23 patients by Kai-Wang et al. demonstrated viral RNA detection in saliva after 20 or more days in 23% of mild cases [11]. One study of 262 COVID-19 patients observed that those who tested positive following discharge tended to be younger, with milder forms of COVID-19 during their initial hospitalisation [10]. In this cohort however, patients remained asymptomatic while the patient reported above had 2 distinct symptomatic presentations.

The scope and timing of dermatological manifestations of COVID-19 is yet to be fully determined. The American Academy of Dermatology’s COVID-19 Registry reports that among 171 lab-confirmed cases with cutaneous manifestations, morbilliform rash was reported in 22% of cases, macular erythema in 13% and vesicular eruptions in 11% [12]. It has been noted that a viral exanthem-like rash associated with COVID-19 can occur after the resolution of respiratory symptoms and subsequent discharge from hospital [13]. Furthermore, while pernio-like acral lesions are well described [14], up to 67% of COVID-

related rashes affect the trunk, as was the case in the above described patient [15]. The dermatological manifestations of secondary syphilis are well established. The rash is classically a diffuse, symmetric macular or papular eruption involving the entire trunk and often the extremities, including the palms and soles, however can vary widely in individual cases [16]. In the above patient, the combination of positive RPR (1:128), anterior uveitis and tinnitus indicates a diagnosis of neurosyphilis with oto/ocular involvement, despite the non-reactive CSF investigations and rash is known to occur in this setting [17]. The timing of onset of the rash in this patient falls 9 days following recurrence of respiratory symptoms and 16 days following onset of blurred vision. Due to the overlap in symptomatology of the concurrent infections it is difficult to say with certainty whether COVID-19 or neurosyphilis was the root cause of the rash. Indeed the headache reported could also be due to either COVID-19 or neurosyphilis, but in the context of uveitis it is felt to likely relate to the latter.

In the above patient, while the initial diagnosis of syphilis was not delayed due to COVID-19, inpatient care was impacted by the need to maintain respiratory precautions in the context of recurrent symptoms and persistently positive PCR results. These precautions were maintained for the duration of the 16-day inpatient stay with the inherent limitations in non-essential healthcare-worker contact and social contacts.

This case highlights a broader issue regarding the management of non-COVID infectious diseases during the global pandemic, in particular STI management. The pandemic has resulted in the necessary curtailing of non-essential medical services in many countries in an effort to redeploy staff and resources towards acute management of COVID-19 patients. However, concern is growing that prolonged suspension of services such as STI clinics may risk not detecting and treating these infections, which could lead to increased diagnoses once the pandemic is over [18]. In Ireland, prior to the pandemic, notifications of Early Infectious Syphilis (EIS) have been increasing yearly since 2013 [2]. In 2019, a 61% increase in notified cases was recorded compared to 2018, resulting in a crude notification rate of 13.9/100,000 population in 2019 compared to 10.2/100,000 and 8.4/100,000 for 2018 and 2017, respectively [2]. This trend is reflected internationally with the United States reporting a 71% increase in the rate of early syphilis between 2014 and 2018 [3] and England reporting that syphilis cases have more than doubled between 2013 and 2018 [19]. During the pandemic in Ireland, up to November 2020, there was a reported 28.59% reduction in notified EIS cases compared to the same timeframe in 2018 [4]. Reductions in reporting of syphilis cases have also been noted internationally, with a reduction in US cases of 6.9% compared to 2019 up to week 40 of 2020 [20].

The causes of this reduction are multifactorial. Reduced social contact due to national lockdowns will likely impact infection rates, with one study noting a 44% reduction in numbers of sexual partners per person during restrictions [21] but hesitance to seek testing or lack of facility to obtain testing due to restrictions is also a potential contributing factor.

As knowledge regarding the varied clinical presentations of COVID-19 infection continues to evolve, overlap with other clinical syndromes will likely be further noted. As the pandemic continues, health care systems will need to continue to adapt to the crisis to ensure management of non-COVID-19 infections including STIs is maintained.

References

- World Health Organization (WHO). WHO Coronavirus Disease (COVID-19) Dashboard. 2020.
- G. Cullen PD, M. Brady, D. Igoe. Update on trends in Early Infectious Syphilis. SSSTDI Autumn Meeting; 22-23 November; Dublin2019.
- Centres for Disease Control and Prevention. Sexually Transmitted Disease Surveillance 2018. 2019.
- Health Protection Surveillance Centre. Statutory Notifications of HIV and STIs reported in Ireland via the Computerised Infectious Disease Reporting (CIDR) system for: Week 45. 2020.
- Lechien JR, Chiesa-Estomba CM, Place S, Van Laethem Y, Cabaraux P, Mat Q, et al. Clinical and epidemiological characteristics of 1420 European patients with mild-to-moderate coronavirus disease 2019. *J Intern Med*. 2020; 288: 335-344.
- CerTest Biotech. Viasure Real Time PCR Detection Kits. Coronavirus 229E, NL63, OC43 & HKU1.
- Health Information and Quality Authority. Evidence summary for SARS-CoV-2 viral load and infectivity over the course of an infection. 2020.
- Li N, Wang X, Lv T. Prolonged SARS-CoV-2 RNA shedding: Not a rare phenomenon. *Journal of Medical Virology*. 2020; 92: 2286-2287.
- Chen J, Qi T, Liu L, Ling Y, Qian Z, Li T, et al. Clinical progression of patients with COVID-19 in Shanghai, China. *Journal of Infection*. 2020; 80: e1-e6.
- An J, Liao X, Xiao T, Qian S, Yuan J, Ye H, et al. Clinical characteristics of the recovered COVID-19 patients with re-detectable positive RNA test. medRxiv. 2020: 2020.03.26.20044222.
- To KK-W, Tsang OT-Y, Leung W-S, Tam AR, Wu T-C, Lung DC, et al. Temporal profiles of viral load in posterior oropharyngeal saliva samples and serum antibody responses during infection by SARS-CoV-2: an observational cohort study. *The Lancet Infectious Diseases*. 2020; 20: 565-574.
- Freeman EE, McMahon DE, Lipoff JB, Rosenbach M, Kovarik C, Desai SR, et al. The spectrum of COVID-19-associated dermatologic manifestations: An international registry of 716 patients from 31 countries. *J Am Acad Dermatol*. 2020; 83: 1118-1129.
- Recalcati S. Cutaneous manifestations in COVID-19: a first perspective. *J Eur Acad Dermatol Venereol*. 2020; 34: e212-e3.
- de Masson A, Bouaziz JD, Sulimovic L, Cassius C, Jachiet M, Ionescu MA, et al. Chilblains is a common cutaneous finding during the COVID-19 pandemic: A retrospective nationwide study from France. *J Am Acad Dermatol*. 2020; 83: 667-670.
- Sachdeva M, Gianotti R, Shah M, Bradanini L, Tosi D, Veraldi S, et al. Cutaneous manifestations of COVID-19: Report of three cases and a review of literature. *J Dermatol Sci*. 2020; 98: 75-81.
- Chapel TA. The signs and symptoms of secondary syphilis. *Sex Transm Dis*. 1980; 7: 161-164.
- Marx GE, Dhanireddy S, Marrazzo JM, Tuddenham SA, Rompalo AM, Leone PA, et al. Variations in Clinical Presentation of Ocular Syphilis: Case Series Reported From a Growing Epidemic in the United States. *Sex Transm Dis*. 2016; 43: 519-523.
- Napoleon SC, Maynard MA, Almonte A, Cormier K, Bertrand T, Ard KL, et al. Considerations for STI Clinics During the COVID-19 Pandemic. *Sexually transmitted diseases*. 2020; 47: 431-433.
- Public Health England. Addressing the increase in syphilis in England: PHE Action Plan. 2019.
- Crane MA, Popovic A, Stolbach AI, Ghanem KG. Reporting of sexually transmitted infections during the COVID-19 pandemic. *Sexually Transmitted Infections*. 2020.
- Li W, Li G, Xin C, Wang Y, Yang S. Challenges in the Practice of Sexual Medicine in the Time of COVID-19 in China. *J Sex Med*. 2020; 17: 1225-1228.