



“Looks Can Be Deceiving”: Atypical Brain Metastases Mimicking Neurocysticercosis, A Case Report and a Review of the Literature

Luigi F Saccaro^{1,2*}; Simone Ferranti³; Enrico Tagliaferri³; Valentina Galfo³; Silvia Fabiani³

¹Psychiatry Department, Faculty of Medicine, University of Geneva, Switzerland.

²Psychiatry Department, Geneva University Hospital, Switzerland.

³Department of Infectious Diseases, Pisa, Italy.

*Corresponding Author(s): Luigi Francesco Saccaro

Psychiatry Department, Geneva University Hospital,
Switzerland.

Email: LuigiFrancesco.Saccaro@unige.ch

Received: May 15, 2023

Accepted: June 09, 2023

Published Online: June 16, 2023

Journal: Journal of Case Reports and Medical Images

Publisher: MedDocs Publishers LLC

Online edition: <http://meddocsonline.org/>

Copyright: © Saccaro LF (2023). This Article is distributed under the terms of Creative Commons Attribution 4.0 International License

Keywords: Lung cancer; Neurocysticercosis; Cystic Brain Metastases

Key Clinical Message

This article reports a case of rare metastatic lung adenocarcinoma presenting with atypical cystic brain lesions initially diagnosed as neurocysticercosis. The differential diagnosis of brain metastases of lung cancer should be known by all clinicians working in the field, so as to reduce the diagnostic delay of cystic brain metastases.

Abstract

Background: The ingestion of eggs of *Taenia solium* (also called pork tapeworm) determines infestation of the Central Nervous System (CNS) by the larval form of parasites with the formation of multiple cysts. The main diagnostic criteria for neurocysticercosis is the evidence of cystic lesions showing the presence of scolex on neuroimaging studies, typically MRI) or CT.

Neurocysticercosis represents the most common parasitosis of the nervous system in the developing world, being also the leading cause of acquired epilepsy.

Sporadic cases of neurocysticercosis are reported in Italy and the vast majority of patients are infected abroad. We hereby describe the case of a patient initially diagnosed with neurocysticercosis because of multiple cystic intracranial lesions, which were finally identified as brain metastases of primary lung adenocarcinoma.

Case presentation: A 67-year-old Italian-born Caucasian woman with a subacute history of gait disorders was admitted to the Infectious Diseases Unit of the Hospital of Pisa in Italy in February 2018, with a suspected diagnosis of neurocysticercosis. MRI showed multiple supra- and infratentorial cystic lesions, some of which had a “dot” within the cyst, suggesting the presence of scolex, which would have been an absolute diagnostic criterion for neurocysticercosis. Serological tests for cysticercosis were negative. This result, together with the negative epidemiology, the number and dimensions of the cysts, and a study of the literature, prompted thoracic TAC-PET imaging, because of the suspect of metastatic lung cancer. CT scan showed a spiculated nodule in the latero-basal segment of the left lower lobe and numerous other solid pulmonary nodules. A fine needle biopsy of the main lesion confirmed the diagnosis of adenocarcinoma (NSCLC).

After an onco-pneumological consultancy, it was decided not to start antineoplastic therapy and the patient was moved



Cite this article: Saccaro LF, Ferranti S, Tagliaferri E, Galfo V, Fabiani S. “Looks Can Be Deceiving”: Atypical Brain Metastases Mimicking Neurocysticercosis, a Case Report and a Review of the Literature. J Case Rep Clin Images. 2023; 6(1): 1143.

into a day hospice, where she expired about one month after her admission to our ward.

Conclusions: This case illustrates the importance of the differential diagnostic approach to peculiar radiological features that on first examination might appear suggestive of neurocysticercosis. The unusual clinical presentation of this case and the radiological aspect of brain lesions delayed our patient's diagnosis of primary cancer. Lack of perilesional edema, cystic appearance and the supposed identification of scolex within cysts led, at first, to the diagnosis of neurocysticercosis. Despite the absence of constitutional symptoms, the possibility of malignancy should be considered in the differential diagnosis of brain cystic lesions.

Case Presentation

A 67-year-old Italian woman with a history of uterine fibroma and multiple thyroid nodularities was admitted to the University hospital of Pisa. The patient had not shown any particular sign or symptom till 2 weeks before.

She presented to an outside institution with a subacute history of gait disorders and motor slowing. She had no constitutional symptoms or cognitive impairment. Magnetic Resonance Imaging (MRI) of the brain performed in the aforementioned institution showed multiple supra- and infratentorial cystic lesions similar in signal intensity to the cerebrospinal fluid (CSF) on the T1- and T2-weighted images (**Figures 1, 2**), with intermediate signal in T2-weighted fluid-attenuated inversion-recovery (FLAIR) images (**Figures 3**), without perilesional edema. Some of these cysts seemed to have central enhancing dots, and most of these had peripheral enhancement (**Figures 4, 5**).

Since the neuroradiologist from the center where the patient was first visited suspected a diagnosis of neurocysticercosis, the patient moved to our institution for further investigation.

She reported a history of smoking, hypertension, and dyslipidemia. She denied constitutional symptoms and did not report traveling abroad.

On physical examination, besides the above-mentioned symptoms, she appeared in good health with normal cognitive performance and vital signs.

Abdominal and pulmonary examination was normal, apart from a slight decrease in vesicular sounds. Despite the heavy brain involvement revealed by the imaging, the remaining neurological examination was unremarkable except for slight hyperreflexia with minimal spreading of the ankle jerk reflexogenic area. Gait disorders were more evident when she went up and down the stairs and she had no nystagmus nor sensitivity abnormalities.

Cardiac, pulmonary, and abdominal findings were normal.

In the following days, slight diffuse hyposthenia was noted, and the patient showed increasing difficulty in reaching and maintaining an upright posture, the gait became more unstable and a light but progressive cognitive slowing appeared.

Her electroencephalogram showed rapid frequencies and abnormalities in the right temporal lobe.

In the suspect of neurocysticercosis, antiepileptic prophylaxis (levetiracetam) and steroid (dexamethasone) were started, to negate the risk of potential exacerbation associated with the

scheduled treatment with albendazole.

A serological test (enzyme-linked immunoelectrotransfer blot assay) for cysticercosis was negative, despite the significant number and dimension of brain lesions. Considering this data and that Italy is not an endemic country for cysticercosis, we investigated other alternative diagnoses.

Abdominal and thoracic Computer Tomography (CT) with and without contrast were performed. This showed a spiculated 15 mm nodule in the lateral basal segment of the left lower lobe (**Figure 6**) suspicious for a primary lung tumor and numerous other solid pulmonary nodules.

The sample from a Fine Needle Aspiration Cytology (FNAC) on the nodular lesion of the lung confirmed the diagnosis of a primary Non-Small Cell Lung Adenocarcinoma (NSCLC).

Cytogenetic FISH showed: ALK rearrangement in 80% of neoplastic cells, ROS1 rearrangement in 8% of neoplastic cells, low expression of PD-L1 (2% of neoplastic cells). No mutations were found in the EGFR and KRAS genes.

After onco-pneumological consultancy, it was decided not to begin antineoplastic therapy due to the stage and extension of the pathology. Palliative support care with high-dosage steroids and levetiracetam were started and the patient was moved to a day hospice. Her cognitive status gradually deteriorated as far as motor capacities, she was rapidly bedridden and needed bladder catheterization. She died about one month later.

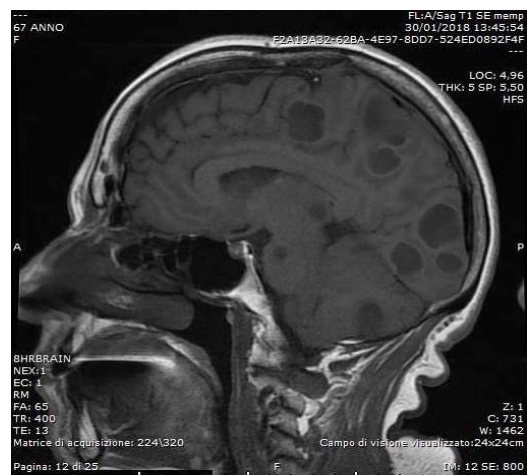


Figure 1: Multiple cystic lesions in sagittal T1-weighted MRI.

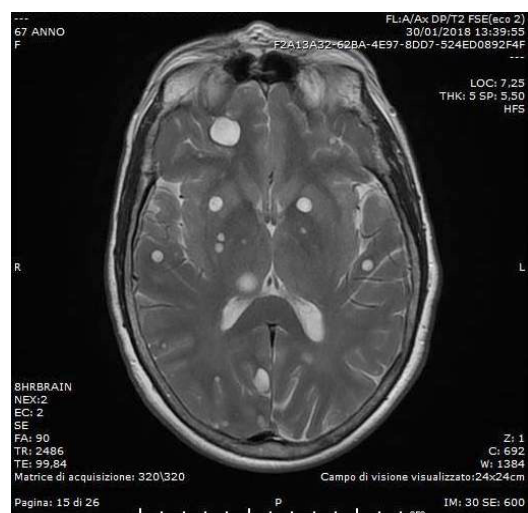


Figure 2: Multiple cystic lesions in axial T2-weighted MRI.

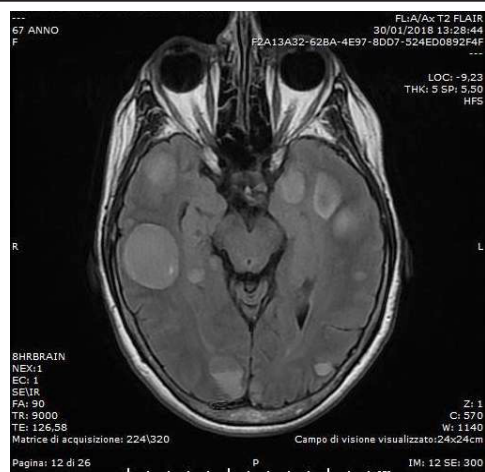


Figure 3: Multiple cystic lesions in axial T2-weighted FLAIR MRI.

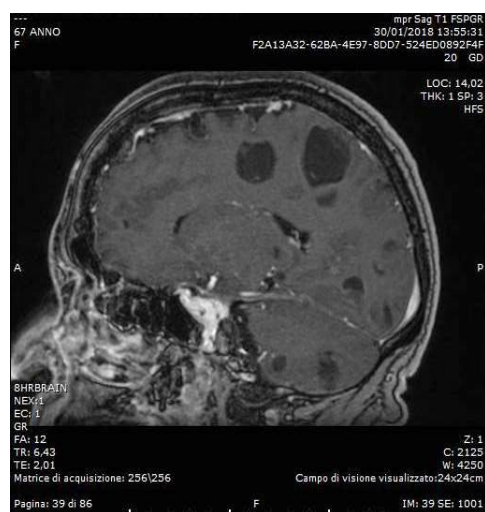


Figure 4: Multiple cystic lesions in sagittal T1-weighted MRI.

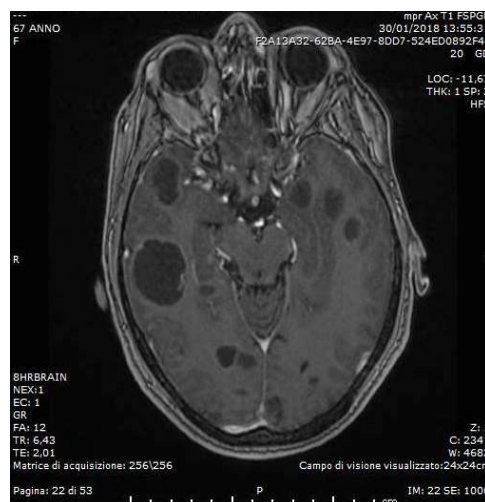

Figure 5: Multiple cystic lesions in axial T2-weighted MRI.

Disclosure

Written informed consent for publication of clinical details and clinical images was obtained from the patient.

Discussion

The most common primary solid tumor responsible for brain metastases is NSCLC, which can present with a variety of clinical manifestations [1]. Multiple brain metastases are frequent (10–30% of patients with cancer) and can be identified at contrast-

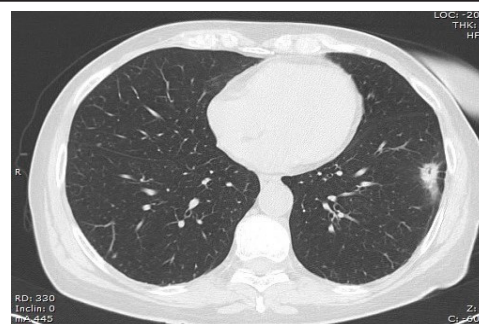


Figure 6: Spiculated lung lesion in axial TC.

enhanced MRI, which has been found [2] to be an extremely sensitive (97%) and specific (100%) imaging modality for the diagnosis of brain metastatic lesions from lung cancers [3]. These typically appear iso- to hypointense in T1-weighted images, hyperintense in T2-weighted images, and hyperintense in T2-weighted FLAIR. The enhancement pattern can be uniform, inhomogeneous, or ring-enhancing but it is usually intense. Brain metastases typically have variable amounts of surrounding vasogenic edema [4,5]. Post-mortem studies show that brain metastases in lung cancer can be asymptomatic in up to 25% of patients [6]. The differential diagnosis of cystic brain lesions includes primary tumors and vascular, inflammatory, or infectious diseases such as brain abscess, tuberculoma [7], neurocysticercosis, and sarcoidosis. Cystic brain metastases have been reported, for example, in malignancies of the lung, the prostate, the thyroid, the breast, and the thymus [8-13].

Not surprisingly, neurocysticercosis may be initially misdiagnosed as cystic brain metastasis [14].

If the primary tumor is not identified, systemic cancer is well controlled, and if the patient is a long-term survivor, definitive proof of the nature of brain cysts can be obtained with brain biopsy [15]. However, our patient did not meet any of these criteria, since a primary cancer with a known propensity for brain metastases was identified and there was a heavy metastatic burden. Thus, to avoid invasive procedures and additional suffering for the patient, we did not perform a brain biopsy.

In this case, the brain metastases were initially diagnosed, in another institution, as neurocysticercosis, an infection of the CNS caused by the larval stage of the tapeworm *Taenia solium*. In the developing world, it is the most common parasitosis of the nervous system and is the leading cause of acquired epilepsy.

This condition commonly presents with multiple intracranial lesions that differ on MRI according to the developmental stage [16,17].

Vesicular (viable) cysts are well circumscribed and rounded with a “hole-with-dot” appearance due to the hyperintense eccentric scolex in their interior, with little or no enhancement on gadolinium-enhanced images. They do not have significant surrounding edema or inflammation and likely cause seizures because of mass effect. On the other hand, colloidal and granular cysts cause pro-epileptogenic inflammation and have associated edema, with ill-defined margins and an enhancement pattern after contrast medium administration [18]. Calcified (dead) cysticerci appear on CT as hyperdense nodules without surrounding edema nor abnormal contrast enhancement: their epileptogenicity may be explained by gliosis, antigen exposure, or hippocampal sclerosis [19].

Other less frequent manifestations include compression

stroke, hypertension possibly related to hydrocephalus (especially in the case of intraventricular neurocysticercosis), chronic meningitis (because of subarachnoid or spinal cord lesions) [20], granular ependymitis, cysticercotic encephalitis, ophthalmologic and endocrinologic manifestations, progressive decrease in visual acuity and other ophthalmological symptoms related to vitritis, uveitis, or endophthalmitis (in the case of intraocular cysticercosis), and various degrees of cognitive impairment [16]. Most of the symptoms appear between 3 and 5 years after infection, but they may not manifest for 30 years or longer [20].

Absolute diagnostic criteria of neurocysticercosis are: histologic demonstration of the parasite from a biopsy of a brain or spinal cord lesion; evidence of parasitic cyst with a usually eccentric scolex; and/or direct visualization of subretinal parasites by fundoscopic examination [16]. Positive serum immunoblot is a major diagnostic criterion, being a sensitive (reaching 94% in patients with multiple cysts, as in our case) and specific test [20].

In the first institution where our patient was initially visited, she was diagnosed with neurocysticercosis, similar characteristics can be found for neurocysticercosis and lung cancer (**Table 1**). Reasons for such an erroneous diagnosis may have been: the presence of multiple brain cystic lesions, whose content appeared similar to CSF on T1- and T2-weighted images; the identification of an eccentric structure within some of the cysts in T1-weighted images, seen as an eccentric focus of enhancement in gadolinium-enhanced T1-weighted images, which was firstly misinterpreted as the scolex; lack of surrounding edema; the presence of ring enhancement of some cysts.

The first three points might have been suggestive of cysts at the vesicular developmental stage, while the fourth point would be more compatible with colloidal cysts than with vesicular cysts.

Elements against the parasitic etiology were: the negative local epidemiology; the number (more than 40), the dimensions (up to 3 cm) and the different shapes (round, oval, irregular) of the cysts; the intermediate signal in T2-weighted FLAIR images of the cysts; the presence of peripheral inhomogeneous bright enhancement of some cysts; the presence of enhancing mural nodule within the cysts; the absence of serological markers.

Considering recent evidence of clustering of cysticercosis patients around *Taenia solium* carriers, human cysticercosis should be considered a disease mostly transmitted from person to person [21]. Albeit endemic in developing countries, neuro-

cysticercosis is also present in developed countries, where it is mostly diagnosed in immigrants. However, it has been diagnosed in native persons without a history of traveling abroad, as well [16]. Effective eradication of neurocysticercosis requires targeting of infected pigs, eggs in the environment, and human carriers [22]. Treatment includes albendazole as a first-line therapy or praziquantel. Since cyst death is often associated with inflammation, also dexamethasone is indicated. For such reasons, anthelmintic therapy might be contraindicated for ocular disease [20]. Antiepileptic prophylaxis is necessary both due to the disease and to the pro-inflammatory action of the anthelmintic therapy, which may cause a worsening of the symptoms, seizures included [20]. Antiparasitic treatment is usually effective against active cysts, but not against calcified ones. Albendazole, in particular, has been found to reduce generalized tonic-clonic seizures due to neurocysticercosis. However, 49% of patients who presented with new-onset seizures have a recurrence of seizures at four years, while patients with calcified lesions and with normalized imaging studies have a better prognosis [23].

Review of the literature

Five cases [13,24-27] of cystic brain metastases from lung adenocarcinoma misdiagnosed as neurocysticercosis have been identified, and one of cystic brain metastases from a lung neuroendocrine tumor [28]. All studies are summarized with principal findings in **Table 2**. In all cases, the initial misdiagnosis of neurocysticercosis was supported by some radiological findings (MRI and CT). In the first case [24], also Magnetic Resonance Spectroscopy (MRS) offered misleading clues.

In all cases, antiparasitic therapy was begun, but negative serology and/or chest X-ray identifying the possible primary tumor prompted further exams to verify the alternative diagnosis of metastatic disease. In four cases [13,24,25,27] brain biopsy or resection was performed, and cytological diagnosis was made from the sample. In the other two cases [26,28], where neither brain biopsy nor resection was made, the treatment included palliative radiotherapy.

In four cases [13,24,26,28], including neuroendocrine carcinoma [28], radiotherapy was administered with overall beneficial effects. In the case of the neuroendocrine carcinoma, the therapy was palliative.

In all cases, treatment was delayed due to the misdiagnosis, ranging from a delay of one month to many years.

Table 1: Neurocysticercosis vs cerebral metastases.

Neurocysticercosis	Cerebral metastases
Multiple cysts	Multiple cysts
Typically 1-2 cm in diameter	Various size and shapes
Grey-white matter junction or subarachnoid	Grey-white matter junction or arterial watershed areas
Vesicular stage: CSF intensity, eccentric hyperintense scolex in T1. no edema	Hypointense in T1 and hyperintense in T2
Colloidal stage: hyperintense in T1, edema, ring- enhancement	Presence of ring-enhancement
Granular nodular: small enhancing nodule, with reduced edema and enhancement	Presence of vasogenic edema
Nodular calcified: signal drop-out in T2, high signal in T1, long term enhancement (possible)	Hyperintense in FLAIR
	Disproportionate edema in DWI
	Possible presence of hemorrhage

Table 2: Neurocysticercosis vs cerebral metastases.

Author	Year	Underling cancer	Outcome
Kim SH (13)	2017	ALK-positive lung cancer	5-months clinical improvement
Mota PC (24)	2011	Cytokeratin-positive lung cancer	5-months clinical improvement
Choi H (25)	2012	Adenocarcinoma of unknown origin	
Hoang A (26)	2017	Lung adenocarcinoma	
Costa R (27)	2014	Cytokeratin-positive lung cancer	3-months clinical improvement
Lam JC (28)	2016	Neuroendocrine lung cancer	Death after 9 month

Conclusions

This case highlights the importance of working with a systematic approach and considering all differential diagnoses of intracranial cysts. In our case, brain metastatic lesions were initially diagnosed as neurocysticercosis, but the opposite can be true, as well. It is possible that brain lesions due to real neurocysticercosis are misdiagnosed for brain metastases [14,29-31]. The differential diagnosis of brain metastases of lung cancer should be known by all clinicians working in the field, so as to reduce the diagnostic delay of cystic brain metastases.

Acknowledgments

We thank Dr. Dhruv Panchal at the Neurology Unit, Addenbrooke's Hospital, Cambridge University Hospitals (UK), for his review of the style and content of the first draft of the manuscript.

We would like to thank the colleagues of Neuroradiology for their precious advice concerning the images.

Funding Information

No sources of funding were declared for this study.

References

- Klos KJ, O'Neill BP. Brain metastases. *The neurologist*. 2004; 10: 31-46.
- Russell EJ, Geremia GK, Johnson CE, Huckman MS, Ramsey RG, et al. Multiple cerebral metastases: detectability with Gd-DTPA-enhanced MR imaging. *Radiology*. 1987; 165: 609-617.
- Yokoi K, Kamiya N, Matsuguma H, Machida S, Hirose T, et al. Detection of brain metastasis in potentially operable non-small cell lung cancer: a comparison of CT and MRI. *Chest*. 1999; 115: 714-719.
- Sharma V, Prabhaskar K, Noronha V, Tandon N, Joshi A. A systematic approach to diagnosis of cystic brain lesions. *South Asian journal of cancer*. 2013; 2: 98.
- Strugar J, Rothbart D, Harrington W, Criscuolo GR. Vascular permeability factor in brain metastases: correlation with vasogenic brain edema and tumor angiogenesis. *J Neurosurg*. 1994; 81: 560-566.
- Posner J, Chernik N. Intracranial metastases from systemic cancer. *Adv. Neurol*. 1978; 19: 579-592.
- Lee H-J, Oh I-J, Park S-W, Ban H-J, Kim Y-C, et al. A Case of Miliary Brain Metastasis of Lung Cancer Mimicking Neurocysticercosis. *Tuberculosis and Respiratory Diseases* 2012; 72: 182-186.
- Surov A, Hainz M, Kornhuber M. Multiple cystic metastases in the brain from adenocarcinoma of the lung. *The American journal of medicine*. 2009; 122: e3-e4.
- Tsai V, Kim S, Clatterbuck RE, Ewend MG, Olivi A. Cystic Prostate Metastases to the Brain Parenchyma: Report of Two Cases and Review of the Literature. *J Neurooncol*. 2001; 51: 167-173.
- Yang J-T, Chang C-M, Lee M-H, Chen Y-J, Lee K-F. Thymic squamous cell carcinoma with multiple brain metastases. *Acta Neurol. Taiwan*. 2010; 19: 41-44.
- Troiani C, Lopes CCB, Scardovelli CA, Nai GA. Cystic brain metastases radiologically simulating neurocysticercosis. *Sao Paulo Med J*. 2011; 129: 352-356.
- Bago-Rožanković P, Bašić S, Vavro H, Rožanković M, Nikolić I, et al. Multiple Cystic Brain Metastases From Papillary Thyroid Carcinoma Mimicking Neurocysticercosis. *Int. J. Surg. Pathol*. 2013; 21: 390-393.
- Kim SH, Hyun JW, Kim HJ, Gwak HS, Lee SH, et al. De novo cystic brain lesions mimicking neurocysticercosis in ALK-positive lung cancer. *Lung Cancer* 2017; 110: 53-55.
- Coulibaly B, Gautier G, Fuentes S, Ranque S, Bouvier C. Degenenerating neurocysticercosis cysts: differential diagnosis with cerebral metastasis. *Rev. Neurol. (Paris)* 2008; 164: 948-952.
- Soffietti R, Cornu P, Delattre JY, Grant R, Graus F, et al. EFNS Guidelines on diagnosis and treatment of brain metastases: report of an EFNS Task Force. *Eur. J. Neurol*. 2006; 13: 674-681.
- Del Brutto OH, Rajshekhar V, White AC, Tsang VC, Nash TE, et al. Proposed diagnostic criteria for neurocysticercosis. *Neurology*. 2001; 57: 177-183.
- García HH, Gonzalez AE, Evans CA, Gilman RH; Cysticercosis Working Group in Peru. *Taenia solium* cysticercosis. *The Lancet*. 2003; 362: 547-556.
- Singh G, Rajshekhar V, Murthy JM, Prabhakar S, Modi M, Khandelwal N, Garcia HH. A diagnostic and therapeutic scheme for a solitary cysticercus granuloma. *Neurology* 2010; 75: 2236-2245.
- Nash TE, Del Brutto OH, Butman JA, Corona T, Delgado-Escueta A, et al. Calcific neurocysticercosis and epileptogenesis. *Neurology*. 2004; 62: 1934-1938.
- Mandell GL, Bennett JE, Dolin R. *Mandell, Douglas, and Bennett's principles and practice of infectious diseases*. Philadelphia: Churchill Livingstone/Elsevier. 2010; 3611.
- Lescano AG, Garcia HH, Gilman RH, Gavidia CM, Tsang VC, et al. Cysticercosis Working Group in Peru. *Taenia solium* cysticercosis hotspots surrounding tapeworm carriers: clustering on human seroprevalence but not on seizures. *PLoS Negl Trop Dis*. 2009; 3: e371.
- García HH, González AE, Del Brutto OH, Tsang VC, Llanos-Zavala F, et al. Cysticercosis Working Group in Peru. Strategies for the elimination of taeniasis/cysticercosis. *J Neurol Sci*. 2007; 262: 153-157.
- DeGiorgio CM, Medina MT, Durón R, Zee C, Escueta SP. Neurocysticercosis. *Epilepsy Curr*. 2004; 4: 107-111.

-
24. Mota PC, Reis C, Pires NF, Sousa G, Chamadoira C, et al. Lung cancer: Atypical brain metastases mimicking neurocysticercosis. *Int J Clin Oncol*. 2011; 16: 746-750.
 25. Choi H, Choi S. Multiple cystic brain metastases from adenocarcinoma mimicking cysticercosis. *Clin Neuroradiol*. 2012; 22: 105-107.
 26. Hoang A, Khine KT, O'Rese JK, Tesser RA, Chesnutt DA. A Rare Ocular Presentation of Metastatic Lung Cancer: Unilateral Anterior Chamber Angle, Bilateral Choroidal, and Multiple Intracranial Metastases. *J. Glaucoma*. 2017; 26: e93-e95.
 27. Costa R, Costa RB, Bacchi C, Sarinho F. Adenocarcinoma of the lung presenting with atypical cystic brain lesions. *BMJ Case Rep*. 2014; 2014: bcr2013203506.
 28. Lam JC, Robinson SR, Schell A, Vaughan S. Pulmonary neuroendocrine carcinoma mimicking neurocysticercosis: a case report. *J Med Case Reports*. 2016; 10: 144.
 29. Lau KY, Roebuck DJ, Mok V, Ng HK, Lam J, et al. MRI demonstration of subarachnoid neurocysticercosis simulating metastatic disease. *Neuroradiology* 1998; 40: 724-726.
 30. Guo A, Chen X, Guo F, Shashikiran T, Song L. Clinical Characteristic of 12 Misdiagnosed Cases With Rare Intracranial Infection. *Neurosurg Q*. 2016; 26: 129-135.
 31. Mahajan A, Patel M, Sable N, Thakur MH. Atypical T1 Hyperintense Neurocysticercosis Masquerading As Cystic Brain Metastases. *Journal of global oncology*. 2016; 3: 673-677.