



Lateral Pterygoid Muscle Preservation in Total Temporomandibular Joint Reconstruction with Stock Prosthesis

Shijing Yue; Jiong Zhao; Guo Bai; Minjie Chen*; Chi Yang*

Department of Oral Surgery, Shanghai Ninth People's Hospital, College of Stomatology, Shanghai Jiao Tong University School of Medicine; National Clinical Research Center for Oral Diseases; Shanghai Key Laboratory of Stomatology & Shanghai Research Institute of Stomatology; Research Unit of Oral and Maxillofacial Regenerative Medicine, Chinese Academy of Medical Sciences, Shanghai, China.

*Corresponding Author(s): Chi Yang

Department of Oral Surgery, Ninth People's Hospital,
Shanghai Jiao Tong University School of Medicine, 639
Zhi Zao Ju Road, Shanghai, China, 200011.
Email: yangchi63@hotmail.com

* These authors are co-correspondence authors.

Shijing Yue, Jiong Zhao & Guo Bai contributed equally to this work.

Received: Apr 12, 2022

Accepted: June 03, 2022

Published Online: Jun 06, 2022

Journal: Journal of Case Reports and Medical Images

Publisher: MedDocs Publishers LLC

Online edition: <http://meddocsonline.org/>

Copyright: © Yang C (2022). *This Article is distributed under the terms of Creative Commons Attribution 4.0 International License*

Keywords: Lateral pterygoid muscle preservation; Total joint reconstruction; Temporomandibular joint; Idiopathic condylar resorption; Osteoarthritis.

Introduction

Patients with non-neoplastic diseases of temporomandibular joint (TMJ), such as idiopathic condylar resorption (ICR) or osteoarthritis (OA), always complain about their pain in the area of TMJ, the limitation of jaw opening or facial deformity clinically. Surgical procedures focusing on TMJ reconstruction are considered when a patient comes with end-stage TMJ diseases [1-3]. Autogenous bone grafting and prosthesis are two sources for joint reconstruction [1].

Abstract

End-stage temporomandibular joint diseases often cause pain in the area of joint, jaw opening limitation or facial deformity, and treatment of total joint reconstruction is recommended. However, the surgical procedures generally ignored the reconstruction of Lateral Pterygoid Muscle (LPM), leading to mouth opening deviation unilaterally or vanishment of lateral movement bilaterally. Here, we explored the feasibility and effectiveness of a new method that LPM was kept attached to the pterygoid muscle fossa through proper condyle osteotomy to preserve LPM during Total Joint Reconstruction (TJR). 6 patients with a total of 7 joints undergoing TJR with LPM preservation were included in this retrospective study. Lateral movement of all 7 joints were restored post-operation, with an average 3.14 mm of lateral moving distance, together with bone healing well and LPM locating stably. Therefore, LPM preservation is essential for function regain of mandible lateral moving post TJR operation and this new method could be utilized to preserve LPM.

Generally, a Total Joint Reconstruction (TJR) device of TMJ consists of 2 parts: A mandibular implant and a fossa implant, which will form the mandibular condyle and glenoid fossa respectively [2]. Several literatures have confirmed its clinical effectiveness [4-8]. Also, TJR has advantages of long lifespan, less complication, predictable prognosis, easy availability for reconstruction materials and decreased bone healing to enable early physical therapy over autogenous bone TMJ replacement [9].



Cite this article: Yue S, Zhao J, Bai G, Chen M, Yang C. Lateral Pterygoid Muscle Preservation in Total Temporomandibular Joint Reconstruction with Stock Prosthesis. J Case Rep Clin Images. 2022; 5(1): 1110.

However, the Lateral Pterygoid Muscle (LPM) is usually cut off from lateral pterygoid fossa when removing the condyle and no longer reattached to the prosthesis according to TJR surgical procedures, as well as autogenous joint replacement [2]. Given the significant role LPM played in mandibular movement, sliding towards contralateral direction is not possible for a reconstructed TMJ. Therefore, an intractable problem that how to achieve the preservation of lateral pterygoid muscle and total joint replacement of TMJ simultaneously to fully restore post-operative function of lateral and protrusive motion of mandible remains to be solved.

From July 2017 to December 2019, a new technique with preservation of LPM and attached partial condylar neck and fixation to the prosthesis was tried in our group. In this study, the ability of the mandible moving in 6 patients with severe ICR or OA who received this new technique was evaluated through clinical and imaging examination before surgery and at least 12 months after the surgery.

Patients and methods

This study was approved by, and in accordance with, the recommendations of the Human Research Committee of Shanghai Ninth People's Hospital.

Patients

The patients for this study were selected in the department of oral surgery, Shanghai ninth people's hospital between July 2017 and December 2019. The inclusion criteria were as follow: (1) non-neoplastic disease of TMJ; (2) the condyle could not be preserved; (3) total joint stock prosthesis (Lorenz/Biomet company, USA) was planned to reconstruct the condyle; (4) by pre-operative digital design, the space between the glenoid fossa and the mandibular stump was enough to seat the preserved condylar neck and not to obstruct the prosthesis moving; (5) the contact area between the preserved condylar neck and the mandibular stump was stable enough; (6) follow-up period was more than 12 months.

Preoperative planning

Preoperative spiral CT scans (64-MDCT, General Electric Company, Massachusetts, USA) were obtained for all patients. The DICOM data was imported into Mimics 21.0 software (Materialise, Belgium) for preoperative planning (Figure 1). On a 3D reconstruction model with LPM, sectional condylar neck with attachment of LPM was marked carefully. The principle of osteotomy design was as follow: (1) damaged condylar head should be cut off; (2) bone with attachment of LPM should be preserved; (3) a gap of at least 1.5 cm between the glenoid fossa and the mandibular stump should attain for prosthesis; (4) trimming of the glenoid fossa and the outer surface of mandibular ascending ramus refer to previously reported [10]. Testing of the fossa and mandibular implant on the 3D reconstruction model was finally performed with the fixation of the condylar bone block and LPM (Figure 2). After simulation, the osteotomy guides and occlusal splints for intra-operative use were designed as previously reported [10] and manufactured by rapid prototyping technology.

Surgical procedures

All operations were performed under general anesthesia with nasotracheal intubation. A modified preauricular approach combined with submandibular incision was used to expose the TMJ and mandibular angle. Cut the lateral ligament, masseter

muscle, and periosteum of zygomatic arch to completely expose zygomatic arch, condyle and part of the attachment of LPM. The periosteum of the condylar neck was peeled off. Osteotomy was performed at the lower and upper boundary where LPM attached to the pterygoid muscle fossa and along the line going through the bottom point of sigmoid notch respectively, using a sagittal saw and osteotomy guides (Figure 3A-D). The LPM attachment on the anterior medial condyle head was preserved. A gap of at least 1.5 cm for prosthesis was attained. Then trim the outer shape of LPM attached bone block in the sagittal direction. A steel wire passed through the preserved condylar block (Figure 3E). Reshape the glenoid fossa and the mandibular ramus to accommodate TMJ stock prosthesis system. After the fixation of the whole prosthesis, the preserved condylar block was fixed to the prosthesis and contacted with the mandibular stump (Figure 3F). 5 ml cellulite was harvested near the submandibular incision and transplanted around the prosthesis to fill and eliminate the dead space. Intermaxillary fixation, occlusion check during the surgery, hemostasis and wound closure were accomplished observing the regular procedures of temporomandibular reconstruction. Two sets of surgical instrument and disinfection were used for intraoral and extraoral operation to avoid infection. Drains were put inside the incision and antibiotics were used after operation.

All patients were advised to undergo physiotherapy postoperatively. Panoramic X-Rays and CT scans were acquired 1 week and at least 12 months after surgery.

Evaluation

Maximum Interincisal Opening (MIO), mouth opening pattern, lateral and protrusive movement of the mandibular and pain were measured and documented. Patient satisfaction was evaluated through postoperative questionnaires. Stability and absorption of the preservation of condylar block and LPM was evaluated by CT scans.

Statistical analysis

Changes of MIO, protrusive moving distance and pain were compared respectively pre- and post- operation. Data on the MIO and protrusive moving distance were compared using the Statistical Package for Social Sciences software package, version 25.0 (SPSS, Chicago, IL) and the paired *t* test. The pain changes were analyzed using the Wilcoxon rank sum test. An α level of ≤ 0.05 was considered significant.

Results

6 patients with 7 joints undergoing TJR using standard stock prostheses were included in this research. They were all female at averaged age of 43.8 (ranged from 21 to 64). Their basic and surgical information were shown in Table 1. All joints went through TJR with LPM preserved. All the patients were in good condition after surgery and had an average follow-up of 26.0 months (range from 14 to 34 months).

Clinical performances of mandibular function - MIO, mouth open type, protrusive and lateral movements, and pain - before and after surgery were measured and listed in Table 2. MIO of all patients was greatly enhanced to a nearly normal level of an average opening of 34.83 mm post-surgery. Pain in TMJ area was much alleviated from 6.0 to 0.5 by VAS. Also, mouth open type was improved in patients. Average protrusive moving distance post-operation was a bit shorter than that pre-operation. As for lateral movement, a significant moving ability can be seen

in all of the joints, averaged 3.14 mm post-operation (Table 2).

Post-operative panoramic X-Rays and CT scans showed that all joints replaced by prostheses had a satisfying bone healing and no obvious bone absorption (Figure 4,5). Continuous cortical bone formed between condylar bone block and mandibular ramus stump (Figure 5C, E). The location of LPM was stable in the long-term axial CT follow up and volume modification change was less than 8%. (Figure 5D, F).

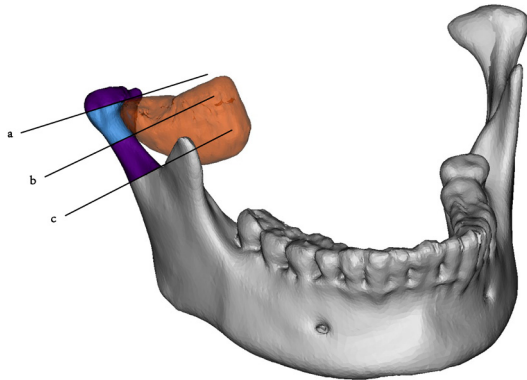


Figure 1: Osteotomy design for LPM preservation on a 3D mandibular reconstruction model. Osteotomy line a was used to remove affected articular surface of the condyle. The lower boundary of lateral pterygoid fossa was on the plane defined by osteotomy line b. Osteotomy line c crossed the bottom point of sigmoid notch. Generally, line b was parallel with line c. Bone block (blue) defined by osteotomy line a and b will be preserved, which also maintained connection with LPM (orange).

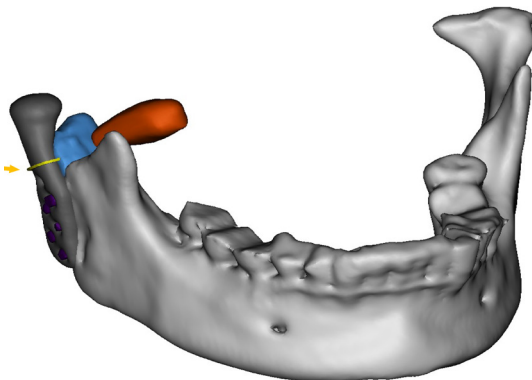


Figure 2: 3D reconstruction of mandible (white), mandibular prosthesis (gray) with fixing screws (purple), LPM (orange), and preserved condylar bone block (blue) post-operation. The steel wire (yellow) used to fix condylar bone block is indicated by a yellow arrow head.

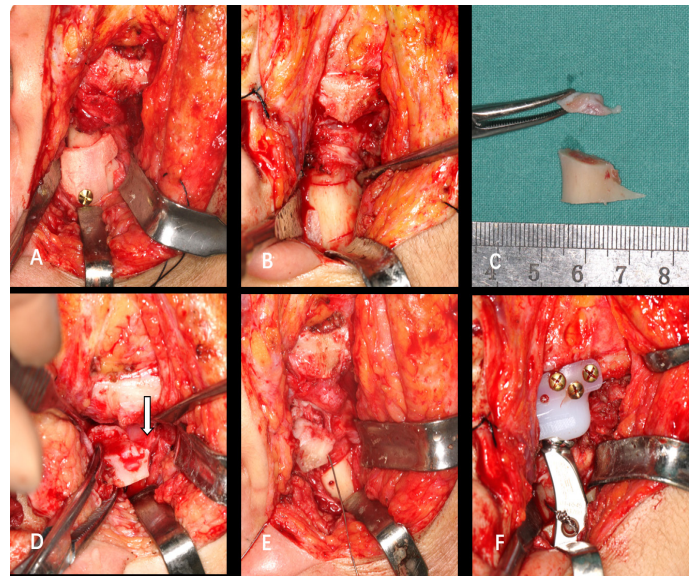


Figure 3: Surgical procedures. (A). fixation of the osteotomy guide; (B). three osteotomy lines-the lower and upper boundary where LPM attached and the line going through the bottom point of sigmoid notch; (C). removal of damaged condylar head and the unwanted condylar neck; (D). preservation of condylar block with attachment of LPM (arrow); (E). a steel wire passing through the preserved condylar block; (F). fixation of the prosthesis and the preserved condylar block.

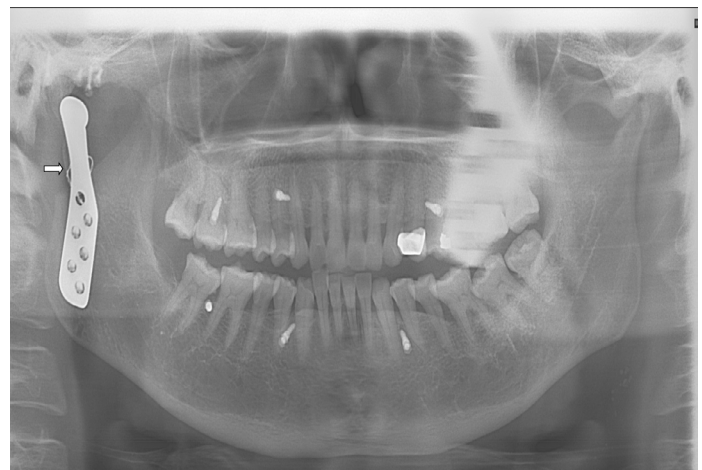

Figure 4: Post-operative panoramic X-Ray with fixation of the preserved condylar block using a steel wire (arrow).

Table 1: Basic information of the patients.

Patient No.	Age (Y)	Gender	Duration (Y)	Diagnosis	TJR Side	Preserved LPM Side	Follow-up (Mo)
1	52	Female	1	Bilateral OA	Right	Right	21
2	64	Female	4	Bilateral OA	Left	Left	34
3	21	Female	3	Bilateral ICR	Left	Left	14
4	21	Female	8	Bilateral ICR	Bilateral	Bilateral	32
5	48	Female	0.83	Left OA	Left	Left	28
6	57	Female	3	Right OA	Right	Right	27
Average	43.8		3.3				26.0
Total					7	7	

TJR, total joint reconstruction; ICR, idiopathic condylar resorption; OA, osteoarthritis.

Table 2: Clinical information of the patients pre- and post-operation.

Patient No.	Preserved LPM Side	MIO (mm)		MOT		PM (mm)		LM (mm)		Pain (VAS)		Patient Satisfaction (VAS)
		T0	T1	T0	T1	T0	T1	Left	Right	T0	T1	
1	Right	30	40	Right	Right	2	2	-	7	7	0	9
2	Left	30	31	Right	Left	1	1	2	-	8	0	9
3	Left	23	31	Left	Left	3	1	2	-	4	0	10
4	Bilateral	28	36	Median	Median	2	3	2	3	3	0	10
5	Left	35	38	Left	Median	1	1	2	-	6	1	9
6	Right	30	33	Right	Right	2	2	-	4	8	2	8
Average		29.33*	34.83*			1.83	1.67	3.14				9.2
Median (Q1, Q3)										6.5** (4.5, 7.75)	0** (0, 0.75)	

T0, time before TJR surgery; T1, time of the latest follow-up post-operation; MIO, maximum interincisal opening; MOT, mouth opening type; PM, protrusive movement; LM, Lateral moving distance in the latest follow-up; Pain was evaluated by VAS, visual analogue scale/score ("0" means no pain, "10" means severe pain, from "0" to "10" means increasing pain); Patient satisfaction after TJR surgery was evaluated by VAS ("0" means very much dissatisfied, "10" means very much satisfied, from "0" to "10" means increasing satisfaction); Q1, 1st quartile; Q2, 3rd quartile.

* $P = 0.014$, paired t test; ** $P = 0.028$, Wilcoxon rank sum test.

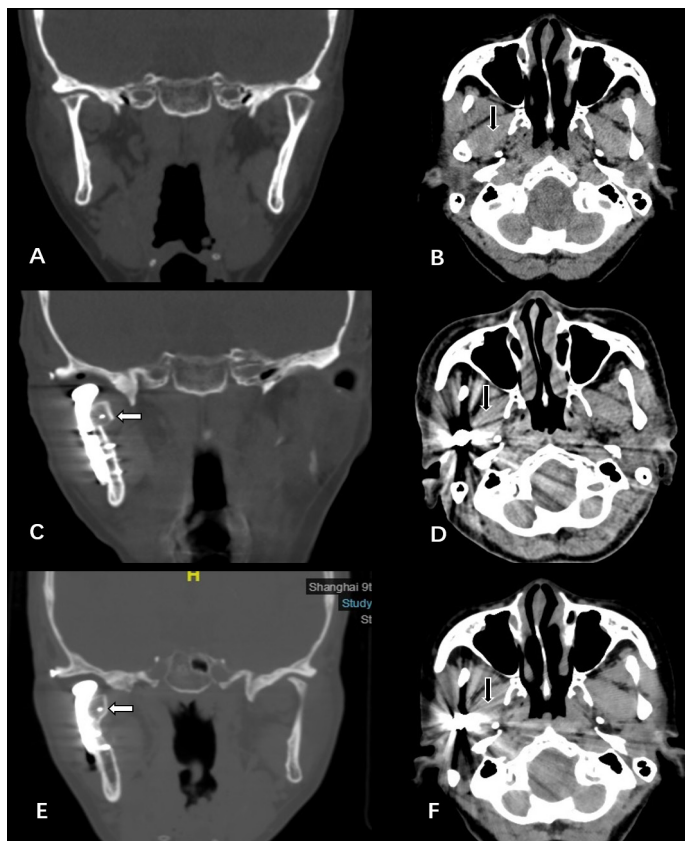


Figure 5: CT scans of a patient with right condylar OA. (A). right condylar resorption in preoperative coronal CT of bone window; (B). LPM attachment in preoperative axial CT of soft tissue window; (C). stable fixation of preserved condylar block in coronal CT of bone window 1 week after operation; (D). preserved LPM attachment in axial CT of soft tissue window 1 week after operation; (E). no absorption of preserved condylar block was found in coronal CT of bone window 2 years after operation; (F). LPM attachment was located stable in axial CT of soft tissue window 2 years after operation.

Discussion

LPM inserts into the LPM fossa in front of the condyle, as well as the articular disk of the temporomandibular joint through the capsule [11]. The function of this muscle is to protrude mandible or draw one of the two condyles forward allowing the mandible to slide to the opposite side. However, the insertion of LPM used to be cut off to ensure a full resection of diseased condyle during TJR, leading to the function of LPM lost or severely compromised. Preserving LPM is considered to be beneficial for moving ability post-operation. Thus, the TJR surgery should be cooperated with muscle reconstruction to restore LPM function and a new LPM preservation technique was shown here.

In this retrospective study, a total of 6 patients with 7 joints were included and their mandibular moving ability were analyzed mainly through clinical indicators such as MIO and distance of lateral movement. The average MIO was obviously augmented after TJR, as well as the pain in the area of TMJ being greatly alleviated, which eliminated the symptoms of temporomandibular diseases. As for lateral movements, all of the joints replaced by prostheses preserved LPM through the new technique that muscles were kept attached with the condyle bone blocks after condyle osteotomy and then reattached to the prostheses using steel wires. Bone healed well according to the CT scans follow up. The average lateral moving distance of all joints was 3.14 mm, demonstrating a considerable and impressing improvement in the LPM function after TJR with muscle reconstruction. Patient satisfaction score after TJR averaged 9.2 (range from 8 to 10) by VAS, which means they were satisfied with their mandibular, especially chewing, function. Thus, the technique we used is feasible and effective clinically, and provide a new way for muscle reconstruction.

There was no surgeon ever tried to reattach LPM to attain a complete functional reconstruction of TMJ until 1996. Rasee [12] was the first to reconstruct LPM in a case by mattress suturing it to the rib just below its cartilage following a free autogenous, osteochondral rib graft fixed to the ramus. Later, Collins and his colleagues [13] investigated the results of 24 joints in 14 patients receiving a lateral pterygoid myotomy with/without re-

attachment to the condyle after TJR surgery. LPM was dissected from the condyle and sutured to the anterior aspect of the remaining condylar neck during their surgery. These researches demonstrated that the preservation of LPM is indisputable essential for a complete function restoration of TMJ. However, the two studies both followed the concept of cutting and re-suturing in terms of LPM preservation. Although that is a method simple and easy to execute, there is a risk of sutures being broken or loose, as well as a poor reattachment of the LPM to prosthesis. To prevent being in such a dilemma, we have innovated a more reliable approach to preserve LPM and testified its feasibility and effectiveness in 3 patients undergoing temporomandibular joint reconstruction with costochondral grafts (data not published). Here, the same method was utilized to preserve LPM in TJR to explore its new possibility. By this approach, we could keep not only the integrity of attachment between condyle and LPM also as much muscle fibers as possible through delicate condyle osteotomy. This newly-add surgical procedure will take a longer time to accomplish though, the cons can be offset by its pros that it avoids the risk of sutures loosing and difficulty for muscle to reattach to the prosthesis, which is unique and cannot be ignored. Meanwhile, the location and volume of LPM are stable in the long-term. In addition, a sufficient blood supply for the remaining condyle bone block after osteotomy will be attained, which is beneficial for post-operation anti-infection and osseointegration. In a word, this method possesses characteristics of preserving intact LPM-bone attachment, micro-movement and minimally invasive, which benefit patients a lot.

Still, there are some limitations for this new method. Given the lateral moving distance of mandible in Chinese population with normal TMJ is 5-7 mm, an average distance of 3.14 mm is acceptable but not satisfying and enough for a full restoration of muscle function even though LPMs have been preserved in a much better way. Patients need a longer period of time to completely recover from surgery and adapt to an artificial TMJ than the follow-up time we documented in this research perhaps partially account for that, for an inclination that the longer follow-up the better lateral movements were observed in our previous research for patients undergoing temporomandibular joint reconstruction with autogenous bone grafts (data not published). A change in muscle fibers direction as a result of the limited choice for fixing site and impossibility to conserve the part of LPM attached to the articular disc might also explain this. However, it is hard to make further progress based on these 2 points according to our clinical practice. Hence, we propose that an exploration for materials that could promote a direct attachment between muscles and prosthesis be of vital significance and with promising prospect.

In conclusion, our results manifest that LPM preservation is essential for function regain of mandibular lateral movement following TJR and a new method could be utilized to preserve LPM effectively, with an average moving distance of 3.14 mm (range from 2-7 mm). At the same time, this is a preliminary study from small, nonrandomized groups, and more clinical researches need to be done to provide more solid evidence.

Acknowledgements: None. All authors have viewed and agreed to the submission.

Conflict of interests: There is no conflicts of interest. All authors have viewed and agreed to the submission.

This work was supported by National Natural Science Foundation of China (81801039) and CAMS Innovation Fund for Medical Sciences (CIFMS) (2019-I2M-5-037).

References

1. Liu F, Steinkeler A. Epidemiology, diagnosis, and treatment of temporomandibular disorders. *Dent Clin North Am.* 2013; 57: 465-479.
2. Yoda T, Ogi N, Yoshitake H, Kawakami T, Takagi R, et al. Clinical guidelines for total temporomandibular joint replacement. *Jpn Dent Sci Rev.* 2020; 56: 77-83.
3. Sidebottom AJ, surgeons UTr, British Association of O, Maxillofacial S. Guidelines for the replacement of temporomandibular joints in the United Kingdom. *Br J Oral Maxillofac Surg.* 2008; 46: 146-147.
4. Hu Y, Zhang L, He D, Yang C, Chen M, et al. Simultaneous treatment of temporomandibular joint ankylosis with severe mandibular deficiency by standard TMJ prosthesis. *Sci Rep.* 2017; 7: 45271.
5. Park JH, Jo E, Cho H, Kim HJ. Temporomandibular joint reconstruction with alloplastic prosthesis: the outcomes of four cases. *Maxillofac Plast Reconstr Surg.* 2017; 39: 6.
6. Xu X, Ma H, Jin S. One-Stage Treatment of Giant Condylar Osteoma: Alloplastic Total Temporomandibular Joint Replacement Aided by Digital Templates. *J Craniofac Surg* 2018; 29: 636-639.
7. Machon V, Hirjak D, Beno M, Foltan R. Total alloplastic temporomandibular joint replacement: the Czech-Slovak initial experience. *Int J Oral Maxillofac Surg.* 2012; 41: 514-517.
8. Lotesto A, Miloro M, Mercuri LG, Sukotjo C. Status of alloplastic total temporomandibular joint replacement procedures performed by members of the American Society of Temporomandibular Joint Surgeons. *Int J Oral Maxillofac Surg* 2017; 46: 93-96.
9. Mercuri LG. Costochondral Graft Versus Total Alloplastic Joint for Temporomandibular Joint Reconstruction. *Oral Maxillofac Surg Clin North Am.* 2018; 30: 335-342.
10. Bai G, He D, Yang C, Chen M, Yuan J, et al. Application of digital templates to guide total alloplastic joint replacement surgery with biomet standard replacement system. *Journal of oral and maxillofacial surgery : official journal of the American Association of Oral and Maxillofacial Surgeons* 2014; 72: 2440-2452.
11. Pierre Cr, Yung JP, Richard MB, Marc M. Insertions of the Lateral Pterygoid Muscle: An Anatomic Study of the Human Temporomandibular Joint. *Journal of oral and maxillofacial surgery: Official journal of the American Association of Oral and Maxillofacial Surgeons.* 1988; 46: 477-482.
12. Rasse M, Kermer C, Undt G. Functional reconstruction in a case of osteoblastoma of the mandibular condyle. *Int J Oral Maxillofac Surg.* 1996; 25: 344-345.
13. Collins CP, Wilson KJ, Collins PC. Lateral pterygoid myotomy with reattachment to the condylar neck: an adjunct to restore function after total joint reconstruction. *Oral Surg Oral Med Oral Pathol Oral Radiol Endod.* 2003; 95: 672-673.