



Isolated right superior pulmonary vein fibrillation during catheter ablation in the left atrium

Marco Galeazzi^{1*}; Maurizio Russo¹; Carlo Lavalle²; Sabina Ficili³; Claudio Pandozi¹; Furio Colivicchi¹

¹Cardiology Department - San Filippo Neri Hospital, Rome, Italy

²Cardiovascular Department, Azienda Universitaria Policlinico Umberto I, Rome, Italy

³Cardiology Department, Ospedale Maggiore di Modica, ASP Ragusa, Italy

*Corresponding Author(s): Marco Galeazzi

UOC Cardiologia Clinica e Riabilitativa, Ospedale San Filippo Neri. Via Giovanni Martinotti 20 - 00135 Rome, Italy
Tel: +39-06330-622-94, Fax +39-06330-62-936
Email: m.galeazzi@lycos.com

Abstract

We performed a radiofrequency catheter ablation of atrial fibrillation by means of high-density electroanatomical mapping of the left atrium. During radiofrequency delivery into the Right Superior Pulmonary Vein (RSPV), we observed restoring of sinus rhythm. Post-ablation re-mapping of the left atrium in sinus rhythm evidenced isolated fibrillatory activity confined to the RSPV. Such finding is not common and confirms that a complete electrical isolation of this vein was obtained during the procedure.

Received: Apr 06, 2020

Accepted: May 06, 2020

Published Online: May 08, 2020

Journal: Journal of Case Reports and Medical Images

Publisher: MedDocs Publishers LLC

Online edition: <http://meddocsonline.org/>

Copyright: © Galeazzi M (2020). *This Article is distributed under the terms of Creative Commons Attribution 4.0 International License*

Keywords: Atrial fibrillation; Catheter ablation; Pulmonary veins

Introduction

A 67-year-old man (W 72 kg, H 175 cm, CHA₂DS₂-VASc = 1 due to hypertensive state) was admitted to our EP lab complaining brief and repetitive episodes of atrial fibrillation. He had previously undergone radiofrequency catheter ablation of the cavo-tricuspid isthmus because of the occurrence of common atrial flutter episodes.

Case description

High-density electrophysiological mapping of the left atrium was obtained by means of CARTO 3 software (Biosense-Webster) Confidense tool and multipolar Pentaray catheter, aiming to identify low potentials belonging to veno-atrial electrical connection areas (Figure1).

During the procedure, atrial fibrillation was accidentally induced. Radiofrequency delivery at the ostium of the Right Superior Pulmonary Vein (RSPV) was followed by restoring of persistent sinus rhythm (Figure 2).

Post-ablation high-density mapping documented the persistence of fibrillation potentials in the RSPV, despite the presence of sinus rhythm (Figure 3). Thus, a complete disconnection of this vein was confirmed. The great importance of the RSPV for the genesis and maintenance of atrial fibrillation in this patient was demonstrated as well.

Two years later the patient was found asymptomatic and in good clinical condition.

Cite this article: Galeazzi M, Russo M, Lavalle C, Ficili S, Pandozi C, Colivicchi F. Isolated right superior pulmonary vein fibrillation during catheter ablation in the left atrium. J Case Rep Med Images. 2020; 3(1): 1044.



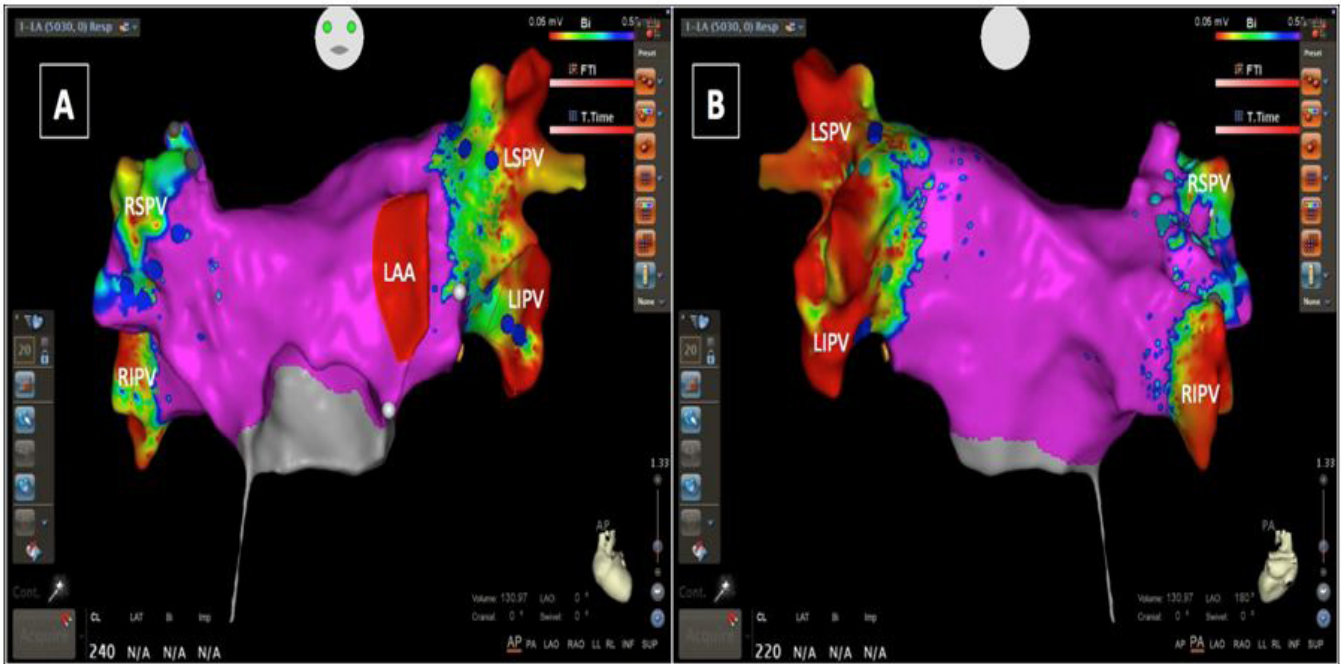


Figure 1: High-density electroanatomical CARTO mapping of the left atrium by means of Confidense tool and multipolar Pentaray catheter. Fragmented areas of low potentials are visible at the level of the pulmonary antra. Panel A: Antero-posterior view. Panel B: Postero-anterior view.

LAA: Left Atrial Appendage; LSPV: Left Superior Pulmonary Vein; LIPV: Left Inferior Pulmonary Vein; RSPV: Right Superior Pulmonary Vein; RIPV: Right Inferior Pulmonary Vein.

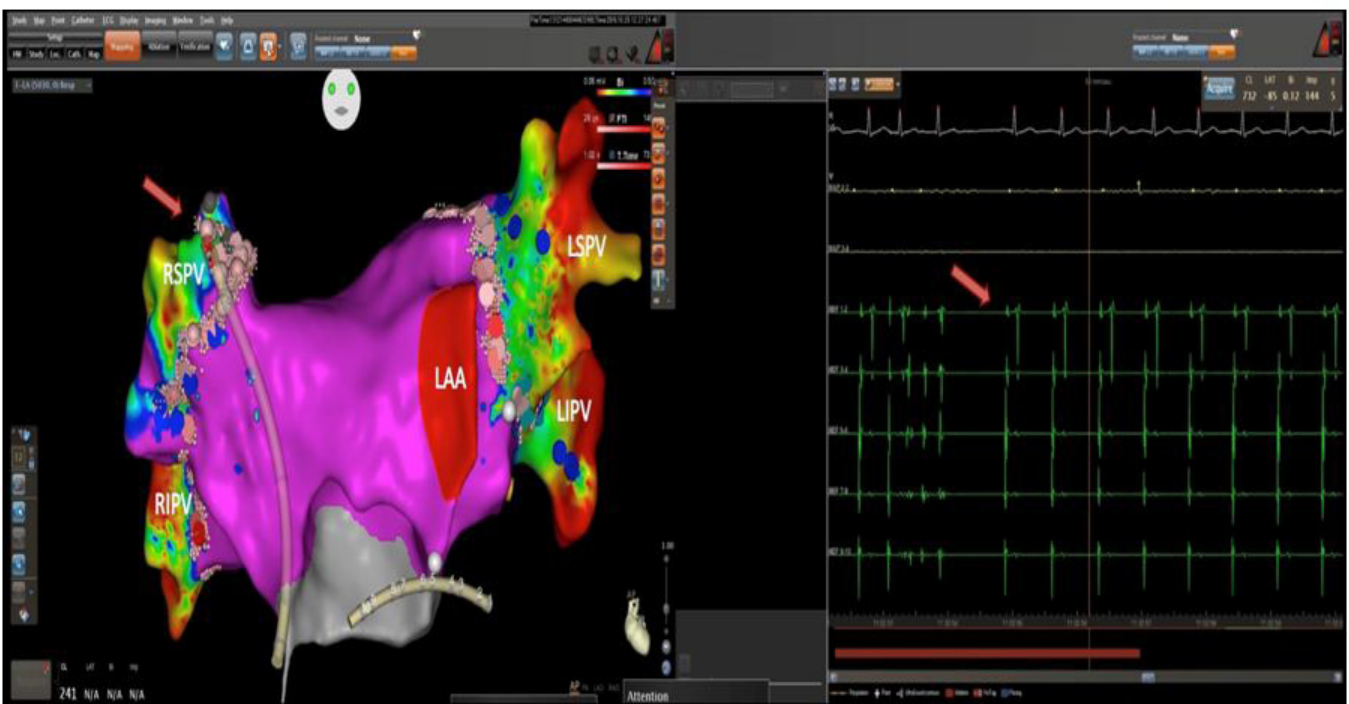


Figure 2: During ablation in the right superior pulmonary vein, atrial fibrillation was interrupted and persistent sinus rhythm was achieved. This phenomenon is visible at the level of the coronary sinus signals (green potentials, red arrow). The position of the Navistar ablation catheter in the RSPV is evidenced by a red arrow as well.

LAA: Left Atrial Appendage; LSPV: Left Superior Pulmonary Vein; LIPV: Left Inferior Pulmonary Vein; RSPV: Right Superior Pulmonary Vein; RIPV: Right Inferior Pulmonary Vein; CS: Coronary Sinus

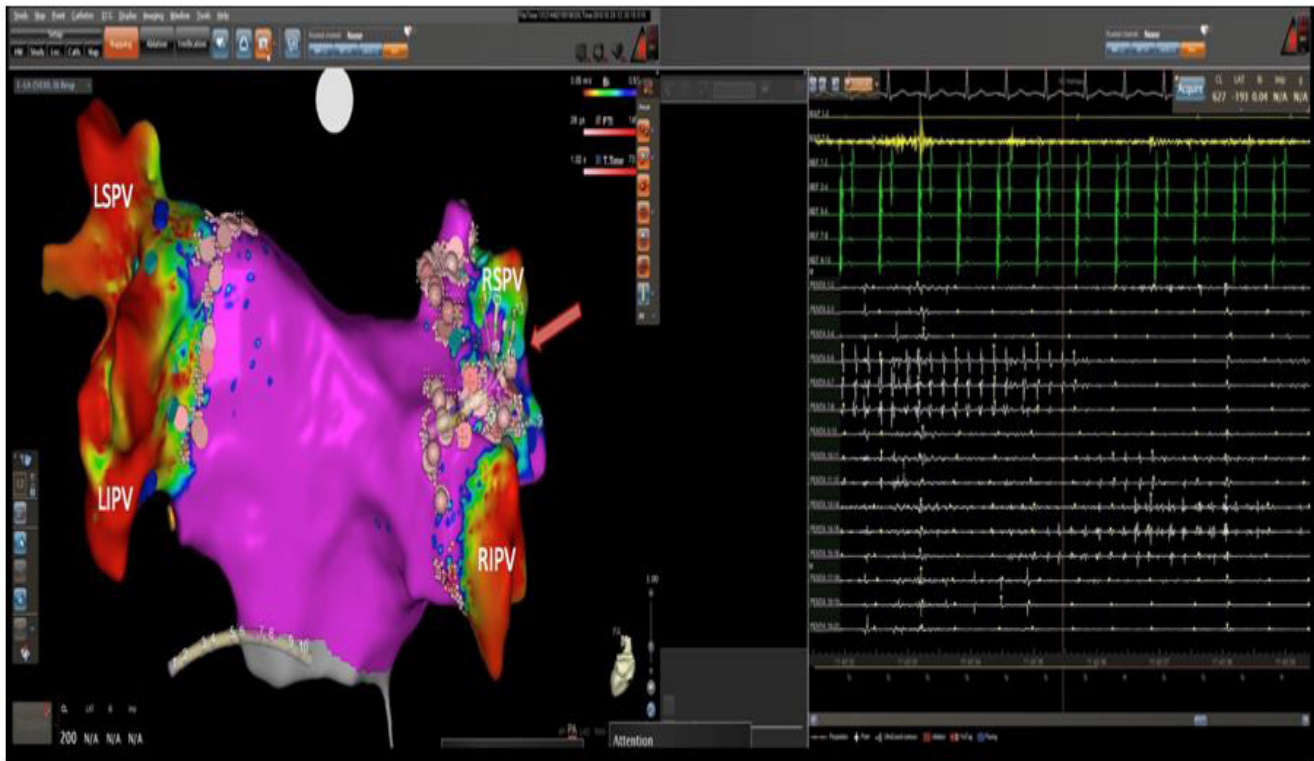


Figure 3: Post-ablation mapping of the right superior pulmonary vein with the multipolar Pentaray catheter (white potentials, red arrow) shows the persistence of fibrillation potentials inside the vein together with the presence of sinus rhythm at the level of the coronary sinus leads (green potentials).

LSPV: Left Superior Pulmonary Vein; LIPV: Left Inferior Pulmonary Vein; RSPV: Right Superior Pulmonary Vein; RIPV: Right Inferior Pulmonary Vein; CS: Coronary Sinus.

Conclusion

Since the main goal of atrial fibrillation ablation consists of achieving a complete electrical disconnection of the pulmonary veins [1-4], the observation of an isolated fibrillatory activity in the RSPV, which was not spread to the rest of the left atrium, confirmed the efficacy of the procedure and was associated to a favorable outcome. To the best of our knowledge no previous image concerning this topic has been published so far.

References

1. Chen SA, Hsieh MH, Tai CT, Tsai CF, Prakash VS, et al. Initiation of atrial fibrillation by ectopic beats originating from the pulmonary veins: electrophysiological characteristics, pharmacological responses, and effects of radiofrequency ablation. *Circulation*. 1999; 100: 1879-86.
2. Haissaguerre M, Jais P, Shah DC, Garrigue S, Takahashi A, et al. Electrophysiological end point for catheter ablation of atrial fibrillation initiated from multiple pulmonary venous foci. *Circulation* 2000; 101: 1409-17.
3. Pappone C, Rosanio S, Oreto G, Tocchi M, Gugliotta F, et al. Circumferential radiofrequency ablation of pulmonary vein ostia: A new anatomic approach for curing atrial fibrillation. *Circulation* 2000; 102: 2619-28.
4. Sau A, Howard JP, Al-Aidarous S, Ferreira-Martins J, Al-Khayatt B, et al. Meta-analysis of randomized controlled trials of atrial fibrillation ablation with pulmonary vein isolation versus without. *J Am Coll Cardiol EP*. 2019; 5: 968-76.