



# Intrahepatic Cholestasis Following Spontaneous Subcapsular Rupture of Hepatic Hemangioma; A Case Report

\*Corresponding Author(s): **Madhushanka**

**Ekanayaka**

Department of Surgery, PGIM Colombo University,  
No. 13, Dombawela Srilanka

Tel: 717 179 286, Fax: 0717 179 286;

Email: imadhuekana@gmail.com

Received: Jul 02, 2020

Accepted: Aug 26, 2020

Published Online: Aug 28, 2020

Journal: Journal of Case Reports and Medical Images

Publisher: MedDocs Publishers LLC

Online edition: <http://meddocsonline.org/>

Copyright: © Ekanayaka M (2020). *This Article is distributed under the terms of Creative Commons Attribution 4.0 International License*

**Keywords:** Tumors; Abdominal pain; Jaundice; Hepatitis.

## Introduction

Hepatic hemangiomas are the commonest benign mesenchymal hepatic tumors. Majority of the cases are asymptomatic and do not need interventions. Few presents with wide variety of symptoms. Of these, spontaneous or traumatic rupture is rare but most dramatic complication. They may present with sudden abdominal pain, anemia and hemoperitoneum.

## Case report

A 42 years old previously healthy male presented with sudden onset Right hypochondrial pain for one week. He started becoming jaundice after 2 days of onset of abdominal pain.

His Biochemical parameters showed elevated C reactive protein of 220 u/L, total bilirubin 67 U/L, direct bilirubinemia

of 56 U/L, alanine aminotransferase 161 U/L aspartate aminotransferase of 260 U/L and alkaline phosphatase of 203 U/L. The hepatitis viral screening was negative.

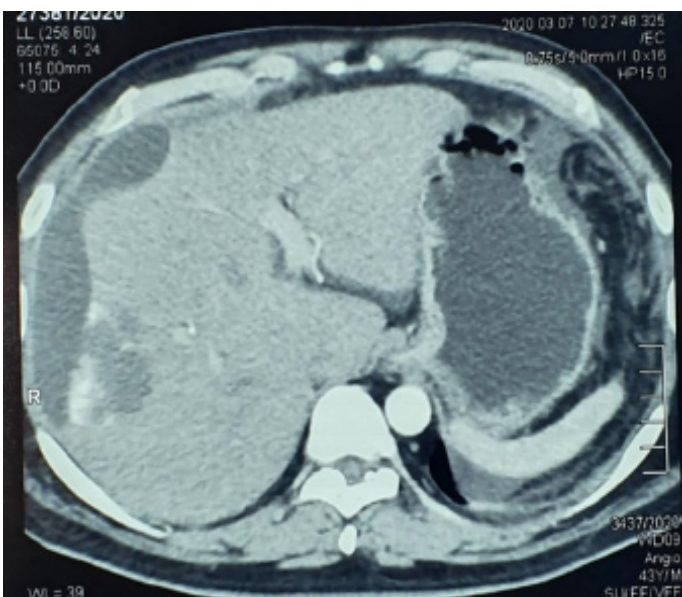
Abdominal ultrasound scan revealed focal hypoechoic lesion in segment VII with subcapsular collection. There was no intra or extra hepatic duct dilatation.

Contrast enhanced CT appearance was suggestive of ruptured hemangioma of segment VII with subcapsular hematoma. There was no intra or extra hepatic duct dilatation (Figure 1). The blunted edges and the parenchymal appearance was suggestive of pre - existing fatty liver disease.

Patients symptoms and biochemistry improved gradually with supportive care. He is being further evaluated for surgical resection.

**Cite this article:** Ekanayaka M. Intrahepatic Cholestasis Following Spontaneous Subcapsular Rupture of Hepatic Hemangioma; A case report. J Case Rep Med Images. 2020; 3(1): 1053.





**Figure 1:** Contrast enhanced CT image showing hemangioma (A) with subcapsular hematoma (B) without intrahepatic duct dilatation (C).

### Discussion

Hemangioma of liver are common benign vascular malformations of the liver. In most cases, these tumors are asymptomatic hence surgical management is limited to symptomatic cases [1]. As the size of lesions increase, so does the chance of rupture [2]. But the spontaneous rupture of these tumor are rare complication seen in less than 1-4% [3]. Occasionally can result in fatal outcomes [4]. Emergency surgery for ruptured hematoma carries higher mortality around 30% and it is limited to life threatening instances [5].

Fatty liver disease may result in intrahepatic cholestasis and is characterized by the presence of intracanalicular bile plugs. These early changes start in the zone 3 of hepatic lobules [6] and further rise of parenchymal pressure may extend the cholestasis towards the zone 2 and 1 and cause severe intrahepatic cholestasis due to central venous channel occlusion.

In this case cholestasis could be due to the parenchymal pressure effect of subcapsular hematoma, leading to mechanical or inflammatory obstruction of bile flow.

In the setting of background liver disease, secondary to Non alcoholic fatty changes and early steatohepatitis (NASH) may have aggravated the cholestasis by necroinflammation and biliary canalicular obstruction [7].

### Conclusion

In conclusion sub capsular rupture of haemangioma can lead to intrahepatic cholestasis in the presence of background chronic liver parenchymal disease.

### References

1. Wolf DC, Raghuraman UV Hepatic Hemangiomas. New York (NY): Division of Gastroenterology and Hepatobiliary Diseases, Department of Medicine, New York Medical College. 2009.
2. Ribeiro MA Jr, Pappiordanou F, Gonçalves JM, Chaib E. Spontaneous rupture of hepatic hemangiomas: A review of the literature. *World J Hepatol.* 2010; 2: 428-433.
3. Jain V, Ramachandran V, Garg R, Pal S, Gamanagatti SR, Srivastava DN. Spontaneous rupture of a giant hepatic hemangioma - sequential management with transcatheter arterial embolization and resection. *Saudi J Gastroenterol.* 2010; 16: 116-119.
4. Brouwers MA, Peeters PM, de Jong KP, Haagsma EB, Klompmaker IJ, Bijleveld CM, et al. Surgical treatment of giant hemangioma of the liver. *Br J Surg.*
5. Aiura K, Ohshima R, Matsumoto K, Ishii S, Arisawa Y, et al. Spontaneous rupture of liver hemangioma: risk factors for rupture. *J Hep Bil Pancr Surg.* 1996; 3: 308-312.
6. Brunt EM, D.G. Tiniakos Pathology of steatohepatitis *Best Pract Res Clin Gastroenterol*, 16; 2002: pp. 1087-1112.
7. Kumar V, Abbas A, Aster J. Robbins Basic Pathology. 9th ed. Elsevier Saunders. 2013.