



Giant Cell Epulis Revealing Hyperparathyroidism in a MEN Patient

Asma Zargni*, Fatma Mnif; Kawthar El Arbi; Dhoha Ben Salah; Mouna Mnif Feki; Nabila Rekik; Faten Hadj Kacem; Mohamed Abid

Department of Endocrinology, Hedi Chaker Hospital, Sfax, Tunisia.

*Corresponding Author(s): Asma Zargni

Department of Endocrinology, Hedi Chaker Hospital,
Sfax, Tunisia.

Tel: +216-54451932; Email: zargni.asma@yahoo.com

Abstract

Primary hyperparathyroidism is a frequent endocrinological disorder. Rarely, it is associated with hereditary syndromes, such as multiple endocrine neoplasia type 1. In this context, we present the case of a woman with a giant cell epulis that was found to be the initial clinical manifestation of primary hyperparathyroidism. A 31-year-old woman reported with a complaint of swelling and occasional pain in the upper-left posterior maxillary region. The diagnosis of a giant cell lesion with primary hyperparathyroidism was confirmed on the basis of radiological, biochemical, and histopathological investigative procedures. The family history of our patient led us to run a genetic study. It confirmed a MEN1 syndrome.

Received: Oct 29, 2021

Accepted: Dec 06, 2021

Published Online: Dec 09, 2021

Journal: Journal of Case Reports and Medical Images

Publisher: MedDocs Publishers LLC

Online edition: <http://meddocsonline.org/>

Copyright: © Zargni A (2021). *This Article is distributed under the terms of Creative Commons Attribution 4.0 International License*

Keywords: Giant-cell epulis; Primary hyperparathyroidism; Multiple endocrine neoplasia.

Introduction

Multiple Endocrine Neoplasia Type 1 (MEN1) is a rare autosomal dominant disease characterized by the occurrence of multiple tumors, particularly in the parathyroid glands, the pancreatic islets, the pituitary gland and the adrenal glands, as well as by neuroendocrine carcinoid tumors. This syndrome is caused by a germline mutation in the multiple endocrine neoplasia type 1 gene encoding the tumor-suppressor protein menin [1]. It is diagnosed in an individual who has either two MEN1-associated tumors or one MEN1-related tumor with a first-degree relative with MEN1 or known MEN1 mutation [2]. MEN1 generally presents with Primary Hyperparathyroidism (PHPT). However, initial presentation may vary and continued

reevaluation of etiology of symptoms is required for appropriate diagnosis. We present the case of a woman with a maxillary swelling that was found to be the first clinical manifestation of primary hyperparathyroidism associated with MEN1.

Case presentation

A 31-year-old woman was admitted to our department of Endocrinology in March 2012 for left maxillary swelling. Her two siblings (a brother and a sister) were diagnosed with MEN1. She was single and had no particular personal medical history. For the past three months, she had noticed a painless swelling affecting the upper left gums, in the premolar and molar region. In addition, she described a visual blur, headaches and amenorrhea for the last year.

Cite this article: Zargni A, Mnif F, El Arbi K, Ben Salah D, Feki MM, et al. Giant Cell Epulis Revealing Hyperparathyroidism in a MEN Patient. J Case Rep Clin Images. 2021; 4(2): 1088.



Magnetic Resonance Imaging (MRI), both facial and cerebral, revealed a left maxillary expansive process of 4.5 cm, infiltrating teeth 22, 23 and 24, extended to the hard palate (Figure 1a) and a well-defined heterogeneous intra and suprasellar expansive process in T1 and T2 isosignal enhancing heterogeneously after gadolinium injection measuring 34 * 25 * 21 mm from the major axis with partial necrotic and hemorrhagic transformation of a pituitary adenoma (Figure 1b). This process fills the optochiasmatic cistern, pushes up the chiasma and comes into contact with the anterior cerebral arteries. This mass was consistent with a pituitary macroadenoma with partial apoplexy.

Intraoral examination revealed the presence of a single, ovoid, lobulated swelling in the upper-left posterior region extending anteriorly up to the first premolar, posteriorly involving the maxillary tuberosity. Borders of the swelling were well defined, and the swelling distended the cheek outward but did not involve it (Figure 2a). The biopsy of the maxillary tumor resulted in a giant-cell epulis.

The diagnosis of a macroprolactinoma was confirmed with an initial prolactinemia at 1544 ng/ml (NR: 1.3-25 µg/mL) and after eliminating a mixed secretion including GH (the glucose braking test was normal: Nadir GH = 0.02 ng /ml), IGF1 = non performed).

This macroprolactinoma was complicated by hypopituitarism. The patient was put on 20 mg/day of hydrocortisone and levothyroxine 100 µg/day.

The assessment of phosphocalcic status showed hypercalcemia at 2.77 mmol/L, hypophosphoremia at 0.7 mmol/L and hypercalciuria at 10 mmol/24h. The hormonal workup showed a high parathyroid hormone level of 395 pg/mL (N: 15-56 pg/mL). Ultrasound and Methoxyisobutylindonitrile (MIBI) scintigraphy (Figure 1c) showed three parathyroid adenomas (2 lower right and one lower left). The diagnosis of PHPT was made. It was complicated by osteoporosis (Zscore= -2.7 AB), the giant cell epulis and two renal lithiasis.

The diagnosis of Multiple Endocrine Neoplasia (NEM1) with PHPT and macroprolactinoma was confirmed by a genetic study.

The patient underwent subtotal parathyroidectomy in June 2012. The pathological study concluded to hyperplasia of the parathyroid glands. The surgery was complicated on day 4 by hypocalcemia related to Hungry Bone Syndrome (Ca = 1.96 mmol/l, PTH = 106 pg/ml) requiring a calcium and vitamin D treatment. The clinical course was marked by the total regression of the maxillary tumor after parathyroidectomy (Figure 2b).

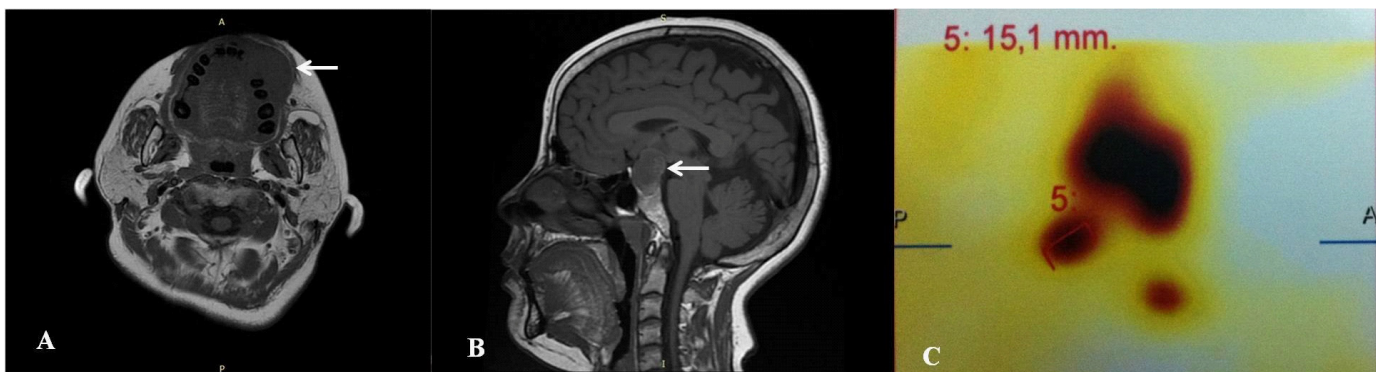


Figure 1: (a) MRI of the facial fundus in axial section: left maxillary expansive process; (b) Cerebral MRI in coronal section: pituitary macroadenoma; (c) Methoxyisobutylindonitrile scintigraphy: parathyroid adenomas.

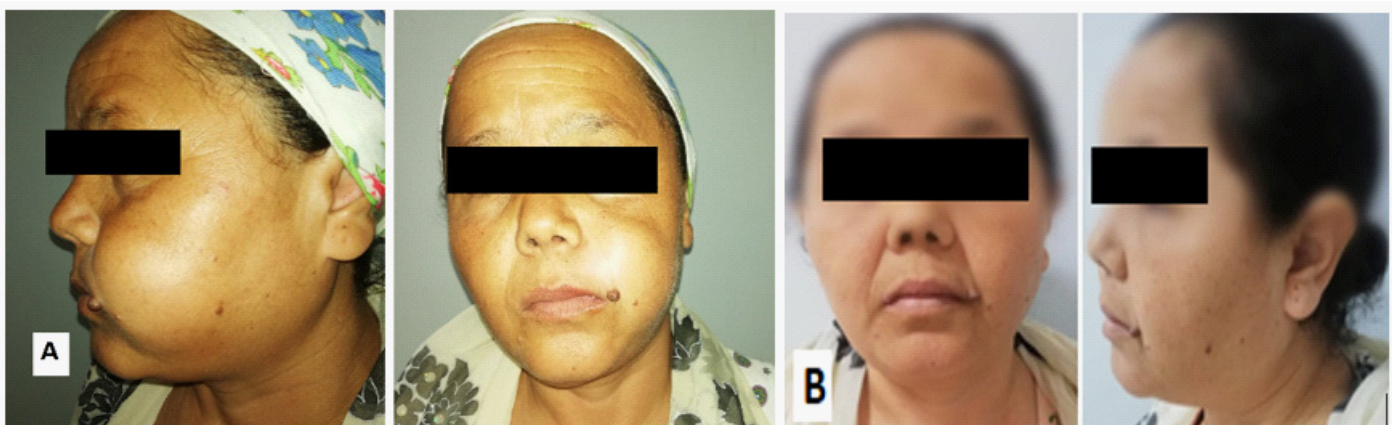


Figure 2: (A) View of the face exhibits asymmetry in the cheek region; (B) View of the face after parathyroidectomy showing total regression.

Discussion

PHPT in MEN1 is the most common endocrinopathy. It represents 2-4% of all forms of PHPT. It is among the first endocrine manifestation in MEN1 patients. All individuals are affected by the age of 50 [3]. In fact, the occurrence of hyperparathyroidism at a young age, supported by family history, and the association with other typical endocrinopathies of MEN1 syndrome [4], as in our patient's case, carries a high suspicion of MEN1 syndrome.

In the present case, an oral lesion was the first manifestation of PHPT. The diagnosis was delayed although there was initially obvious indication of this endocrine disorder. An oral giant cell lesion, the so-called epulis, is one of the features of hyperparathyroidism [5,6].

The epulis is a benign, circumscribed, gingival pseudotumor located at the marginal gingiva of a tooth or two contiguous teeth [7]. It often follows chronic local irritation or hormonal disturbances. It usually occurs in newborns [8] and women during periods of genital activity. Histological examination confirms the diagnosis. This pseudotumor has no degenerative potential. It is exceptionally indicative of PHPT [9,10]. It is often secondary to tumor extension from a central gigantocellular granuloma.

This lesion is caused by increased circulating levels of parathyroid hormone, resulting in increased osteoclastic bone resorption, primarily in cortical bone [11].

Its maxillary localization during this endocrinopathy could be explained by the accelerated bone remodeling of the maxillary bones incessantly stimulated by the masticatory forces. In extreme cases, the radiological density of the dental dentin is increased and the tooth roots can be resorbed. The histological findings in bony lesions of hyperparathyroidism are not pathognomonic, requiring differentiation from central or peripheral giant cell granulomas, fibrous dysplasia, and cherubism [12]. The histological presentation of central giant cell granuloma is identical to brown tumor of hyperparathyroidism. These usually regress after surgical excision of the parathyroid lesions involved. Our case emphasizes the fact that it is mandatory to test for hyperparathyroidism in all histologically proven giant cell lesions of the jaw [13]. Regarding the management of PHPT, surgery is the recommended treatment as it improves bone mineral density, reduces the risk of fractures and kidney stones.

Conclusion

Primary hyperparathyroidism is a frequent endocrinological disorder. Rarely, it is associated with hereditary syndromes, such as multiple endocrine neoplasia type 1. In this case, we emphasize on the importance to test for hyperparathyroidism in giant cell epulis that was found to be the initial clinical manifestation of primary hyperparathyroidism.

References

1. Al-Salameh A, Baudry C, Cohen R. Update on multiple endocrine neoplasia Type 1 and 2. *Presse Médicale*. 2018; 47: 722-731.
2. Thakker RV, Newey PJ, Walls GV, Bilezikian J, Dralle H, Ebeling PR, et al. Clinical practice guidelines for multiple endocrine neoplasia type 1 (MEN1). *J Clin Endocrinol Metab*. 2012; 97: 2990-3011.
3. Falchetti A, Marini F, Luzi E, Giusti F, Cavalli L, Cavalli T, et al. Multiple endocrine neoplasia type 1 (MEN1): not only inherited endocrine tumors. *Genet Med Off J Am Coll Med Genet*. 2009; 11: 825-835.
4. Falchetti A, Marini F, Giusti F, Cavalli L, Cavalli T, Brandi ML. DNA-based test: when and why to apply it to primary hyperparathyroidism clinical phenotypes. *J Intern Med*. 2009; 266: 69-83.
5. Zhang W, Chen Y, An Z, Geng N, Bao D. Reactive gingival lesions: a retrospective study of 2,439 cases. *Quintessence Int*. 2007; 38: 103-110.
6. Almeida JD. Achados clínicos e radiográficos das doenças endócrinas de interesse estomatológico. 1995.
7. Fonseca GM, Fonseca RM, Cantín M. Massive fibrous epulis-a case report of a 10-year-old lesion. *Int J Oral Sci*. 2014; 6: 182-184.
8. Diniz MB, Elisa MG, Angela CZ, Costa CA, Hebling J. Congenital epulis: a rare benign tumor in the newborn. *J Indian Soc Pedod Prev Dent*. 2010; 28: 230- 233.
9. Coen G. Primary hyperparathyroidism beginning with a giant cell epulis. *Folia Endocrinol*. 1965; 18: 371.
10. Parbatani R, Tinsley GF, Danford MH. Primary hyperparathyroidism presenting as a giant-cell epulis. *Oral Surg Oral Med Oral Pathol Oral Radiol Endodontology*. 1998; 85: 282-284.
11. Neville BW, Damm DD, Allen CM, Chi AC. *Oral and maxillofacial pathology*. Elsevier Health Sciences. 2015.
12. Potter BJ, Tiner BD. Central giant cell granuloma: report of a case. *Oral Surg Oral Med Oral Pathol*. 1993; 75: 286-289.
13. Aghaghazvini L, Sharifian H, Rasuli B. Primary hyperparathyroidism misdiagnosed as giant cell bone tumor of maxillary sinus: a case report. *Iran J Radiol*. 2016; 13: e13260.