



# Giant Aortic Aneurysm: An Asymptomatic and Exuberant Presentation

Rui Seixas\*; Sofia Sobral; Henrique Rita

Internal Medicine Department, Litoral Alentejano Local Health Unit, Santiago do Cacém, Portugal.

**\*Corresponding Author(s): Rui Seixas**

Internal Medicine Department, Litoral Alentejano Local Health Unit, Santiago do Cacém, Rua de Santa Catarina, lot 3, 3rd left 7520-265 Sines, Portugal.

Tel: +351-915421111; Email: ruipmseixas@gmail.com

Received: Oct 29, 2021

Accepted: Dec 06, 2021

Published Online: Dec 09, 2021

Journal: Journal of Case Reports and Medical Images

Publisher: MedDocs Publishers LLC

Online edition: <http://meddocsonline.org/>

Copyright: © Seixas R (2021). *This Article is distributed under the terms of Creative Commons Attribution 4.0 International License*

**Keywords:** Giant aortic aneurysm; Aneurismatic dilation; Vascular malformation.

## Clinical image description

The giant aortic aneurysm, defined as aortic dilatation with a maximum diameter greater than 10 cm [1], is the most frequent subtype of aortic aneurysm. However, its incidence is low and rarely described in the literature being a generally asymptomatic pathology and incidentally discovered in routine imaging exams as presented in this patient. Physicians should be alerted to this pathology since its cause varies and may occur in the context of atherosclerotic degeneration, Marfan syndrome, aortic valve disease or autoimmune syndromes such as Takayasu's arteritis [2]. Its risk of rupture will depend on its size and annual growth [3]. The approach and its treatment vary depending on the affected arterial segment and the underlying etiology. The authors present a case of a 96-year-old, autonomous woman

with a history of chronic kidney disease secondary to arterial hypertension and osteoporosis, without a record of therapy and without knowledge of blood pressure control. Admitted to the Emergency Department due to dyspnea and asthenia with four weeks of progressive worsening and tolerating only minor efforts. On objective examination, he only presented decreased breath sounds in the left hemithorax, without the presence of adventitious sounds. A chest X-ray showed exuberant hypotransparency in a towel in the left hemithorax (Figure 1). In-depth imaging study with chest tomography revealed massive ascending aortic aneurysmal dilatation with molding of the left subclavian artery and tracheal deviation measuring 100 x 75 x 113 mm (Figure 2). Given the patient's age and chronic kidney disease, an etiological study was not pursued, namely chest tomography with contrast injection or invasive surgical therapy.

**Cite this article:** Seixas R, Sobral S, Rita H. Giant Aortic Aneurysm: An Asymptomatic and Exuberant Presentation. J Case Rep Med Images. 2021; 4 (2): 1087.



Medical therapy was optimized with good symptomatic response, so she was discharged from the hospital and continued follow-up in consultation of Internal Medicine.

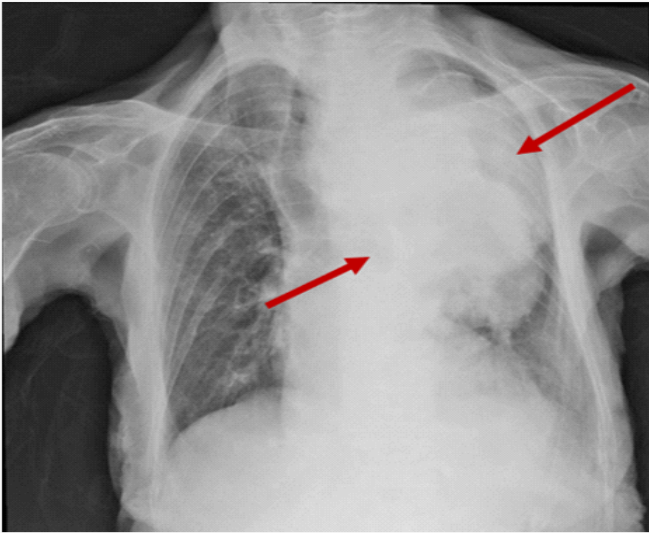


Figure 1

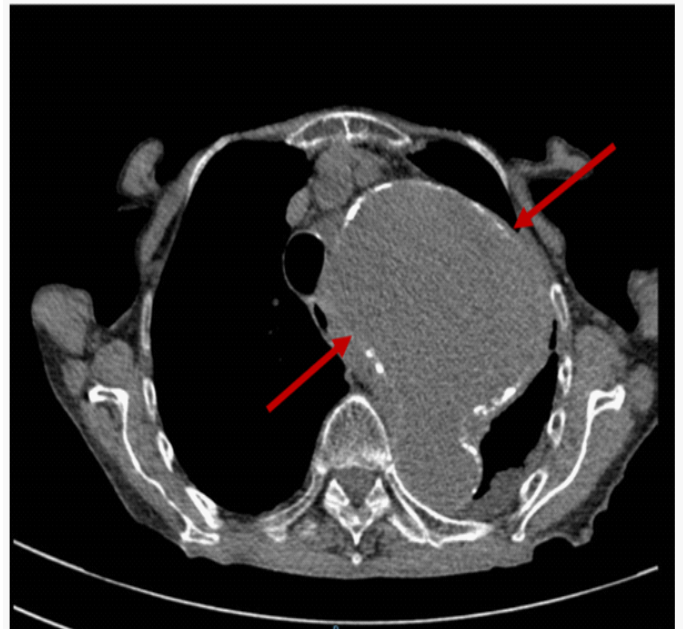


Figure 2

### References

1. V Agarwal, C Yaliwal, E Ofo, S Kolvekar. Giant ascending aortic aneurysm-a case report and review. *Heart Lung and Circulation*. 2007; 16: 385-388.
2. T Okura, Y Kitami, Y Takata, T Fukuoka, J Arimitsu, K Hiwada. Giant unruptured aneurysm of the thoracic aorta: a case report. *Angiology*.1999; 50: 865-869.
3. Isselbacher EM. Thoracic and abdominal aortic aneurysms. *Circulation*. 2005; 111: 816-828.