



# Exophthalmia grade III unilateral secondary to a mucocele ethmoido-frontal

Seydou Diallo<sup>1</sup>; Rodrigue R Elien GY<sup>1</sup>; Jean M Mbaikoua<sup>2</sup>; Japhet P Thera<sup>1</sup>

<sup>1</sup>Institute of African Tropical Ophthalmology, Bamako, Mali

<sup>2</sup>National University Hospital Center of Bangui, Bangui, Central Africa Republic

**\*Corresponding Author(s): Seydou DIALLO**

**& Rodrigue R ELIEN GY**

Institute of African Tropical Ophthalmology, Bamako, Mali  
& National University Hospital Center of Bangui, Bangui,  
Central Africa Republic

Tel: 00223-7646-6147; Email: vcmenezes@hotmail.com &  
rodrigueelien@yahoo.fr

Received: Oct 18, 2019

Accepted: Dec 12, 2019

Published Online: Dec 14, 2019

Journal: Journal of Case Reports and Medical Images

Publisher: MedDocs Publishers LLC

Online edition: <http://meddocsonline.org/>

Copyright: © Diallo S & Elien GYRR (2019). *This Article is distributed under the terms of Creative Commons Attribution 4.0 International License*

**Keywords:** Unilateral exophthalmia; Mucocele ethmoido-frontal; Adult mali

## Clinical Image

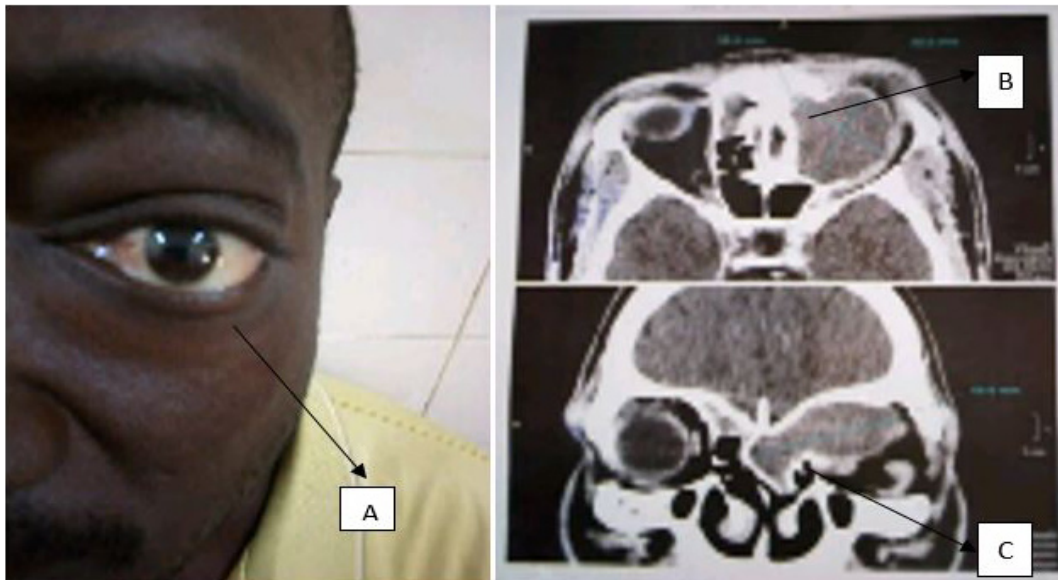
Mucoceles are benign, pseudo-cystic, expansive tumors, due to an accumulation of mucus in a cavity whose orifice is obstructed. This accumulation may occur in the tear sac or sinus. Mucocele can be maxillary, sphenoidal, ethmoidal, frontal and ethmoido-frontal. Mucocele rarely occurs before adolescence. Osteal obstruction and chronic inflammation are the 2 most commonly accepted factors in the genesis of mucoceles. Nevertheless, it would appear that an over-added infection may

precipitate the formation of mucocele. We report the case of a 37-year-old patient with no specific history, who has a unilateral left-sided Grade III exophthalmia secondary to ethmoido-frontal mucocele. The ophthalmological examination was found in both eyes: visual acuity without correction of 10/10. The external eye examination at the level of the left eye showed: a non-pulsatile, axial, reducible exophthalmia (Figure: 1A) and a limitation of ocular mobility in the different positions of the eye, the



**Cite this article:** Diallo S, Elien GYRR, Mbaikoua JM, Thera JP. Exophthalmia grade III unilateral secondary to a mucocele ethmoido-frontal. J Case Rep Clin Images. 2019; 2(1): 1031.

anterior segment and the fundus were normal. The intraocular pressure measured at the Goldman tonometer was 12 millimetres of mercury in the right eye and 16 millimetres of mercury in the left eye. The examination of the right eye was uncommon. Orbito-cerebral computed tomography finds a Grade III exophthalmate on the left secondary to an intra-orbital extension of a left supra-orbital ethmoidal cell mucocele, associated total obstruction and ostial blockage of the frontal sinuses (Figure: 1B, C). The patient was referred to otolaryngologists for surgical management of mucocele. The follow-up procedures were favourable without recurrence.



**Figure 1:** (A) exophthalmia grade III (B, C) intra-orbital extension of a left supra-orbital ethmoidal cell mucocele, associated with total obstruction and osteal blockage of the frontal sinuses.