



Enhanced Recovery: A Reality in Cancer and Pregnancy: A Case Report

Sindhu Sankaran¹; Amrithavarshini Ragavan¹; Pradeep Chirravur²; Meera VV Ragavan^{3*}; N Ragavan⁴

¹Department of Urology, Apollo Hospitals, 21, Greams Lane, Off Greams Road, Chennai, India.

²Department of Anesthesiology, Apollo Hospitals, 21, Greams Lane, Off Greams Road, Chennai, India.

³Obstetrics and Gynaecology, DNB-Obstetrics and Gynecology, MRCOG(UK), Consultant Urogynecologist, Department Of Obstetrics And Gynecology, Apollo Hospitals, 21, Greams Lane, Off Greams Road, Chennai, India.

⁴Consultant Uro-Oncologist, Department Of Urology and Uro-Oncology, Apollo Hospitals, 21, Greams Lane, Off Greams Road, Chennai, India.

***Corresponding Author(s): Meera VV Ragavan**

Apollo Hospitals, 21, Greams lane, Off Greams Road,
600006, Chennai, India.

Tel: +91-9488648574; Email: dr.meeraragavan@gmail.com

Abstract

Background: Renal malignancies in pregnancy are rare occurrences with a little over 100 cases described in literature. It is usually diagnosed and managed in the first trimester but we present the management of a third trimester pregnancy with renal mass

Case Presentation: A 27-year-old primigravida presented with a left sided intermittent pain at 32 weeks of pregnancy that on an ANC ultrasound revealed a renal mass. Diagnosis was through included a MRI for pre surgical planning Management included a MRI for pre surgical planning followed by a two staged simultaneous LSCS under spinal anesthesia and robotic left radical nephrectomy under general anesthesia.

Conclusion: Management of renal malignancies in pregnancy requires careful choice of diagnostic modalities, multidisciplinary decision-making and careful surgical and anesthetic planning to give best maternal and foetal outcomes.

Received: Dec 20, 2021

Accepted: Feb 15, 2022

Published Online: Feb 18, 2022

Journal: Journal of Case Reports and Medical Images

Publisher: MedDocs Publishers LLC

Online edition: <http://meddocsonline.org/>

Copyright: © Ragavan MVV (2022). *This Article is distributed under the terms of Creative Commons Attribution 4.0 International License*

Keywords: Renal cell cancer; Pregnancy; Pregnancy; Robotic nephrectomy; Regional anesthesia.

Abbreviations: MRI: Magnetic Resonance imaging; EAU: European Association of Urology; LSCS: Lower Section Caesarean Section; POD: Post-Operative Day.

Cite this article: Sankaran S, Ragavan A, Chirravur P, Ragavan MVV, Ragavan N. Enhanced Recovery: A Reality in Cancer and Pregnancy: A Case Report. J Case Rep Clin Images. 2022; 5(1): 1103.



Background

Renal malignancies diagnosed during pregnancy are rare occurrences with only about 100 cases described in literature so far [1-2]. The most common histological subtype is adenocarcinoma-clear cell carcinoma, with a small percentage taken up by chromophobe, nephroblastoma, angiosarcoma etc., [2]. It is usually an incidental finding during routine antenatal imaging. In some cases, advanced tumors may present with palpable mass, pain or hematuria [3]. The diagnostic work-up for a renal mass including basic blood work, sonography and an MRI instead of contrast CT scan as recommended by EAU guidelines [4].

Small renal masses can undergo surveillance, but larger masses need surgical intervention. Management requires multidisciplinary approach with careful consideration of possible consequences to mother and child. We report the case of 27-year-old primigravida presenting with a renal mass in third trimester of pregnancy.

Case presentation

A 27-year-old primigravida presented at third trimester of gestation with intermittent abdominal pain. Ultrasound scan at 32 weeks of gestation revealed a large ill-defined heterogeneous mass in the left kidney, which was confirmed by an MRI scan as a 13 cm left renal tumour highly suspicious for renal cell carcinoma (Figure 1).

The clinical situation was discussed in multidisciplinary team and with the patient about the various treatment options. In view of advanced pregnancy, it was decided to perform a concomitant cesarean section and radical nephrectomy at 35 weeks

The surgery was performed in two steps. Under spinal anesthesia and supine position, lower segment cesarean section was performed with a pfannenstiel incision. Healthy male child was delivered and was transferred to NICU for short observation. After delivering the placenta and securing the uterus, a single robotic trocar was placed under vision just supero-medial aspect of the left Anterior superior iliac spine. Airtight skin closure was done.

The patient was then given a general anesthesia. The robotic trocar was kept in a sterile condition and the patient was moved to kidney position. The operative area was cleaned and re-draped. The existing robotic trocar was utilized to secure other ports. Robot assisted radical nephrectomy and node dissection. The renal vasculature was secured with hemolok clips. Highly engorged vessels were found in the perinephric and retroperitoneal spaces (perhaps related to pregnancy) and these were secured using hemolock clips and bipolar energy. After the completion of nephrectomy, the cesarean section wound was opened, specimen delivered and abdomen was closed in layers.

The total operative time was 3 hours with robotic dock time of 1hour 20 minutes. Patient recovery was uneventful.

Histopathological analysis revealed a grade 3 epithelial origin renal neoplasm suggestive of pT3aNx clear cell RCC with clear margins. The gross specimen was 17*14*8 cm in dimensions with capsule intact. Genetic workup for VHL and fumarate hydratase gene mutations was offered owing to the young age of the patient.

Follow up consultation USG scan at 3 months and CT scan at 6 months were normal. Both mother and baby are doing well.

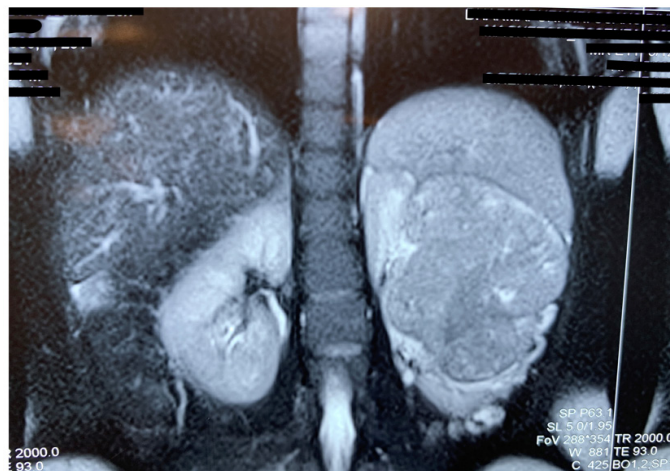


Figure 1: MRI image showing renal mass and singleton live in-traiterine pregnancy of 34 weeks.

Discussion

Newly diagnosed malignancies occur in about 0.07-0.1% of all pregnancies [5]. Potentially malignant renal masses are extremely rare and renal cell carcinoma is the most common amongst them [6]. In 2015, Khaled et al., reported 106 cases of RCC in pregnancy described in literature with common presenting symptoms of flank pain, hematuria and hypertension. He also describes most cases to be incidental findings as part of routine ANC ultrasonography [5]. Our patient despite undertaking routine ANC, presented only in the third trimester with flank pain owing to the large size of the mass.

Diagnostic evaluation of pregnant women with renal masses requires special consideration of non-invasive techniques and minimal radiation exposure to mother and foetus. MRI can adequately identify, differentiate between, and stage solid renal masses in most cases, and with the avoidance of radiation exposure to the foetus, this is the imaging of choice [4].

The challenge of managing RCC in pregnancy lies in the operative difficulty and potential anaesthetic and surgical complication to the baby. Recommendations regarding the timing of surgery depend on the gestational age, the size of the mass and probability of survival of foetus [7,8]. Any surgery performed in first and third trimester is associated with a higher risk of spontaneous abortion and pre-term labour respectively. Third trimester malignancies can be either left alone until after delivery or synchronous surgery to prevent miscarriage. In contrast to small renal masses (usually a maximum of 4 cm in diameter), studies showed a positive correlation of tumour diameter with meta-static spread. Every additional centimetre of tumour diameter added an additional risk of 25% for distant metastasis [9]. Thus, while smaller tumours can go into active surveillance, larger ones need early intervention. Considering the extremely large size of the mass, potential metastatic spread and mechanical impact on the foetus, surgery with multidisciplinary involvement was planned.

The surgical intervention needs to be timed after ensuring adequate growth and lung maturity of the foetus but at the same time ensuring a radical nephrectomy for the mother at the earliest available and safe opportunity, preferably within a month of the diagnosis.

The authors felt that performing a caesarean under spinal was more physiological and allowed the mother to see and feel the baby before going into general anaesthesia for nephrectomy.

Securing a single robotic trocar under vision before closure of the abdomen after caesarean, allowed quick progress into the second step of the operation.

The advantage of robot assisted surgery include reduced post-operative morbidity, decreased pain, and postoperative analgesic requirements, rapid postoperative mobilization, and decreased maternal hypoventilation and wound complications, all of which have positive impact on foetal well-being. This advantage can be clearly seen herewith, where mobilization and soft diet intake was achieved on POD1 and both mother and child were safely discharged on POD2.

Conclusion

This case report is being written to understand the importance of right diagnostic modalities, multidisciplinary decision making and careful surgical planning and anaesthetic planning with regards to use of spinal anaesthesia for safety of the foetus. The approach of simultaneous LSCS and radical nephrectomy in case of adequate foetal lung maturity, use of robot assisted laparoscopy and provision for intensive neonatal care in a tertiary level set-up and the choice of anaesthetic care can give best maternal and foetal outcomes.

Informed Consent

Written informed consent has been obtained to publish this case from the patient.

Ethical Approval

Ethical approval is not required at our institution to publish an anonymous case report.

References

1. Mancuso A, Macrì A, Palmara V, et al. Chromophobe renal cell carcinoma in pregnancy: Case report and review of the literature. *Acta Obstet Gynecol Scand.* 2001; 80: 967-969.
2. Boussios S. Renal cell carcinoma in pregnancy: A rare coexistence. *Clin Transl Oncol.* 2014; 16: 122-127
3. Crotty TB, Farrow GM, Lieber MM. Chromophobe cell renal carcinoma: Clinicopathological features of 50 cases. *J Urol.* 1995; 154: 964-967.
4. Ljungberg B, Albiges L, Bensalah K, Bex A, Capitanio U, et al. Guidelines on renal cell carcinoma EAU. *Eur Assoc Urol Updat.* 2017.
5. Khaled H, Lahloubi NA, Rashad N. Review on renal cell carcinoma and pregnancy: A challenging situation. *J Adv Res.* 2016; 7: 575-580.
6. Loughlin KR. The management of urological malignancies during pregnancy. *Br J Urol.* 1995; 76: 639-644.
7. Shim MH, Mok CW, Chang KH, Sung JH, Choi SJ. Clinical characteristics and outcome of cancer diagnosed during pregnancy. *Obstet Gynecol Sci,* 2016; 59: 1-8.
8. Yin L, Zhang D, Teng J, Xu D. Retroperitoneal laparoscopic radical nephrectomy for renal cell carcinoma during pregnancy. *Urol Int.* 2013; 90: 487-489.
9. Bettez M, Carmel M, Temmar R, Cote AM, Sauve N, et al. Fatal fast-growing renal cell carcinoma during pregnancy. *J Obstet Gynaecol Can.* 2011; 33: 258-261.