



Disease Progression after Discontinuation of Lenvatinib in a Patient with Known Thyroid Cancer, Pleural Metastasis, and COVID-19

Nawar Hasan^{1*}; Heerani Woodun²; Omar Ahmad³; Nicolae Culis⁴; Abigail Pascoe⁵

¹Department of Radiology, (Trust Grade CT1), Nottingham University Hospitals, Nottingham, UK.

²Surgical Trainee at Nottingham University Hospitals NHS Trust, England, UK.

³Medical Doctor-Geriatric Medicine at NHS Nottingham, England, UK.

⁴Department of Radiology, (FY2), Nottingham University Hospitals, Nottingham, UK.

⁵Oncologist, Nottingham University Hospitals NHS Trust, England, UK.

*Corresponding Author(s): Nawar Hasan

Department of Radiology, Nottingham University Hospitals, Hucknall road Nottingham NG51PB, UK.
 Tel: +447385890824; Email: nawaaralkaabi@gmail.com

Abstract

A 77-year-old female, with background of refractory metastatic papillary thyroid cancer after a 2-stage thyroidectomy in 2016 and radioactive iodine ablation, presented with dyspnea and chest pain. She was COVID-19 positive. Computed tomography of thorax demonstrated marked progression in pleural soft tissue metastasis with pleural thickening and a large pleural effusion. She required chest drainage. She was on immunotherapy with Lenvatinib, a multi-tyrosine kinase inhibitor, which was discontinued 5 days ago due to her reduced performance status and adverse effects. Disease hyperprogression due to discontinuing Lenvatinib was suspected. She improved, recommenced Lenvatinib at a lower dose and had a good clinical response. Awareness of the flare-up phenomenon on withdrawal of Lenvatinib is important, especially in patients with pleural disease or effusions. This case also illustrates the successful treatment of COVID-19 in a metastatic thyroid cancer patient who had recently received and stopped Lenvatinib, with subsequent recovery to enable reinstatement of Lenvatinib.

Received: Oct 17, 2022

Accepted: Nov 02, 2022

Published Online: Nov 04, 2022

Journal: Journal of Case Reports and Medical Images

Publisher: MedDocs Publishers LLC

Online edition: <http://meddocsonline.org/>

Copyright: © Hasan N (2022). *This Article is distributed under the terms of Creative Commons Attribution 4.0 International License*

Keywords: Papillary thyroid cancer; Lenvatinib; Tyrosine kinase inhibitor; Pleural metastasis; Covid-19.

Introduction

Thyroid cancer is estimated to have a worldwide incidence of approximately 567 000 cases [1] and Differentiated Thyroid Cancer (DTC) makes up about 95% of these cases [2]. DTC is typically associated with a good prognosis, and approximately 85% of patients are cured following some combination of surgery, radioiodine therapy, and thyroid-stimulating hormone suppression [3]. However, the remaining patients with Radioiodine Refractory (RR)-DTC have a 5-year survival rate of as low as 10% [3]. Lenvatinib, a multi-tyrosine kinase inhibitor, was approved

for the treatment of patients with locally recurrent or metastatic progressive RR-DTC based on the global Phase 3 SELECT study. The median progression-free survival was 14.7 months longer than it was among those who received a placebo [4]. The efficacy of Lenvatinib was also confirmed in patients with poorly differentiated cancer [5]. In some patients, fast disease progression after TKI discontinuation was noted, which was called the flare-up phenomenon [6]. We report a case of rapid development of pleural effusion after discontinuation of Lenvatinib with concurrent covid-19 infection in a patient with metastatic papillary thyroid cancer after primary resection in 2016.



Cite this article: Hasan N, Woodun H, Ahmad O, Culis N, Pascoe A. Disease Progression after Discontinuation of Lenvatinib in a Patient with Known Thyroid Cancer, Pleural Metastasis, and COVID-19. J Case Rep Clin Images. 2022; 5(2): 1118.

Case presentation

A 77-year-old female, with background of metastatic papillary thyroid cancer, underwent a 2-stage thyroidectomy at Stage pT2, pNx, R0, followed by radioactive iodine ablation in 2016. She had an initial excellent response to treatment on dynamic risk stratification in 2017, but then had a biochemical relapse in 2020, and Computed Tomography (CT) scan in January 2021 showed multiple small lung metastases. She underwent a therapy dose of radioiodine in April 2021, which did not show any uptake of I131. Thyroglobulin continued to gradually rise with progressive lung and pleural nodules. She was started on Lenvatinib 24 mg once daily in June 2022. She developed pleuritic chest pain shortly after starting Lenvatinib, and CT-Pulmonary Angiogram (CTPA) ruled out pulmonary embolus but showed progression of pleural metastases as the potential cause of pain. She required opiate analgesia, and Lenvatinib was continued. However, she became extremely fatigued and weak with reduced mobility and declining performance status, and Lenvatinib was suspended to optimize analgesia and consider restarting at a lower dose.

Five days later, she was admitted with shortness of breath, right-sided pleuritic chest pain and new oxygen requirements of 40%. Initial investigations revealed white cell count (WCC) of $10.4 \times 10^9/L$, C-Reactive Protein (CRP) of 147 mg/L, a diagnosis of Covid-19 and chest radiography (**Figure 1**) showed right-sided pleural effusion. She received intravenous antibiotics and was started on a 10-day course of Baricitinib after discussion with the infectious diseases team, as well as dexamethasone.

Due to her worsening dyspnea, she had a CT-PA and chest (**Figures 2,3,4**), which ruled out pulmonary embolism but showed marked progression in burden of pleural soft tissue metastasis and large right pleural effusion with near total collapse of the right lower lobe. A right-sided chest drain drained 1300 millilitres of pleural fluid. Her symptoms improved, including chest radiography (**Figure 5**) and WCC, which reduced to $6.18 \times 10^9/L$ and CRP to 11 mg/L.

Progression of her metastatic disease and/or tumour flare after discontinuing Lenvatinib was suspected. After discharge, she was well enough to recommence Lenvatinib at 20mg and has now had thyroglobulin response and a significant improvement in pleuritic pain in keeping with a clinical response.

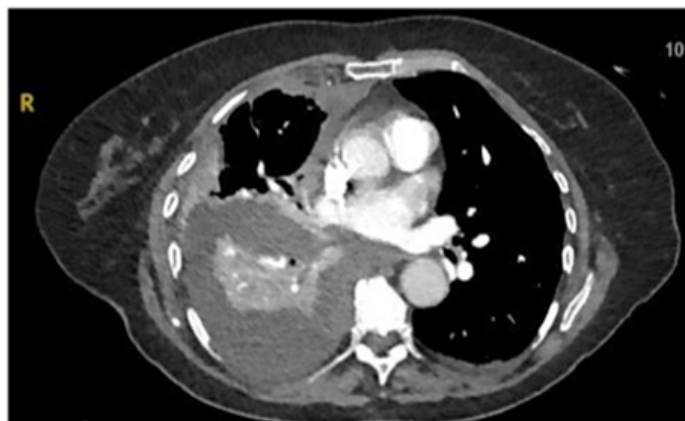


Figure 2&3: (2) Axial view of CT Thorax. (3) Coronal view of CT Thorax.

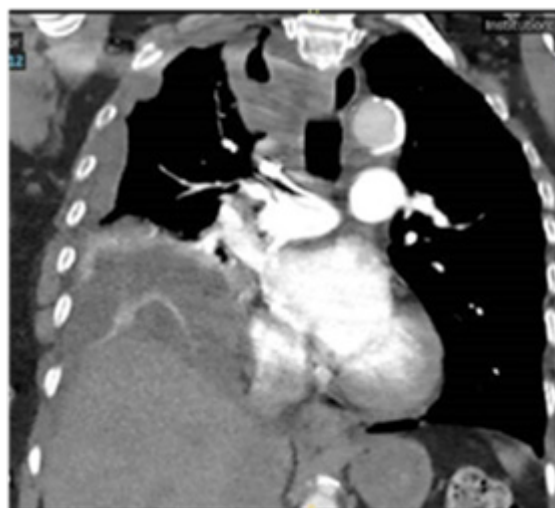

Figure 4: Sagittal view of CT Thorax

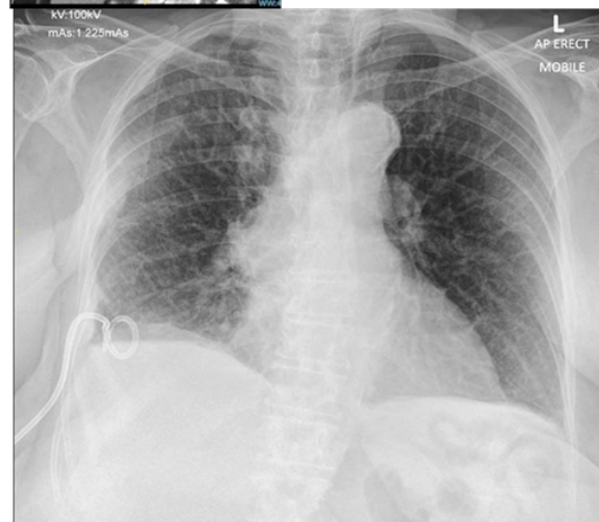
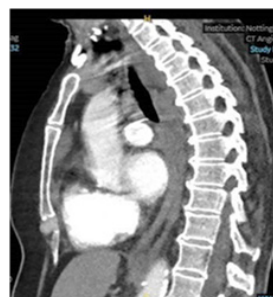
Figure 5: Right basal chest drain in situ, improvement of the right-sided pleural effusion, although right lower zone volume loss remains. Right-sided pleural thickening.

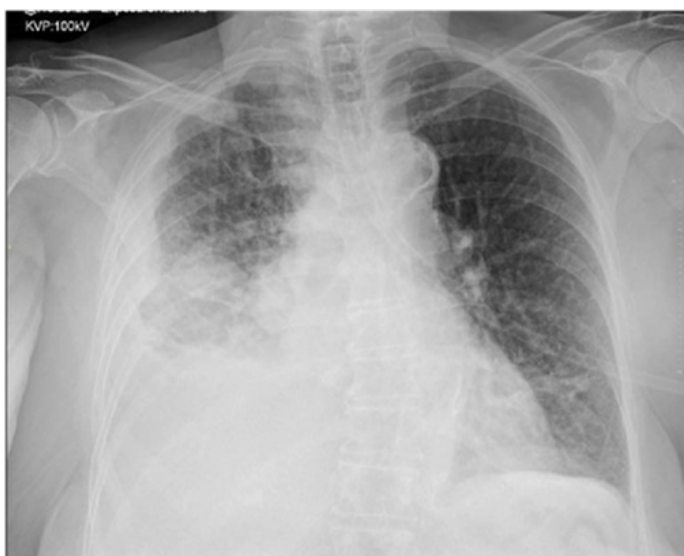

Figure 1: CXR on admission showing right pleural effusion and collapse.

Figure 2,3,4: Marked progression in pleural soft tissue metastasis with near complete circumferential pleural thickening in the right hemi thorax with a large pleural effusion, near complete collapse of the right lower lobe, generalized interlobular septal thickening on the right in keeping with lymphangitis carcinomatosa, mediastinal nodal metastasis.

Discussion

Lenvatinib can have adverse effects that lead to either decreasing its dose or stopping it altogether, including diarrhoea, hypertension, proteinuria and decreased appetite.

This case is unique as it portrays the impact of COVID on oncology patients but also demonstrates the potential flare-up phenomenon of discontinuing Lenvatinib. This phenomenon has been described [6]. However, its mechanism is not fully understood. Hypothetically cessation of anti-angiogenic therapy leads to an increase in vascular density, tumour blood flow rate and permeability, with subsequent, extravasation of fluids leading to reactive oedema [7], ascites and pleural effusions. A mice study with two VEGFR inhibitors observed that seven days after cessation, the tumours were completely revascularized, starting already one day after withdrawal [8]. In renal cell carcinoma patients with known metastasis to the lung and pleura, the fast development of pleural effusion after discontinuation of sunitinib or sorafenib has been reported with subsequent quick improvement in associated symptoms with the reintroduction of the same therapy [9].

In our case, disease progression occurred, and right pleural effusion rapidly increased within seven days after discontinuation of Lenvatinib but improved with re-starting Lenvatinib at a lower dose.

Arguably, COVID-19 could be the contributory factor to her signs and symptoms, and more robust studies will help to understand the flare-up phenomenon.

Conclusion

Lenvatinib can have many side effects, particularly in older patients. Deciding when to start Lenvatinib in metastatic iodine refractory patients can be challenging, with NICE guidance stating that it should be reserved for symptomatic or imminently symptomatic disease [9]. Dosing studies have suggested benefit of starting at full dose, but many patients do require dose interruptions or reductions [10]. Awareness of the flare up phenomenon on withdrawal of the drug is important when using Lenvatinib, especially in patients with pleural disease or effusions. This case also illustrates successful treatment of Covid-19 infection in a metastatic thyroid cancer patient who had recently received and stopped Lenvatinib, with recovery to the point of successful reinstatement on Lenvatinib.

Acknowledgement

We would like to thank the patient, the oncology and radiology department at Nottingham University Hospitals NHS Trust.

Conflict of interest: No conflicts of interest to declare.

References

1. Bray F, Ferlay J, Soerjomataram I, Siegel RL, Torre LA, et al. Global cancer statistics 2018: Globocan estimates of incidence and mortality worldwide for 36 cancers in 185 countries. *CA Cancer J Clin.* 2018; 68: 394-424.
2. Cabanillas ME, Habra MA. Lenvatinib: role in thyroid cancer and other solid tumours. *Cancer Treat Rev.* 2016; 42: 47-55.
3. Fleeman N, Houten R, Chaplin M, Beale S, Boland A, et al. A systematic review of lenvatinib and sorafenib for treating progressive, locally advanced or metastatic, differentiated thyroid cancer after treatment with radioactive iodine. *BMC Cancer.* 2019; 19: 1209.
4. Schlumberger M, Tahara M, Wirth LJ, Robinson B, Brose MS, et al. Lenvatinib versus placebo in radioiodine-refractory thyroid cancer. *New England Journal of Medicine* 2015; 372 621-630.
5. Tahara M, Kiyota N, Yamazaki T, Chayahara N, Nakano K, et al. Lenvatinib for anaplastic thyroid cancer. *Frontiers in Oncology* 2017; 7: 71-77.
6. Wolter P, Beuselinck B, Pans S & Schöffski P. Flare up: an often unreported phenomenon nevertheless familiar to oncologists prescribing tyrosine kinase inhibitors. *Acta Oncologica* 2009; 48: 621-624.
7. Desar IM, Mulder SF, Stillebroer AB, van Spronsen DJ, van der Graaf WT, et al. The reverse side of the victory: flare up of symptoms after discontinuation of sunitinib or sorafenib in renal cell cancer patients. A report of three cases. *Acta Oncologica* 2009; 48: 927-931.
8. Mancuso MR, Davis R, Norberg SM, O'Brien S, Sennino B, et al. Rapid vascular regrowth in tumors after reversal of VEGF inhibition. *J Clin Invest.* 2006; 116: 2610-2621.
9. National Institute for Health and Care Excellence. Lenvatinib and sorafenib for treating differentiated thyroid cancer after radioactive iodine (NICE Guidance TA535). 2018.
10. Marcia S Brose, Yury Panaseykin, Bhavana Konda, Christelle de la Fouchardiere, Brett G M Hughes, et al. A Randomized Study of Lenvatinib 18 mg vs 24 mg in Patients With Radioiodine-Refractory Differentiated Thyroid Cancer. *The Journal of Clinical Endocrinology & Metabolism.* 2022; 107: 776-787.